

When voice fades, images speak; imaging diagnosis of recurrent laryngeal nerve palsy on FDG PET-CT

Nadia Nazir¹, Ayesha Zubair², Aamna Hassan³, Kashif Saddique⁴
¹⁻⁴Department of radiology, Shaikat Khanum Memorial Cancer Hospital and Research Center, Lahore

Correspondence: Aamna Hassan. Email: aamnah@skm.org.pk

ORCID ID: 0000-0003-0026-0729

Abstract

Vocal cord palsy may reveal underlying sinister pathology. Unilateral vocal cord palsy can be detected incidentally on FDG PET-CT scan performed for oncologic evaluation. There may be asymmetrically increased FDG uptake in the contralateral vocal cord due to compensatory hyperactivity and hypertrophy, along with dilatation of the affected laryngeal ventricle, consistent with vocal cord paralysis.

PET-CT also aid in identifying the underlying etiological lesion along the course of the recurrent laryngeal nerve. Awareness of these characteristic imaging features is essential to prevent misinterpretation as primary laryngeal malignancy. This case highlight the integral role of FDG PET-CT in assessing the causes of vocal cord palsy.

Keywords: Vocal cord palsy, PET-CT scan, Lung cancer, Mediastinal mass.

DOI: <https://doi.org/10.47391/JPMA.26-58>

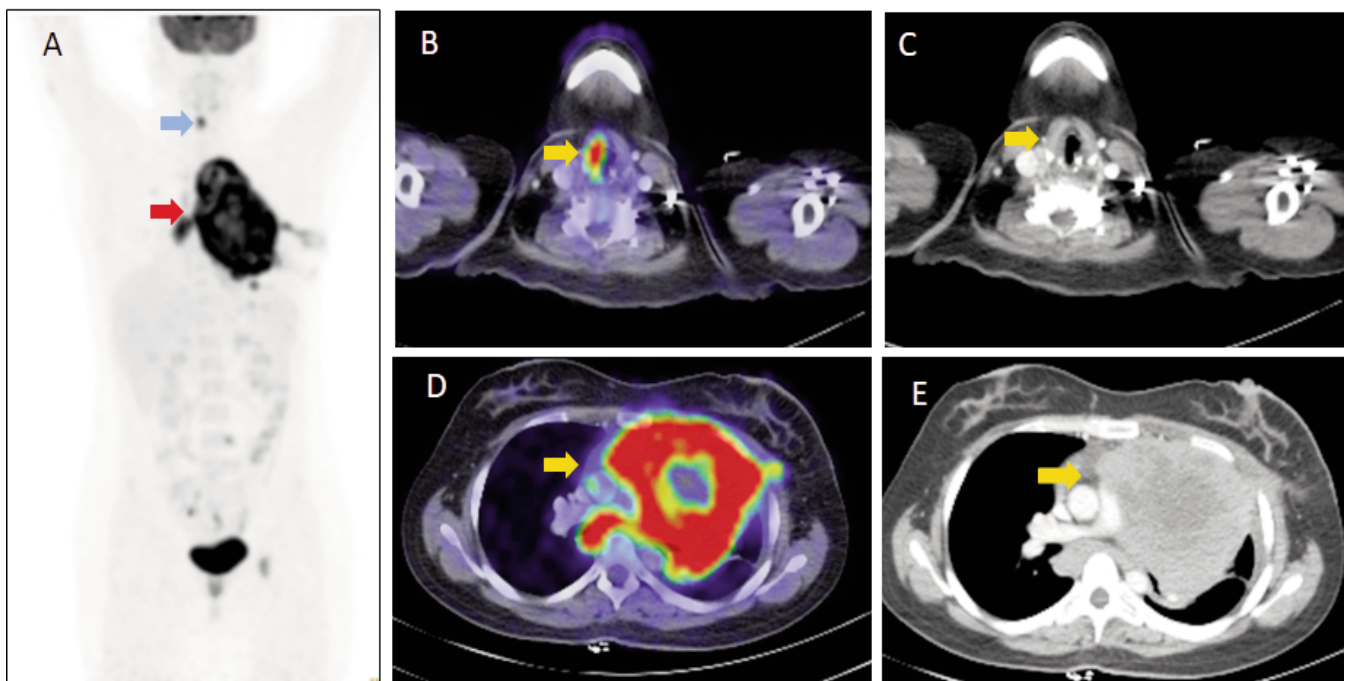


Figure A: Known left upper lobe lung mass (red arrow) and asymmetric, physiologically increased uptake in right vocal cord. No uptake seen in left vocal cord (vocal cord paralysis due to recurrent laryngeal nerve palsy as a result of compressive effect of lung mass).

Figure B and C represents physiological FDG uptake in normal right vocal cord while no uptake is present in left vocal cord (medialization of left vocal cord can be appreciated on CT images).

Figure D and E show hypermetabolic left lung mass in upper lobe.

Case Discussion

A 21-year female presented with history of neck swelling and weight loss. Ultrasound neck revealed multiple enlarged lymph nodes and biopsy showed Hodgkin lymphoma. She underwent F18 FDG PET-CT scan for staging purpose which gave the diagnosis of multiple hypermetabolic cervical and mediastinal lymph nodes along with increased FDG uptake in contralateral vocal cord.

Vocal cords are innervated by recurrent laryngeal nerve (RLN) and play a major role in phonation. Vocal cord palsy causes hoarseness of voice which is a primary symptom and has various laryngeal and extra laryngeal causes; including several mediastinal etiologies as neoplastic, inflammatory, vascular, and postoperative sequel^{1,2}. Lung cancer is the most common cause of vocal cord palsy. The length and course of the left RLN is longer than that of the right RLN; which predisposes the left RLN to a higher rate of injury from non-traumatic causes, such as neoplastic infiltration².

The normal FDG uptake of the larynx is symmetric and shows low-grade FDG activity in resting vocal cords³. Laryngeal FDG uptake can symmetrically increase during phonation because of laryngeal muscle contraction. Lack of FDG physiological activity in paralyzed cord and compensatory hypertrophy of the nonparalyzed vocal cord causes asymmetrical FDG uptake⁴.

Recognition of the particular FDG PET-CT findings of vocal cord palsy is essential to avoid misdiagnosis as primary laryngeal pathology. FDG PET-CT provides beneficial functional and anatomical information, helping in the detection of compensatory changes as well as in the identification of the underlying cause along the recurrent laryngeal nerve path. Early and accurate clarification and interpretation of this findings can influence patient management and may alter clinical outcomes.

Disclaimer: None.

Conflict of Interest: None.

Source of Funding: None.

References

1. Thomassen A, Nielsen AL, Lauridsen JK, Blomberg BA, Hess S, Petersen H, Johansen A, Asmussen JT, Sørensen JR, Johansen J, Godballe C, Høilund-Carlsen PF. FDG-PET/CT can rule out malignancy in patients with vocal cord palsy. *Am J Nucl Med Mol Imaging*. 2014 ;4:193-201.
 2. Mosaad BM, Abdelkader H, Rabie T, Abdelkawi M. 18F Fluorodeoxyglucose positron emission tomography [18F-FDG PET CT] in assessment of patients with vocal cord paralysis [VCP] secondary to extra laryngeal neoplasticcauses: How is it reliable?. *Egyptian Journal of Radiology and Nuclear Medicine*. 2024 Feb 2;55:28.
 3. Heller MT, Meltzer CC, Fukui MB, Rosen CA, Chander S, Martinelli MA, Townsend DW. Superphysiologic FDG Uptake in the Non-Paralyzed Vocal Cord. Resolution of a False-Positive PET Result with Combined PET-CT Imaging. *Clin Positron Imaging*. 2000 ;3:207-211.
 4. Erdoğan O, İsmi O, Arpacı RB, Vayisoğlu Y, Özcan C. False-Positive Laryngeal FDG Uptake During PET/CT Imaging: Reinke's Edema. *Turk Arch Otorhinolaryngol*. 2018 ;56:114-116.
-