

Membranous nephropathy secondary to pulmonary tuberculosis

Mohammad Yasin¹, Mohsin Khan², Faiza Khan³, Niama Khan⁴

Abstract

Glomerulonephritis (GN), secondary to tuberculosis, is quite a rare condition. Here we report the case of membranous nephropathy, which completely resolved after the treatment of tuberculosis. A 42-year-old man presented to a nephrologist with burning micturition. His urine routine examination (RE) was suggestive of 2+ protein. His 24-hour urinary protein was 4.2 grams. Renal biopsy revealed membranous nephropathy. His autoimmune, hepatitis B, hepatitis C, and HIV workups were non-conclusive. The nephrologist advised him to take Rituximab. Before the commencement of immunosuppressants, his Interferon-gamma Release Assay (IGRA) was tested which turned positive. He was referred to a pulmonologist for treatment of latent tuberculosis and further workup. His sputum geneXpert detected pulmonary TB. He was treated with anti-tuberculous therapy (ATT), and his proteinuria improved gradually and settled. The patient did not require any immunosuppressants for MN. The initial symptoms of MN secondary to TB are subtle. It is imperative to evaluate the cause of membranous nephropathy before starting an immunosuppressant. GN secondary to TB can be treated successfully with ATT.

Keywords: Glomerulonephritis, Pulmonary tuberculosis, Rituximab, Antituberculosis therapy (ATT).

DOI: <https://doi.org/10.47391/JPMA.22020>

Introduction

Membranous nephropathy (MN) results from an immune response of the body to foreign antigens. The immune response led to the formation of immune complexes, which deposit inside the glomerulus capillary membrane and are often present with proteinuria.¹ Primary MN results from the deposition of immunocomplexes in the capillary basement membrane, while secondary MN results from malignancies, infection, and diabetes.² Tumours contribute

to 10% of the cases of MN, and the most common tumours are of lung origin.³ Hepatitis B and C are the most common infections implicated in MN. While tuberculosis is quite a rare cause of infectious MN, the usual treatment for primary MN is immunosuppressive agents. The treatment of secondary MN is cause-related, but in some cases add-on immunosuppressants are also needed. TB is a rare cause of GN, and the renal spectrum varies from the involvement of interstitial to advanced cavitory lesions depending on the patient's immune status.⁴

Here, we present an unusual case of membranous nephropathy. During the management of proteinuria, the patient was diagnosed with pulmonary tuberculosis. As he was being treated for tuberculosis, the patient's proteinuria settled, and he did not require an immunosuppressant (Rituximab).

Case Summary

A 42-year-old male from Abbottabad presented on April 15, 2023, to a nephrologist with a history of burning micturition and eye puffiness in Ayub Medical Teaching Institute, Abbottabad. He did not report any comorbidities in the past. A routine urine examination showed 3–4 WBCs, 5–6 RBCs, and +2 protein in the urine. Serum creatinine was 1.2 mg/dl with an eGFR of >60 ml/min/1.73m² (normal >60 ml/min/1.73m²). The clinical diagnosis of nephrotic syndrome was made by the nephrologist. On May 1, 2023, the kidney biopsy revealed membranous nephropathy with IgG4, C3, and IgG granular deposits on immunofluorescence (**Figures A and B**). Moderate tubular damage without interstitial fibrosis was also noticed. The patient's random blood glucose level was 96 mg/dl (normal- 101–140mg/dl). Hepatitis B surface antigen, hepatitis B core antibody (IgM), and anti-HCV antibodies were non-reactive. The anti-phospholipase 2 receptor antibody (Anti-PLAR2) was negative. Serum albumin was 4.3 g/dl. He was labelled with primary membranous nephropathy and advised intravenous Rituximab in 1–2 doses. Before the commencement of Rituximab, he was screened for latent infection. His gamma-interferon assay (QuantiFERON-TB Gold Plus) was positive. He was referred to the pulmonologist for a workup of tuberculosis. During history taking, the patient revealed that multiple members of his family had contracted pulmonary TB and taken ATT (anti-tuberculosis treatment). The patient had no bothersome symptoms yet, apart from burning micturition and

^{1,2}Department of Pulmonology, Ayub Teaching Hospital, Abbottabad, Pakistan;

³District Head Quarter Hospital, Abbottabad, Pakistan; ⁴Ayub Teaching Hospital, Abbottabad, Pakistan.

Correspondence: Mohsin Khan. e-mail: mohsinkhan1464@yahoo.com

ORCID ID: 0000-0002-2003-4967

Submission completed: 14-11-2024 **1st Revision received:** 27-05-2025

Acceptance: 10-01-2026

Last Revision received: 09-01-2026

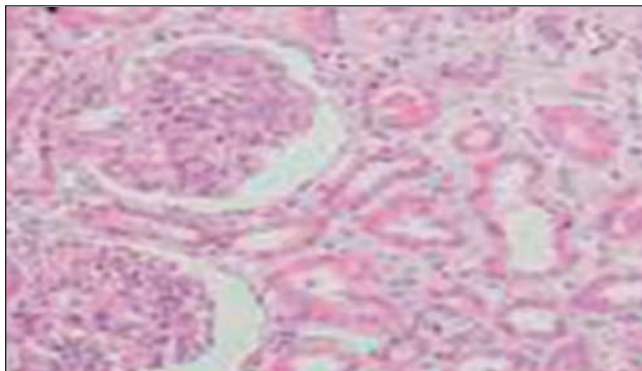


Figure-1: Kidney biopsy showing thickened capillary membrane and glomerulus (200X). productive cough in the morning with sputum. The patient’s weight was 60 kg; his chest was clear with bilateral equal air entry and vesicular breathing. No added sound was appreciated on auscultation. There was no cervical, axillary, or inguinal lymphadenopathy. His chest X-ray was unremarkable. He was advised high-resolution computed tomography (HRCT) of the chest, Sputum GeneXpert, and smear microscopy. The HRCT of the chest showed non-specific features without any clinical significance. The sputum studies were normal, but the geneXpert showed moderate detection of Mycobacterium tuberculosis with Rifampicin sensitivity. The patient was started on the **Table:** Showing details of patients who presented with MN secondary to tuberculosis.

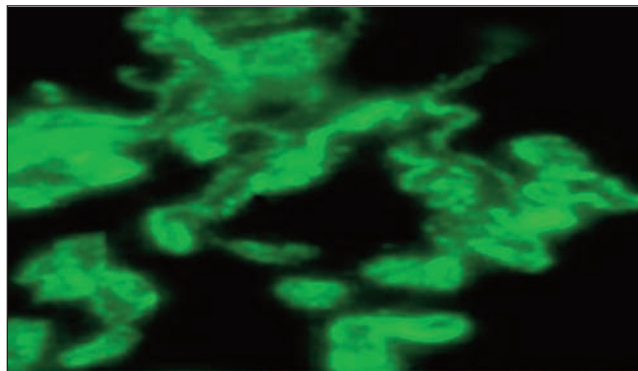


Figure-2: Kidney biopsy showing thickened capillary membrane and glomerulus (200X). intensive phase of ATT, i.e., tablets Isoniazid 300 mg, Rifampicin 600 mg, Ethambutol 1,100 mg, and Pyrazinamide 1,600 mg for two months; follow-up was conducted after two weeks with liver function test. After one month of treatment with ATT, his proteinuria settled from 4.2 g to 3.2 g (details in Table. After completion of the intensive ATT phase, he was switched to the continuation phase for four months (Tablet Isoniazid 300 mg, Tablet Rifampicin 600 mg). After six-month treatment with anti-tuberculosis drugs, the patient was totally symptom-free without any proteinuria.

Complete blood count (April 19, 2023)				
WBCs	5.2/mm ³	24-Hour Urinary Protein	April 15, 2023	4222.56mg/day
RBC	5.3/mm ³		July 10, -2023	3215.7mg/day
PLT	286/mm ³		Oct 22, 2023	2973.6mg/day
Hct	49%		May 23, 2024	400mg/day
HB	15g/dl		June 22, 2024	Nil
MCV	92fl	RBS	80-160mg/dl	90mg/dl
Urine Routine examination				
PH	05	Renal Biopsy	Mesangium	Mild Proliferation
Protein	+2		Glomeruli	08 and normal
Glucose	Nil		Capillary wall	Thick with spikes
ketone	Nil		Tubules	Moderate damage
RBC's	5-6HPF		Interstitial	normal
WBC's	3-4HPF		Blood vessel	normal
Urine Microscopy on				
Bacteria	NIL/HPF	Immuno-fluorescent	IgG	++
Yeast	NIL/HPF		IgA	-
High Power field				
Cast	Nil		IgG4	++++
Crystals	+2HPF		IgM	-
Serum Albumin (3.2-4.5g/dl)				
	4.3g/dl		C3	-
Viral serology				
Anti HCV	Negative	IGRA*	<0.3IU/ml (normal)	High, Positive
Anti-HIV	Negative	e-GFR**	>60 ml/min/1.73m ²	>60
Ab Hep B Core IgM	Negative	creatinine	0.9-1.4 (normal)	1.2 mg/dl
HB S Ag	Negative	AFB***	Negative	Negative

*IGRA: Interferon Gamma Release Assay, **e-GFR: Estimated Glomerular filtration rate, ***Acid Fast Bacilli, RBC: Red Blood Cell, WBC: White Blood Cell, PLT: Platelets, HCL: Haematocrit, Hb: Haemoglobin, MCV: Mean Corpuscular Volume, HCV: Hepatitis C virus, HIV: Human Immuno Deficiency virus, HbsAg: Hepatitis B Surface Antigen.

Written consent was obtained from the patient for writing this case report.

Discussion

This report presents a case of MN that achieved remission after anti-tuberculosis medications. The patient had some features of active pulmonary TB, like chronic cough with sputum and a strong family history of TB contact with multiple individuals. Morimoto N et al.¹ reported a similar case without any signs or symptoms of tuberculosis, but before starting steroids and immunosuppressants, the screening test for TB (the T-SPOT test) turned positive. Bhuwania P et al.⁵ reported a case of MN secondary to tuberculosis in which the patient had signs of oedema and a non-resolving fever. Madhumita Pal et al.⁶ reported a case in which renal interstitium was involved in renal biopsy. Most cases of MN have subtle clinical, pulmonary, and systemic signs of tuberculosis. In the literature review, case here were very few reports of cases that were diagnosed on renal biopsy. Most of the cases have granular deposits on the IF (immunofluorescent) and diffuse thickness of the glomerular basement membrane (GBM). In the current case, the clinical improvement of proteinuria was observed within one month after

the commencement of ATT. In the case report by Morimoto N et al.¹ (Figure 4), clinical improvement of proteinuria was observed over a period of one month. While a case reported by Bhuwania P et al.⁵ showed improvement after two months, the reason could be the concomitant liver involvement in this case. Another case of a 15-year-old girl reported by Shang MH et al.⁷ was initially treated as a case of acute GN but later proved to be MN secondary to TB. In this case, the improvement in proteinuria was also observed over a period of one month. In the current case, immunosuppressant therapy for MN was not needed, and the response of ATT to proteinuria was very dramatic. A case report in the literature from Saudi Arabia by Malhotra KP et al. shows that MN responded to ATT and sustained remission without the need for immunosuppressants.³ Kanaji N. et al.⁸ reported a case of an 83-year-old male of Japanese descent whose proteinuria was successfully treated with ATT, although the patient was infected with *Mycobacterium shimoidei*. However, the response of proteinuria to ATT was slower as compared to the current case. The reason could be different species of *Mycobacterium*, i.e., non-*Mycobacterium tuberculosis* (NTM), and differences in the ATT regime. The initial presentation of MN secondary to TB has non-specific and poorly defined symptoms. In most cases, the initial symptoms are similar to that of GN. However, the detailed history of TB contact and screening tests for infectious diseases reveal the disease in most cases. TB should be considered a secondary cause of membranous glomerulonephritis and a TB workup is required for a confirmatory diagnosis.

Conclusion

Though urinary tuberculosis is rare, patients can present with isolated secondary glomerulonephritis. The initial symptoms of MN secondary to TB are subtle. It is imperative to evaluate the cause of membranous nephropathy before starting an immunosuppressant. The clinical improvement is achievable within one month after the commencement of anti-TB therapy. Membranous GN is treatable with a good prognosis. This case increases the emphasis on the importance of screening before the commencement of immunosuppressants.

Disclaimer: None.

Conflict of Interest: I declare that the person who signed the HOD Letter is also the co-author of the same manuscript.

Funding Sources: None.

References

1. Morimoto N, Nagahama K, Tsuura Y, Terai A, Tanabe M, Otani M, et al. Membranous nephropathy in a patient with pulmonary tuberculosis infection and lung adenocarcinoma: a case report. *CEN Case Rep.* 2022;11:126–33. doi:10.1007/s13730-021-00641-7.
2. Su Z, Luo Z, Wu D, Liu W, Li W, Yin Z, et al. Causality between diabetes and membranous nephropathy: Mendelian randomisation. *Clin Exp Nephrol.* 2025;29:227–35. doi:10.1007/s10157-024-02566-8.
3. Lefaucheur C, Stengel B, Nochy D, Martel P, Hill GS, Jacquot C, et al. Membranous nephropathy and cancer: epidemiologic evidence and determinants of high-risk cancer association. *Kidney Int.* 2006;70:1510–7. doi:10.1038/sj.ki.5001790.
4. Malhotra KP, Chandra A, Rao N, Shukla S, Gupta A. Tuberculosis as a microbiologically proven aetiology of membranous nephropathy and interstitial nephritis. *Saudi J Kidney Dis Transpl.* 2019;30:1447–9. doi:10.4103/1319-2442.275491.
5. Bhuwania P, Mule A, Checker S, Bhayandar M. Membranous nephropathy and pulmonary tuberculosis: an uncommon combination: case report. *EMJ.* 2024;9:106–10. doi:10.33590/emj/11000011.
6. Pal M, Sengupta M, Basu K, Roychowdhury A. Membranous nephropathy associated with tuberculosis — a case report. *Asian Pac J Trop Med.* 2022;15:183–5. doi:10.4103/1995-7645.340571.
7. Shang MH, Zhu N, Hao J, Wang L, He ZY, Yang M, et al. Membranous nephropathy associated with tuberculosis. *Chin Med J (Engl).* 2016;129:622–3. doi:10.4103/0366-6999.176986.
8. Kanaji N, Kushida Y, Bandoh S, Ishii T, Haba R, Tadokoro A, et al. Membranous glomerulonephritis associated with *Mycobacterium shimoidei* pulmonary infection. *Am J Case Rep.* 2013;14:543–7. doi:10.12659/AJCR.889684.

Author Contribution:

MY: Critical review.

MK: Concept and design.

FK: Drafting.

NK: Final approval.