

Unstable angina pectoris in a young male after first dose of COVID-19 MRNA-vaccine

Billi Kinesya¹, Makhyan Jibril Al-Farabi², Yusuf Mannagalli³, Yudi Her Oktaviono⁴

Abstract

Some side effects regarding COVID-19 vaccination have been reported. The most common reports of cardiovascular issues were myocarditis and pericarditis. Although inflammation is the most common cause in this matter, there were only a few reports about ischaemic cases related to COVID-19 vaccines. These reports also commonly included older men who received a second dose of mRNA vaccination. We present a 25-year-old man with chest pain mimicking a heart attack after receiving the first dose of the mRNA COVID-19 vaccine. There were no known preceding cardiovascular risk factors. Workups were done, and the diagnosis made was unstable angina pectoris. This may remind physicians to increase awareness of cardiovascular side effects in this vaccination era, as it may be encountered even in younger patients. The patient was seen at Dr. Soetomo General Academic Hospital, Surabaya, Indonesia, in August 2022

Keywords: COVID-19 Vaccines, Myocarditis, RNA, Cardiovascular, Angina, Pericarditis

DOI: <https://doi.org/10.47391/JPMA.S6-ACSA-17>

Introduction

Severe Acute Respiratory Syndrome Coronavirus 2 (SARS-CoV-2) or Coronavirus Disease-2019 (COVID-19) is the new version of Coronavirus discovered in 2019. COVID-19 acquired a rapid spread in 2019 and World Health Organization (WHO) had to declare a pandemic situation in 2020. This encouraged researchers worldwide to look for medical therapy to acquire protection from COVID-19 and an important one was the development of research for the COVID-19 mRNA vaccine. This has proven to be very useful in preventing and reducing the severity of COVID-19.¹

.....
^{1,3}Faculty of Medicine, Universitas Brawijaya, Malang, ^{2,4}Department of Cardiology & Vascular Medicine, Universitas Airlangga, Dr Soetomo General Hospital, Surabaya, Indonesia.

Correspondence: Yudi Her Oktaviono **Email:** yudi.her@fk.unair.ac.id

ORCID ID: 0000-0002-2350-2789

The administration of mRNA vaccines are not free of side effects and allergic reactions, the cause of which are not known with certainty. The investigators suspect the content of PEGylated lipids and the pre-existence of anti-PEG antibodies (IgEs and/or IgGs), to be the culprits². The adverse effects observed are swelling, fever, body aches, weakness, drowsiness, and aches.³ In addition, side effects on the heart as unstable angina pectoris, myocarditis, and pericarditis are still rarely known. This case report will discuss the adverse effects on the heart after the mRNA vaccine in the form of Unstable Angina Pectoris (UAP) in a 25 years old male. To our knowledge, this side effect has not been reported in literature.

Case Report

A 25-year-old male reported to the Dr. Soetomo General Academic Hospital, Surabaya, Indonesia, in August 2022. He was a healthy man without any chronic diseases. As an obligation to the Indonesian government, he was given the first dose of mRNA-1273 (Moderna) Vaccine. The government policy obligates physicians who received CoronaVac (Sinovac) vaccine to be boosted with mRNA vaccine.

During the first 24 hours the young man felt fit so undertook some running exercise on the second day. After an hour of exercise, he suddenly felt a very intense pain in his chest radiating to left shoulder and left arm similar to a heart attack. Even after two hours lying down, the pain was not relieved. He sought help at primary health care and got DAPT (Aspirin & Clopidogrel) and ISDN (Isosorbide Dinitrate) as the first treatment. As no improvement was observed, the possibility of a myocardial infarction being vaccine related was considered and he was referred to the main hospital.

A 12-lead electrocardiogram (ECG) on arrival showed sinus rhythm with left axis deviation and incomplete right bundle-branch block (ICRBBB) (Fig. 1). Chest radiography showed no abnormalities. Laboratory findings (blood test, electrolyte serum, lipid profile, and cardiac markers) were not indicative of any specific heart disease.

Lab findings at the emergency room were normal on cholesterol levels, renal functions, random blood glucose,

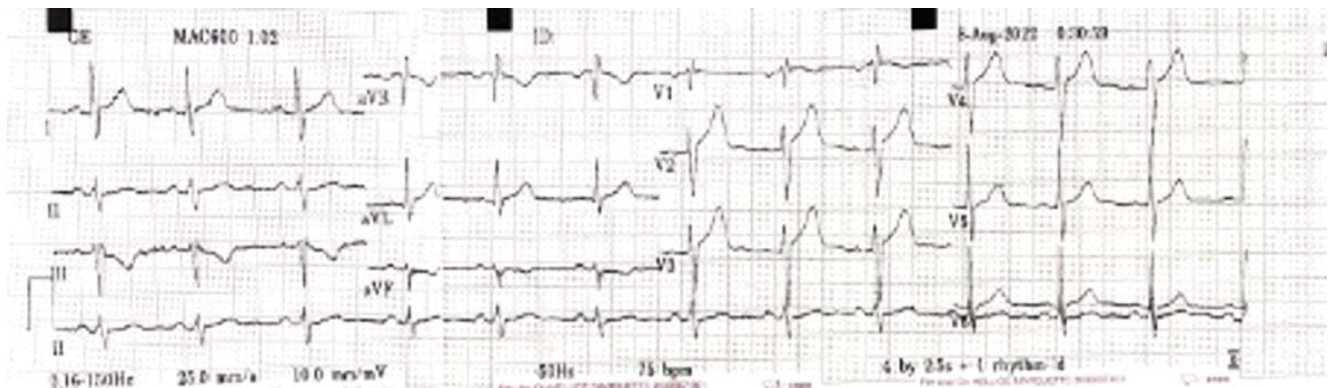


Figure-1: ECG on admission showing ICRBBB.

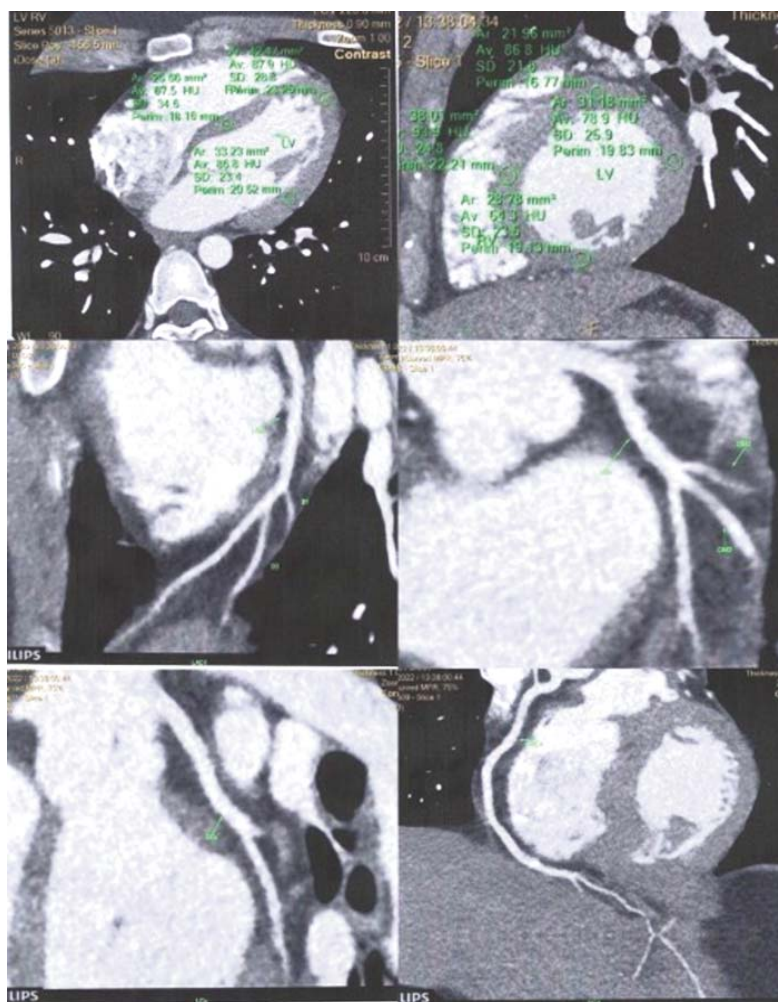


Figure-2: Cardiac CT-Scan after 24 hours.

CRP, LDH, and NT-proBNP. Troponin-I was also negative, a mark of no cardiac muscle damage.

Although there was no fever since the vaccination, we tried to exclude myocarditis. The cardiac CT scan was done only to know there was no proof of inflammation (myocarditis and pericarditis) process. Cardiac CT scan revealed no myocarditis or pericarditis (Fig. 2).

All exams had been done, and the diagnosis fell into unstable angina pectoris since we have myopericarditis was excluded, as the common post mRNA-Vaccine vaccine heart disease. He was hospitalized receiving NSAID (Acetaminophen) and Atorvastatin as his main medications. The pain subsided on the second day, and was discharged on the third day. One month after discharge, the patient was asymptomatic without a follow-up ECG.

Discussion

Discussing serious side effects of mRNA vaccine on the cardiovascular scale, Myocarditis and Pericarditis are the most emerging topics right now⁴. However, it is necessary to know that another complication has not been reported, like coronary diseases. We have reported mRNA-1273 vaccine side effects resembling a heart attack in a young Indonesian male. Cases like this may often be under-reported. It can be understandable since the Indonesian vaccination programme is massive and must be done quickly. Therefore, many people did not get special attention nor observation regarding personal vaccine side effects.

A study from the USA reported that 5.98% of recipients of BNT162b2 complained of cardiovascular side effects. They

are palpitation (4.36%), chest pain (1.12%) and blood pressure changes and syncope (0.87%)⁵. It's unclear how the mRNA vaccine caused chest pain in these patients. Hypothetically, Testosterone and Catecholamine take part in the process⁶. One of the major sites of SARS Cov-2 mRNA accumulation and spike protein production is in the adrenal cortex and medulla. This induced a hyper catecholaminergic state marked by high numbers of CD3+ T-lymphocytes and CD20+ B-lymphocytes, while immune cells like eosinophils and macrophages were almost depleted. Adrenaline and noradrenaline tend to activate lymphocytes and inhibit eosinophils, monocytes, and macrophages⁷. Increased testosterone and catecholamine in the blood are presumed to be the main cause of chest pain in young men.

As the reported cases are in small numbers, this is also becoming one of the limitations in data gathering. We couldn't find the exact relationship between mRNA COVID-19 vaccines and the occurrence of coronary heart disease. We also did not perform the cardiac biopsy which is the gold standard in diagnosing myocarditis, as the patient did not provide the consent. Instead, we got the cardiac CT scan data. We recommend doing full examinations on these kinds of cases. Physicians should increase their awareness of the serious side effects of COVID-19 vaccines.

Conclusion

Vaccination proved to be our best weapon to fight COVID-19 pandemic, but it has the potential to give some under-reported side effects. This is the first case report of chest pain resembling a heart attack after mRNA-1273 vaccination on a young healthy male. This has never been reported probably because so many people were involved in this vaccination programme. It is hypothesized that the chest pain could arise from increased testosterone and catecholamine hormones,

particularly in young males.

Consent: Case report publication consent was obtained from the patient

Disclaimer: The abstract has been presented during ACSA (Airlangga Cardiovascular International Conference – Continuing Medical Education – Surabaya Cardiology Update – Airlangga Cardiovascular Expert Meeting) 2022, held by Indonesian Heart Association as a participant in Scientific Poster competition.

Conflict of Interest: NIL

Funding disclosure:None.

References

1. Han F, Liu Y, Mo M, Chen J, Wang C, Yang Y, et al. Current treatment strategies for COVID-19 (Review). *Mol Med Rep* 2021;24:858. doi: 10.3892/mmr.2021.12498.
2. Verbeke R, Lentacker I, De Smedt SC, Dewitte H. The dawn of mRNA vaccines: The COVID-19 case. *J Control Release* 2021;333:511-20. doi: 10.1016/j.jconrel.2021.03.043.
3. Esparza Olcina MJ, Juanes de Toledo B. Pfizer-BioNTech, the first mRNA vaccine against COVID-19, appears safe and effective. *Evid Pediatr* 2021;17:6.
4. Pillay J, Gaudet L, Wingert A, Bialy L, Mackie AS, Paterson DI, et al. Incidence, risk factors, natural history, and hypothesised mechanisms of myocarditis and pericarditis following covid-19 vaccination: living evidence syntheses and review. *BMJ* 2022;378:e069445. doi: 10.1136/bmj-2021-069445.
5. Kadali RAK, Janagama R, Peruru S, Malayala SV. Side effects of BNT162b2 mRNA COVID-19 vaccine: A randomized, cross-sectional study with detailed self-reported symptoms from healthcare workers. *Int J Infect Dis* 2021;106:376-81. doi: 10.1016/j.ijid.2021.04.047
6. Cadegiani FA. Catecholamines Are the Key Trigger of COVID-19 mRNA Vaccine-Induced Myocarditis: A Compelling Hypothesis Supported by Epidemiological, Anatomopathological, Molecular, and Physiological Findings. *Cureus* 2022;14:e27883. doi: 10.7759/cureus.27883.
7. Scanzano A, Cosentino M. Adrenergic regulation of innate immunity: a review. *Front Pharmacol* 2015;6:171. doi: 10.3389/fphar.2015.00171.