

## Spinal meningiomas: Management and outcomes

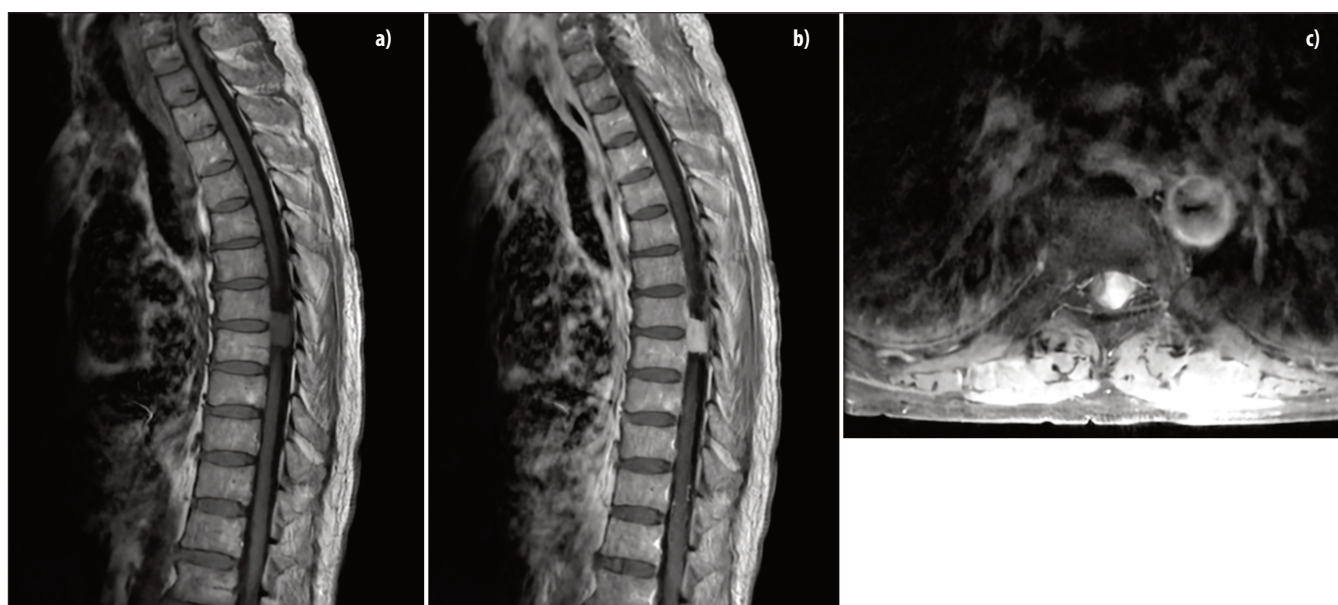
Anam Tariq<sup>1</sup>, Ayesha Sohail<sup>2</sup>, Zara Shah<sup>3</sup>, Saqib Bakhshi<sup>4</sup>, Muhammad Shahzad Shamim<sup>5</sup>

### Abstract

Spinal meningiomas are relatively rare, benign, intradural, extramedullary tumours, that are typically slow-growing and well-defined. Surgery is always the first line for treating spinal meningiomas. Here, we have discussed the existing literature on spinal meningiomas and the role of surgery in determining the outcomes.

DOI: <https://doi.org/10.47391/JPMA.23-52>

due to presence of oestrogen receptors.<sup>1,2</sup> Majority of SM are reported to be WHO grade 1 meningiomas but rarely these benign, not life threatening tumours can compress the spinal cord and result in an acute or chronic neurological dysfunction.<sup>3,4</sup> They are mostly found in the thoracic region but can involve any region of the spine. MRI is the investigation of choice and Bayoumi et al.<sup>5</sup> have classified spinal meningiomas into following four stages



**Figure:** a) MRI thoracic spine sagittal section, T1 weighted image, showing an iso-intense intra-dural extra-medullary lesion in mid-thoracic region. b) MRI thoracic spine sagittal section, T1 post-contrast image of the same patient, showing a homogeneously enhancing intra-dural extra-medullary lesion in mid-thoracic region. c) MRI thoracic spine axial section, T1 post-contrast image of the same patient, showing a homogeneously enhancing intra-dural extra-medullary lesion with no extension towards the foramen. It was meningioma grade 1 on histopathology.

### Introduction

Spinal meningiomas (SM) are slow growing, intradural extramedullary benign tumours that usually have a favourable outcome and low recurrence rate after surgical resection. These tumours with uncertain histogenesis represent 25-45% of all the spinal intradural tumours and 1.2-12% of all the central nervous system meningiomas. They are more frequently found in 50-80 years old women

based on the area of the spinal canal involved; Stage 1 (less than 25%), stage 2 (25-50%), stage 3 (50-75%) and stage 4 (more than 75%). These are further classified into four types (I-IV) and nine subtypes.<sup>5</sup> Complete surgical resection is the treatment of choice for spinal meningiomas and surgical approach is dependent on the anatomical location of tumour and its attachment.<sup>1</sup>

### Review of Evidence

Hua et al.<sup>6</sup> published their results from a comprehensive study in 2018, investigating the prognostic factors and the functional neurological outcomes of spinal meningiomas (SM). 194 of total 483 SM patients who underwent gross total resection (GTR) were monitored and using the

<sup>1</sup>Clinical Trials Unit, Aga Khan University; <sup>2</sup>Post Graduate Medical Education, Aga Khan University; <sup>3-5</sup>Section of Neurosurgery, Department of Surgery, Aga Khan University

**Correspondence:** Muhammad Shahzad Shamim.

e-mail: [shahzad.shamim@aku.edu](mailto:shahzad.shamim@aku.edu)

ORCID ID: 0000-0001-8305-8854

Simpson grading scale, the degree of tumour excision was assessed. Favourable neurological outcomes were reported in 80(41.2%) patients while all 19(9.8%) patients who experienced decreasing neurological function had tumour adhesion to the spinal cord. Recurrence was observed in 9(4.6%) patients regardless of the length of follow-up, and male gender ( $p<0.001$ ), prior recurrence ( $p<0.001$ ), high WHO and Simpson grading ( $p<0.001$ ) were identified as important variables that predicted the risk. Corresponding to this, patients were more likely to experience a loss in neurological function if they had recurrent tumours ( $p<0.001$ ), worse preoperative neurological functions ( $p<0.001$ ) and more segments involved ( $p<0.034$ ). On multivariate analysis, higher tumour grade ( $p<0.001$ ) and higher Ki-67 index ( $p<0.001$ ) were further demonstrated to be independent predictors of impairment in neurological function. This is one of the largest cohorts and is based on a single, major neurological centre.<sup>6</sup>

Kwee et al.,<sup>7</sup> retrospectively reviewed a cohort of 166 SM patients who underwent open microsurgical management. The tumours were classified using WHO and Simpson grading system and Modified Rankin Scores (mRS) were used to evaluate treatment outcomes. Data for 159 patients was analysed and 141 of 159 (95.8%) patients were reported to have undergone GTR of their tumours. Subtotal resection (STR) was carried out in 18(11.3%) patients. Post-operative complications were seen in 35(21.7%) patients including CSF leak in 7 (4.4%) patients and delayed wound healing in 6(3.77%) patients. Favourable surgical outcomes were seen in 117(73.1 %) patients, 24(15 %) remained stable, and 19(11.8 %) deteriorated, including mortality in 12 patients. Patients with postoperative complications had an increased likelihood of having an unfavourable outcome ( $p<0.054$ ), while younger patients had a non-significantly better outcome ( $p<0.087$ ). Atypical meningioma and male sex were found to be associated with a poor outcome on multivariate analysis. Unfavourable surgical outcomes were linked to low pre-operative mRS, tumour adhesion, and infiltration. Recurrences were seen in 12(7.2 %) cases all of which were related to the extent of resection. With complete (Simpson I-III) and incomplete resection, respectively, the recurrence free survival after 15 years was 67.2% and 21.9%. The authors advise using intraoperative neuromonitoring, or IONM, to improve surgical outcomes.<sup>7</sup>

Cao et al., determined the surgical outcomes of spinal meningiomas using the linked Surveillance, Epidemiology, and End Results (SEER) database. The authors identified 4204 patients with spinal meningiomas over a 12-year period. The primary outcome of the study was survival after diagnosis. A total of 709(16.9%) were already deceased at the time of data collection. Of the patients, 3396(80.8%)

had undergone surgery and 108(2.6%) needed radiation therapy. The OS rates were 95.4%, 90.4%, 85.3%, and 70.9% at 1, 3, 5 and 10 years following diagnosis, respectively. Patients with benign meningiomas who were married, female, and younger demonstrated higher OS rates. The outcomes also demonstrated that surgical intervention is beneficial for a better prognosis. The survival analysis findings further supported the notion that patients would fare better following surgery.<sup>8</sup>

In a retrospective study over a 20-year period, Haddad et al., investigated the differences in outcomes across subgroups of spinal meningioma dural attachments. A total of 141 patients were identified and all of them had undergone posterior based resection. The most common locations for dural attachments were ventral (28.4%) and ventrolateral (26.2%) followed by dorsolateral (22.0%), lateral (12.1%), and dorsal (11.3%). Extent of resection, postoperative complications, any new long-term neurological deficits, and recurrence frequency were the main outcomes of interest. The majority of patients underwent gross-total resection (GTR) (83.3%), with no differences between dural attachment subgroups ( $p=0.362$ ). There were also no differences between dural subgroups in terms of largest diameter of tumour resected ( $p=0.201$ ), perioperative complications ( $p=0.116$ ), long-term neurological deficit ( $p=0.100$ ), postoperative radiation therapy ( $p=0.971$ ), recurrence ( $p=0.800$ ) or length of follow up ( $p=0.413$ ). On multivariate analysis, cervical spine tumours were associated with lower incidence of GTR ( $p=0.006$ ). The dorsal (18.8%) and ventral (20.0%) tumours had slightly higher risk of surgical complications ( $p=0.047$ ) whereas dorsolateral tumours had slightly reduced rates of improvement after surgery ( $p=0.046$ ). High Simpson grade tumours (III and IV) were associated with higher rate of recurrence on log-rank analysis ( $p=0.007$ ). The study concluded that the posterior-based approaches for resection of spinal meningiomas are safe and effective, regardless of dural attachment location, with similar surgical, oncological, and neurological outcomes.<sup>9</sup>

## Conclusion

Spinal meningiomas are rare, benign pathologies. Surgery is effective and safe. Long-term spinal cord compression, however, can result in long-term neurological deficits even after a successful surgery, hence the importance of early diagnosis and prompt treatment. Recurrences, can occur even after 10 to 15 years. Regular follow-up plans must be developed for each patient.

## References

1. Gilard V, Goia A, Ferracci FX, Marguet F, Magne N, Langlois O, et al. Spinal meningioma and factors predictive of post-operative deterioration. *J Neurooncol* 2018;140:49-54.

2. Kobayashi K, Ando K, Matsumoto T, Sato K, Kato F, Kanemura T, et al. Clinical features and prognostic factors in spinal meningioma surgery from a multicenter study. *Sci Rep*. 2021;11:11630.
  3. Pettersson-Segerlind J, Fletcher-Sandersjö A, Tatter C, Burström G, Persson O, Förander P, et al. Long-term follow-up and predictors of functional outcome after surgery for spinal meningiomas: a population-based cohort study. *Cancers (Basel)*. 2021;13:3244.
  4. Pettersson-Segerlind J, von Vogelsang AC, Fletcher-Sandersjö A, Tatter C, Mathiesen T, Edström E, et al. Health-Related Quality of Life and return to work after surgery for spinal meningioma: A Population-Based Cohort Study. *Cancers (Basel)*. 2021;13:6371.
  5. Bayoumi AB, Laviv Y, Yokus B, Efe IE, Toktas ZO, Kilic T, Demir MK, Konya D, Kasper EM. Proposal of a new radiological classification system for spinal meningiomas as a descriptive tool and surgical guide. *Clin Neurol Neurosurg*. 2017;162:118-126.
  6. Hua L, Zhu H, Deng J, Tian M, Jiang X, Tang H, et al. Clinical and prognostic features of spinal meningioma: a thorough analysis from a single neurosurgical center. *J Neurooncol*. 2018;140:639-647.
  7. Kwee LE, Harhangi BS, Ponne GA, Kros JM, Dirven CMF, Dammers R. Spinal meningiomas: Treatment outcome and long-term follow-up. *Clin Neurol Neurosurg*. 2020 ;198:106238.
  8. Cao Y, Jiang Y, Liu C, Jin R, Jin Z, Hong X, et al. Epidemiology and survival of patients with spinal meningiomas: A SEER analysis. *Eur J Surg Oncol*. 2021;47:2340-2345.
  9. Haddad AF, Safaee MM, Pereira MP, Oh JY, Lau D, Tan LA, Clark AJ, Chou D, Mummaneni PV, Ames CP. Posterior-based resection of spinal meningiomas: an institutional experience of 141 patients with an average of 28 months of follow-up. *J Neurosurg Spine*. 2022;23:1-
-