

## Neglected paediatric talus neck fracture: A successful clinical outcome without post-traumatic complications

Burak Kuscu<sup>1</sup>, Kaan Gurbuz<sup>2</sup>, Fatih Dogar<sup>3</sup>

### Abstract

Paediatric talus fracture is an extremely rare type of fracture and occurs due to the structural properties of the elastic cartilage that is resistant to high forces. It has a much lower prevalence than in adults. The axial loading of the talus to the anterior tibia while the ankle is in dorsiflexion is the most common mechanism of talus fractures. Although talus neck fracture is the most common fracture, talus corpus fractures are the second most common. Here we present the case of an adolescent male patient who underwent a successful non-surgical treatment and follow-up of a neglected talus neck fracture.

**Keywords:** Children, Talus, Closed fracture, Avascular necrosis, Outcome.

**DOI:** <https://doi.org/10.47391/JPMA.9445>

### Introduction

Talus fractures are very rare, comprising nearly 0.008% of all childhood fractures.<sup>1</sup> Children's bone structure is considered to be less fragile because of its flexibility and skeletal immaturity. Since it has higher elastic resistance than that of adults, it probably must be exposed to higher forces before the fracture occurs.<sup>2</sup> The classification system used in adults can also be applied to children.<sup>3</sup> Based on the anatomical localisations, talus fractures can be classified as neck, corpus, peripheral, and osteochondral fractures. Fractures most commonly occur in the talus neck and talus corpus. The complications seen in adult talus fractures— are avascular necrosis, talar dome collapse, and tibiotalar arthrosis—which are also possible complications for childhood fractures.<sup>4</sup> While closed reduction and cast fixation treatment are sufficient for non-displaced fractures, surgical treatment may sometimes be required to minimise the risk of trauma-related avascular necrosis (AVN) due to impaired blood supply in displaced fractures.<sup>1,2</sup> Conversely,

<sup>1</sup>Clinical of Orthopaedics and Traumatology, Kahramanmaraş, Pazarcık State Hospital, Kahramanmaraş, Turkey; <sup>2</sup>Kayseri City Education and Research Hospital, Kayseri, Turkey; <sup>3</sup>Kahramanmaraş Sutcu Imam University, Kahramanmaraş, Turkey.

**Correspondence:** Burak Kuscu. e-mail: dr.burakkuscu@hotmail.com

ORCID ID: 0000-0002-1082-2206

**Submission complete:** 28-04-2023

**Review began:** 13-06-2023

**Acceptance:** 08-06-2024

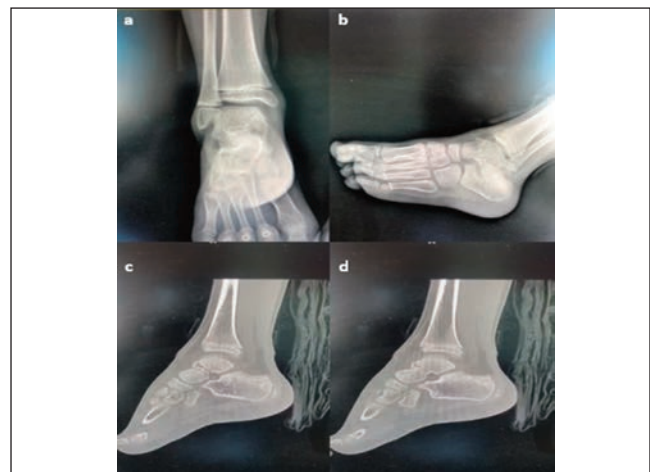
**Review end:** 14-03-2024

although the risk of developing AVN is very low in non-displaced fractures, a few cases of AVN in minimally displaced fractures have been reported.<sup>5</sup>

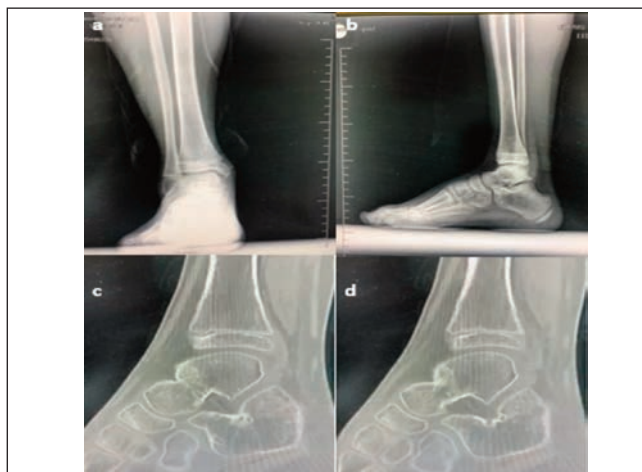
As reported by Buchan, Daniel DO et al., when a paediatric surgeon encounters a neglected paediatric talus neck fracture in a patient seeking treatment for minimal complications, deciding whether non-surgical or surgical treatment would be the best option has always been a dilemma.<sup>6</sup> While making this decision in light of the literature, surgeons stay in limbo due to lack of literature support. Therefore, this study aims to present the clinical outcomes of a neglected paediatric talus neck fracture caused by a simple trauma treated non-surgically with a cast without any complications including AVN.

### Case Report

An 11-year-old male presented to the Emergency Department of Pazarcık State Hospital, Turkey, in May 2022, due to a sprained ankle while playing football. The patient, who was evaluated in the emergency department, had no known disease, no medication, or history of surgery. His X-ray images (Figure 1a-1b) revealed no abnormalities; thus, he was discharged without orthopaedic consultation. An Orthopaedic Surgeon was consulted because of persistent pain and inability to step on his feet after two weeks. During the physical examination, ankle swelling, mild ecchymosis, and dorsal ankle pain were confirmed. Active



**Figure-1:** a & b) Anterior posterior and oblique emergency radiographs of the ankle joint; the neck of talus fracture was initially missed in the emergency department on these views; c & d) CT images demonstrating neck of talus fracture.



**Figure-2:** a & b) Anterior posterior view of the ankle after two months; c & d) CT images demonstrating healing of the fracture site at six months.

and passive ranges of motion of the ankle were painful and he could not bear weight on the affected foot. Computed tomography (CT) was requested which revealed a comminuted minimally displaced fracture of the talus neck (Figure 1c-1d). The patient was then hospitalised for a follow-up with a splint for three days in the orthopaedic service department and was discharged with a short leg circular cast. After six weeks of follow-up, the cast was finally removed, passive range of motion exercises were started, and partial weight bearing was advised. At the end of two months, the patient showed improvement on X-ray (Figure 2a-2b) and CT (Figure 2c-2d), and started walking with full weight bearing.

## Discussion

Paediatric talus fractures, which are less common than that of adults, can have devastating consequences if not treated properly and adequately with a meticulous regular follow-up. Since the elastic resistance of children's bone is higher than that of adults, it probably must be exposed to higher forces before the fracture occurs than in adults. The types of injuries described in the literature are traffic accidents and falling from a height. The fact that the talus neck fracture occurring in the patient in this case was caused by an impact trauma is a first in terms of literature contribution. As demonstrated in this case, sophisticated surgical interventions do not always achieve successful clinical outcomes compared to non-surgical treatment modalities.

There is no consensus on the literature yet regarding the prognosis of paediatric talus fractures and their early/late complications. For small, minimally displaced or non-displaced talus fractures in the younger paediatric age group before late puberty, non-surgical treatment with closed reduction and casting, if necessary, appears to be a

viable option. Surgery should be a good option for talus fractures in the older paediatric age group, and for displaced and comminuted fractures in any paediatric age group. These included supporting literature at which point the authors of this case report were confident that the appropriateness of the chosen treatment was confirmed. In their study, Meier et al. examining the long-term follow-up of 15 children with an average age of 10 years who had talus neck and corpus fractures, reported that closed reduction and casting were applied if necessary. They demonstrated that there were excellent clinical results in fractures other than types 2 and 3 according to Hawkins criteria<sup>7</sup> and they determined that arthrodesis was applied in those types of fractures.<sup>8</sup> Similarly, Smith et al. in their study that retrospectively examined 29 children with a mean age of 13.5 years with talus fractures concluded that they did not detect osteonecrosis in any child under the age of 12, regardless of the type of treatment, conservative or surgical.<sup>9</sup> The risk of developing complications in talus fractures is directly related to the amount of the initial fracture displacement. AVN development rates have been shown to be very low in paediatric series.<sup>10</sup> Thus, the final point for this case is the conservative treatment of choice.

Although literature data on AVN development rates as an early or late complication after paediatric talus fractures were inadequate, Eberl et al. showed that AVN was not observed in any of the children aged less than 12 years in their series, whereas AVN developed in one out of every three children aged >12 years. They recommended that the age of 12 years should be considered the limit, and surgery should be performed for displaced comminuted fractures in children aged 12 and above.<sup>2</sup> The clinical result of this case regarding AVN had the same clinical outcome with the literature including the cut-off value of age.

Physicians who are not inclined to evaluate trauma patients in the emergency department may miss fractures due to open epiphyses in the paediatric age group. For the first time in the literature, this case report showed that a rare paediatric talus neck fracture can occur due to impact trauma. Therefore, orthopaedic consultation should be sought in every suspected case, especially in the paediatric age group, in order not to miss possible fractures and their treatments.

## Conclusion

If any clinical suspicion exists, CT should be advised for certain difficult-to-diagnose fractures. AVN is less likely to be associated with minimally displaced and non-displaced fractures, although it may occur despite the type of treatment. This requires regular meticulous clinical follow-up.

**Ethical Approval:** This article does not contain any studies with human participants or animals performed by any of the authors. A written informed consent was obtained from the patient's legal guardians and/or parents for the publication of his/her images and other clinical information.

**Disclaimer:** None.

**Conflict of Interest:** None.

**Funding Sources:** The funders had no role in the study design, data collection, analysis, decision to publish, or preparation of the manuscript.

## References

1. Monestier L, Riva G, Faoro L, Surace MF. Rare shear-type fracture of the talar head in a thirteen-year-old child - Is this a transitional fracture: A case report and review of the literature. *World J Orthop* 2021;12:329-37. doi: 10.5312/wjo.v12.i5.329.
2. Waseem S, Nayar SK, Vemulapalli K. Paediatric talus fractures: A guide to management based on a review of the literature. *Injury* 2022;53:1029-37. doi: 10.1016/j.injury.2021.12.024.
3. Huang X, Ruan S, Lei Z, Cao H. Anteromedial cannulated screw fixation for Hawkins II/III talus fractures in children: a retrospective study. *J Orthop Surg Res* 2023;18:765. doi: 10.1186/s13018-023-04253-y.
4. Ab Halim MAHB, Alias AB, Ahmad ARBH. A displaced talus fracture in paediatrics. *J Foot Ankle Surg Techn Rep Cases* 2022;2:100142. Doi: 10.1016/j.fastrc.2021.100142
5. Sidhu GAS, Hind J, Ashwood N, Kaur H, Lacon A. Talus Fracture Dislocation Management With Crossed Kirschner Wires in Children. *Cureus* 2021;13:e13801. doi: 10.7759/cureus.13801.
6. Buchan D, Gill LEA. Neglected talar fracture-dislocation in a paediatric patient. *Curr Orthop Pract* 2018;29: 278-82. DOI: 10.1097/BCO.0000000000000618
7. Hawkins LG. Fractures of the neck of the talus. *J Bone Joint Surg Am* 1970;52:991-1002.
8. Carpenter BB, Williams ML. Fractures of the Pediatric Foot and Ankle. In: Butterworth M, Marcoux J, eds. *The Pediatric Foot and Ankle*. Cham, Switzerland: Springer Nature Switzerland AG, 2020; pp 257-79. doi: 10.1007/978-3-030-29788-6\_14.
9. English CJ, Merriman DJ, Austin CL, Thompson SJ. Open Reduction and Internal Fixation of a Pediatric Talar Body Fracture using a Medial Malleolar Osteotomy - A Case Report. *J Orthop Case Rep* 2021;11:30-2. doi: 10.13107/jocr.2021.v11.i10.2454.
10. Hamoudi C, Doljencu A, Illes T. Avascular necrosis of the talus causing meniscoid lesions in the ankle joint: a case report. *J Med Case Rep* 2022;16:83. doi: 10.1186/s13256-022-03298-7.

## Author Contribution:

BK: Design, drafting, revision, final approval and agreement to be accountable for all aspects of the work.

KG: Design, drafting, revision and final approval.

FD: Design, final approval and agreement to be accountable for all aspects of the work..