

## Pneumopericardium in a child – “halo sign” on chest x-ray: A Case Report

Alina Sadaf<sup>1</sup>, Aqeela Rashid<sup>2</sup>, Sadia Omer<sup>3</sup>

### Abstract

A 5 year old boy with acute lymphoblastic leukaemia on chemotherapy presented with chest pain and vomiting for two days after an elective procedure under general anaesthesia. His chest x-ray was remarkable for a prominent halo sign, an air gap surrounding the heart indicating a large pneumopericardium. Although the pneumopericardium could not be appreciated on an echocardiogram, the child developed clinical signs of cardiac tamponade. Attempts to evacuate the pneumopericardium were unsuccessful leading to death.

**Keywords:** Pneumopericardium, Halo sign.

**DOI:** <https://doi.org/10.47391/JPMA.9393>

### Introduction

Pneumopericardium is the term used to describe air in the pericardial space. It is a rare but life-threatening condition associated with approximately 50% mortality.<sup>1</sup> In children, it may arise spontaneously or because of infection, asthma exacerbation, ventilation-associated barotrauma, or external trauma.<sup>2-4</sup> It is important for clinicians to identify the radiologic sign of pneumopericardium to act in a timely manner. We present this case to highlight the radiographic appearance of pneumopericardium and describe the difficulty associated in diagnosing the condition with echocardiography.

### Case Report

A 5-year-old boy diagnosed with precursor B cell acute lymphoblastic leukaemia completed a month of induction chemotherapy. He underwent an elective procedure under general anaesthesia for a bone marrow biopsy and intrathecal chemotherapy administration. Two days after the procedure, he presented to the paediatric oncology clinic with symptoms of vomiting and chest pain. He was referred to the emergency room for evaluation. On examination, he was noted to have tachycardia,

<sup>1,2</sup>Department of Pediatric Oncology, Shaukat Khanum Memorial Cancer Hospital and Research Centre, Lahore, Pakistan; <sup>3</sup>Department of Pediatric Intensive Care, Shaukat Khanum Memorial Cancer Hospital and Research Centre, Lahore, Pakistan.

**Correspondence:** Alina Sadaf. e-mail: [alina.sadaf@gmail.com](mailto:alina.sadaf@gmail.com)

ORCID ID. 0000-0002-1377-8757

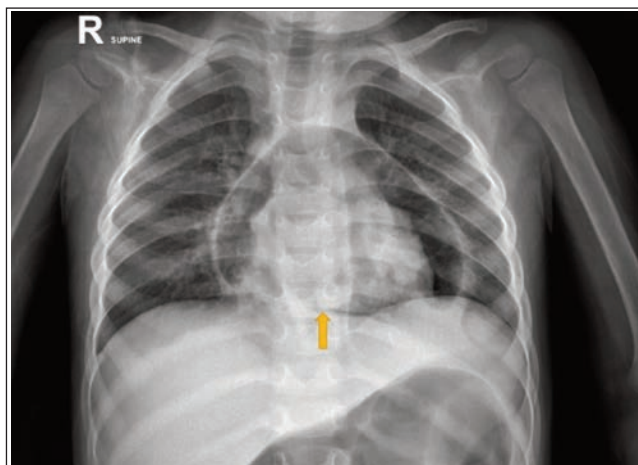
**Submission complete:** 28-04-2023

**Review began:** 07-06-2023

**Acceptance:** 18-11-2023

**Review end:** 17-09-2023

tachypnoea and decreased breath sounds on both sides of the chest. A chest x-ray was performed (Figure). The image was striking for the presence of a large air-filled lucency surrounding the heart shadow, an exaggerated halo sign. In addition, the diaphragm was continuously visible behind the mediastinum known as the continuous diaphragm sign. Notably, there was no air in the pleural space or in the subcutaneous tissue. An echocardiogram was performed which could not identify the pneumopericardium but an artefact and poor window was noted. Approximately 6 hours after admission, the child developed hypoxia and rapid hypotension and could not be stabilized to attempt a Computed tomography (CT)-guided pericardiocentesis. Bedside ultrasound guided pericardiocentesis failed due to difficulty in finding the air pocket. The patient went into pulseless cardiac arrest and could not be revived.



**Figure:** Supine chest radiography shows prominent air lucency around the heart shadow known as the “halo sign”. The yellow arrow indicates the “continuous diaphragm sign”.

### Discussion

It is rather unusual that the patient in this case developed pneumopericardium after elective general anaesthesia of a short duration. Presumably, the pneumopericardium developed due to inadvertent barotrauma injury causing air leak in the pericardium. Alternatively, the child may have developed subclinical pericarditis that lead to pneumopericardium but this is a less likely scenario. Chest x-ray is a sensitive and specific radiologic tool to quickly and inexpensively identify pneumopericardium. The classic findings are the halo sign and continuous diaphragm sign

as demonstrated in this case.<sup>5</sup> Additional findings may include pneumomediastinum with air tracking along with the superior mediastinal structures and occasionally reaching the subcutaneous tissues of the neck producing subcutaneous emphysema. Importantly, pneumopericardium may be difficult to identify on an echocardiograph. Air in the pericardial space creates an artefact that obscures the view of the heart and technicians may mistake this for a poor window. This should not distract the clinician from a diagnosis of pneumopericardium that has been established on a chest x-ray.<sup>6</sup> However, echocardiography is still important to evaluate the cardiac function for identifying cardiac tamponade physiology. In this patient's case, echocardiography could not identify the pneumopericardium and the cardiac function was reported as normal by the technician. But the child had clinical evidence of tamponade presenting as hypotension which prompted the clinicians to attempt bedside pericardiocentesis. This highlights the importance of clinical evaluation for the diagnosis of cardiac tamponade. A CT guided pericardiocentesis is the preferred method in a haemodynamically stable patient while bedside pericardiocentesis should be attempted if there is a haemodynamically compromised patient but it still may be difficult to identify the air pocket using an ultrasound technique.

### Conclusion

Pneumopericardium is a rare but lethal complication of barotrauma caused during general anaesthesia. Although easily identified on a plain chest radiograph as a halo sign, it may be missed on an echocardiogram. Prompt intervention with pericardiocentesis can prevent death due to cardiac tamponade.

**Consent:** Written consent for publishing the case report could not be obtained from the guardians during hospitalization and after discharge they could not be located. Anonymity has been maintained.

**Disclaimer:** None.

**Conflict of interest:** None.

**Funding disclosure:** None.

### References

1. Cummings RG, Wesley RL, Adams DH, Lowe JE. Pneumopericardium resulting in cardiac tamponade. *Ann Thorac Surg* 1984;37:511-8. doi: 10.1016/s0003-4975(10)61146-0
2. Rosenbaum AE, Schweppe HI JR, Rabin ER. Constrictive pericarditis, pneumopericardium and aortic aneurysm due to histoplasma capsulatum. *N Engl J Med* 1964;270:935-8. doi: 10.1056/NEJM 196404302701805
3. Maxson IN, Chandnani HK, Lion RP. The Heart's Halo: Caring for Pediatric Pneumopericardium. *J Pediatr Intensive Care* 2018;7:213-5. doi: 10.1055/s-0038-1653981
4. Fulda G, Brathwaite CE, Rodriguez A, Turney SZ, Dunham CM, Cowley RA. Blunt traumatic rupture of the heart and pericardium: a ten-year experience (1979-1989). *J Trauma* 1991;31:167-72
5. Khan AN, Al-Jahdali H, Al-Ghanem S, Gouda A. Reading chest radiographs in the critically ill (Part I): Normal chest radiographic appearance, instrumentation and complications from instrumentation. *Ann Thorac Med* 2009;4:75-87 doi: 10.4103/1817-1737.49416
6. Reid CL, Chandraratna AN, Kawanishi D, Bezdek WD, Schatz R, Nanna M, Rahimtoola SH. Echocardiographic detection of pneumomediastinum and pneumopericardium: the air gap sign. *J Am Coll Cardiol* 1983;1:916-21. doi: 10.1016/s0735-1097(83)80209-5

### Author Contribution:

AS: Concept, design and initial drafting

AR: Contributed to the study design and editing

SO: Contributed to the design, image and editing of the manuscript

All authors have approved the final manuscript as submitted and agree to be accountable for all aspects of the work