

An unusual case of long-standing retained nasopharyngeal foreign body

Maimoona Shafqat, Seema Naveed, Ambreen Riaz, Muhammad Zafar Rabbani

Abstract

The nasopharynx is a rare anatomical location where a foreign body may become lodged after being ingested or inhaled. We are presenting a rare case of nasopharyngeal foreign body impaction in a two-and-a-half-year-old child that had been missed for almost a year. The child presented with a history of right-sided foul-smelling nasal discharge, snoring and mouth breathing. An X-Ray soft tissue lateral view of the post-nasal space showed an irregular partially radiopaque nasopharyngeal foreign body. The removal of the foreign body was performed under general anaesthesia successfully. Foreign body impaction in the nasopharynx can easily be missed and it is important to keep this region in mind when dealing with missing inhaled or ingested foreign bodies.

Keywords: nasopharynx, snoring, mouth breathing, radiopaque.

DOI: <https://doi.org/10.47391/JPMA.9051>

Introduction

Most inhaled foreign bodies pass either into the trachea or the esophagus. Nasopharyngeal foreign body impaction is uncommon therefore they can go undetected for months or years still if a patient presents with symptoms of nasal obstruction, snoring, mouth breathing and foul-smelling nasal discharge, nasal or a nasopharyngeal foreign body should be suspected and possible investigations should be carried out. Here we reported a case of a wheel of a toy car, retained as a foreign body in the nasopharynx for almost 1 year.

Case Report

On November 30, 2022, a two-and-a-half-year-old child presented in the ENT Outpatient Clinic, of Shifa Tameer-e-Millat University, Islamabad, Pakistan, with complaints of mouth breathing and snoring, along with foul-smelling nasal discharge. According to the mother, while playing with a car toy, he accidentally swallowed the wheel of a toy car and choked one year ago. His grandmother tried

.....
Department of ENT, Shifa Tameer-e-Millat University, Islamabad, Pakistan

Correspondence: Maimoona Shafqat. Email: maimoonashafqat@gmail.com

ORCID ID. 0000-0003-3963-4214

Submission complete: 15-04-2023

Review began: 12-06-2023

Acceptance: 16-12-2023

Review end: 05-11-2023

to remove it but could not. Meanwhile, the child got cyanosed and was taken to the Quaid-e-Azam international hospital, Rawalpindi. While going to the hospital, the attendant held the child upside down leading to vomiting on the way to the hospital and later in the hospital. The vomitus contained saliva and yellow-coloured fluid that was blood-stained. After these episodes, the child became stable. X-Rays of neck, chest, abdomen, along with an abdominal ultrasound was done that showed no abnormality.

The child's condition remained stable for a month. After that, he began to have difficulty swallowing and saliva started dribbling from the mouth, which was dark and slightly blood-stained. He had dark-colored stools as well. The child was taken to multiple hospitals, but the exact cause of his condition remained unknown. He took medicines and remained stable for a few months. After 4 months, he developed the same symptoms again and got better with medication. For the last month, the patient developed complete mouth breathing, snoring, and malodorous right-sided nasal discharge. He also had fever and difficulty in swallowing solid food.

On examination, nasal patency was absent on both sides and nasal examination showed purulent, foul-smelling, black-coloured discharge. X-Ray post-nasal space lateral view showed an irregular, partially radio-opaque shadow in the post-nasal space, suggestive of a retained foreign

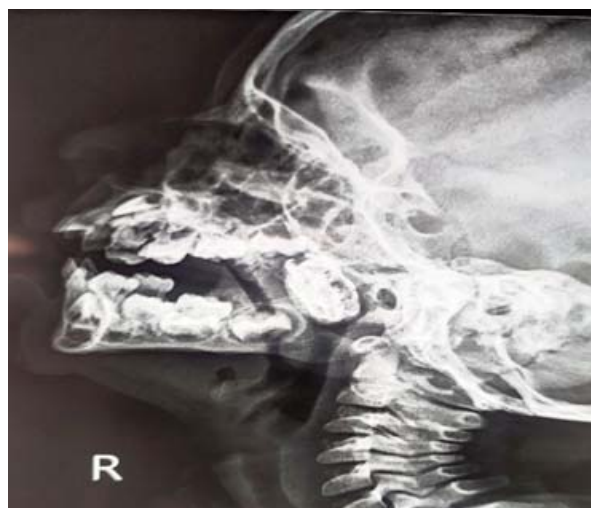

Figure-1: Pre-operative X-Ray soft tissue of nasopharynx lateral view showing foreign body.

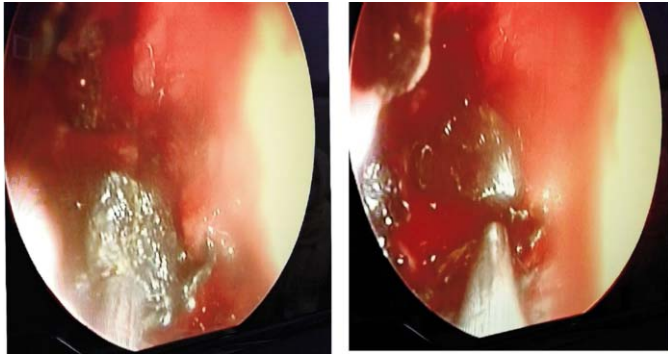


Figure-2: Endoscopic view of the nasopharynx showing the foreign body

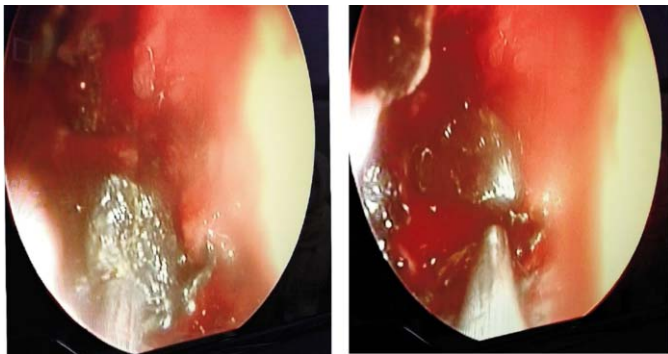


Figure-3: Foreign body removed from the nasopharynx object [Figure 1].

The removal of foreign body was planned under general anaesthesia. Endoscopic examination showed the complete obstruction of the nasopharynx by an irregular hard black material [Figure 2]. It was broken down into multiple fragments some of which were partially removed from the nasopharynx and some from the oropharynx. The large central core was pushed inferiorly into the oropharynx and removed with forceps. Detailed

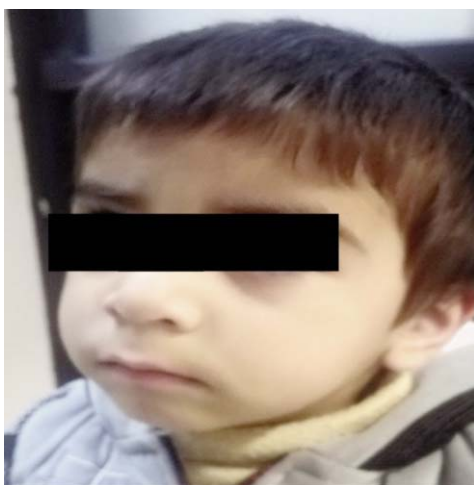

Figure-4: Picture taken at first follow-up.

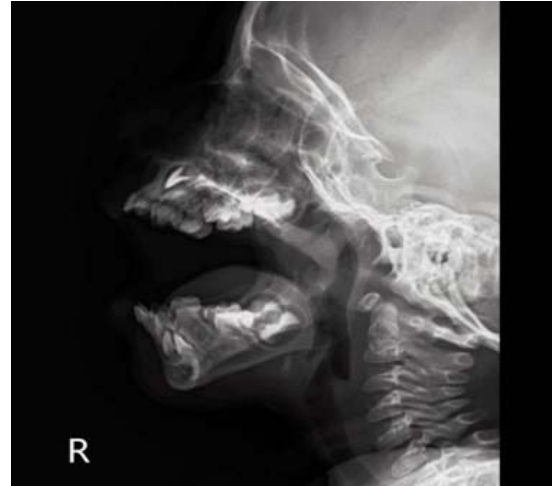


Figure-5: Post-operative X-Ray soft tissue nasopharynx lateral view.

inspection of the removed dark, friable material showed a central core of a plastic foreign body [Figure 3].

In the immediate postoperative period, the patient started breathing from the nose and had no foul-smelling nasal discharge. The patient remained asymptomatic until the next follow-up after 1 week [figure 4] and his postoperative X-Ray of nasopharynx was unremarkable [figure 5].

Discussion

Foreign objects may become lodged in any of the air passages, including the nose, throat, and bronchi, but are extremely uncommon in the nasopharynx. The most probable route for a foreign object to get lodged in the nasopharynx is through the nose but impaction after ingestion is less seen because the nasopharyngeal isthmus blocks the passage of a foreign object during ingestion. Vomiting or violent coughing after ingestion may force the foreign object to enter the nasopharynx. Sometimes, in an attempt to remove foreign body, parents put the child upside down and foreign body gets lodged in the nasopharynx¹.

It is essential that when a young patient presents with unilateral foul-smelling nasal discharge, the nose and nasopharyngeal foreign body should be ruled out. A Foreign body in the nasopharynx may present with persistent cough, chronic rhino sinusitis, or may remain asymptomatic^{2,3}. In some cases, the sign and symptoms of foreign body aspiration may be nonspecific, especially when aspiration is not witnessed. In that case, the diagnosis can be delayed or missed, which increases morbidity^{4,5}.

In the published literature, impaction of nasopharyngeal foreign objects is more common in the age group below

10 years, which is usually self-inflicted. Various foreign objects like a bottle cap¹, metallic ring², safety pins⁵, glass ball⁶, coin⁷, detached beverage cap⁸, ear plug⁹, long metallic hook¹⁰, fish bone¹¹ have been reported in the literature.

It has been observed that long-standing, undiscovered nasopharyngeal foreign bodies can lead to complications such as acquired development of a cleft palate and nasopharyngeal foreign bodies may even present with symptoms of adenoid hypertrophy and accidentally discovered during adenoidectomy⁵.

In cases of foreign body ingestion or inhalation, in addition to an X-Ray chest, neck, and abdomen, an X-Ray soft tissue post nasal space lateral view should be done as a part of routine radiological investigation, especially if a patient has co-existing nasal obstruction. X-Ray in these patients are a simple investigation that can detect a radiopaque foreign object. If a suspected nasopharyngeal foreign object is not radiopaque then nasopharyngoscopy can be carried out for diagnosis⁶.

In our case, the long-standing nasopharyngeal foreign body remained undetected for several months. The possible explanation for how the foreign body got lodged in the nasopharynx after being ingested is the possibility of the object being moved upwards after violent coughing and vomiting. Another article reveals a case of ingestion of a metallic ring at the age of 3 months with long-standing symptoms of halitosis; however, the investigations did not reveal pathology. At the age of 4 years, an X-Ray of nasopharynx revealed a foreign body in the nasopharynx which was removed under general anaesthesia which led to the relief of symptoms caused due to the obstruction.

Conclusion

Our case presented with unilateral foul-smelling nasal discharge for last one year and was diagnosed as having a foreign body in the nasopharynx by a simple X-Ray of the

nasopharynx.

The object was removed under general anaesthesia. Therefore, it is concluded that X-Ray nasopharynx and endoscopic examination of the nasopharynx should be a part of routine investigation in a patient of paediatric age group presenting with suspected foreign body ingestion and continuous unilateral foul-smelling nasal discharge.

Disclaimer: None to declare.

Conflict of Interest: None to declare.

Funding disclosure:None to declare.

References

1. Gupta G, Gupta V, Singla A, Kaur G, Raheja V, Verma N. Nasopharynx harboring ingested foreign bodies: Two case reports. *Saudi J Otorhinolaryngol Head Neck Surg* 2021;23:75-7.
2. Freni JK, Jo JK, Sankar P. An unusual long standing metallic foreign body in nasopharynx in an adult. *Int J Otorhinolaryngol Head Neck Surg* 2021;7:1540-3.
3. Abraham ZS, Massawe ER, Mapondella KB, Kahinga AA, Mithe S, Ntunaguzi D. A rare incidental encounter of a foreign body in the nasopharynx during adenotonsillectomy: a case report from Tanzania. *Medical Journal of Zambia* 2019; 46: 367 -70.
4. Thakkar H. Foreign body metal safety pin in nasopharynx. *Indian Journal of Clinical practice* 2020; 30:852.
5. Mahdy Mohammed Nassar. A Rare Incidental Encounter of a Foreign Body in the Nasopharynx during Endoscopic Assisted Adenoidectomy. *Nassar. J Otolaryngol Rhinol* 2022 8:124-6.
6. Ritesh Nandwani, Ashok Kumar. An unusual nasopharyngeal foreign body with unusual presentation. *IAIM* 2022; 9: 30-2.
7. Mori T, & Inoue N. Nasopharyngeal foreign body triggered by a blind finger sweep. *BMJ Case Rep* 2016.
8. Hamidi H, Rastin MS. A rare nasopharyngeal foreign body (detached beverage can stay-tab): A case report. *Radiol Case Rep* 2022; 17:4690-3.
9. Alshehri WM, Al-Qahtani B. A Rare Incidental Finding of a Foreign Body in the Nasopharynx during Adenotonsillectomy. *Case Rep Otolaryngol* 2018;2018.
10. Chatterjee P, Vasamsetty VP, Das C, Das SK. Impaled Nasopharyngeal Foreign Body. *Bengal Journal of Otolaryngology and Head Neck Surgery*. 2020;28:285-8.
11. Kołodziejczyk P, Sokołowski J, Gotlib T, Morawski R, Niemczyk K. Foreign body in nasopharynx—case report. *Polski Przegląd Otorinolaryngologiczny* 2017;6:47-50.

Authors' Contributions

MS: Writing the original case report.

SN, AR: Data collection.

MZR: Made the substantial contribution to the concept, supervision.