

Paraganglioma of the urinary bladder: A case report

Muzammil Hassan, Abdul Hafeez Quereshi

Abstract

It is very uncommon to discover Paragangliomas in the urinary bladder. These tumours originate from the sympathetic nerves which supply chromaffin cells in the bladder wall. They can be classified as functional or non-functional. If functional, the most common presentations are with hypertensive crisis or post-micturition syncope. A silent paraganglioma of the bladder can be easily misdiagnosed which can result in severe peri-operative morbidity. We present a case of a male patient who was being managed for hypertension for 2-3 years. He presented at The Indus Hospital, Karachi on 7th August 2022 with gross painless haematuria. An ultrasound scan revealed an echogenic lesion arising from base of the urinary bladder, which was treated via Transurethral Resection of Bladder Tumour (TURBT). Histopathological report revealed Paraganglioma of the Bladder. He was later scheduled for Partial Cystectomy (PC) and has been doing well ever since.

Keywords: Paraganglioma, Bladder tumour, Partial cystectomy, Extra-adrenal paraganglioma, Transurethral Resection of Bladder Tumour, Computed tomography.

DOI: <https://doi.org/10.47391/JPMA.8415>

Introduction

Chromaffin cell tumours of the adrenal medulla are known as pheochromocytomas, and these are of neural crest origin. When occurring at extra-adrenal sites, these tumours are known as Paragangliomas and the reported incidence is 10%.^{1,2} In the urinary bladder, these tumours are usually functional and symptomatic.³ Paragangliomas of the bladder are very uncommon and account for 0.06% of all bladder tumours.⁴⁻⁶

This case highlights one of the rarest late presentations of this tumour, emphasizing the need for an early and prompt diagnosis.

Case Report

A 47 years old male, known case of hypertension was presented in our Out Patient Department of The Indus

Department of Urology, The Indus Hospital, Karachi, Pakistan.

Correspondence: Muzammil Hassan. e-mail: muzammilhassan1@gmail.com

ORCID ID. 0009-0007-4317-2063

Submission complete: 04-12-2022

Review began: 16-01-2023

Acceptance: 02-12-2023

Review end: 05-08-2023

Hospital, Karachi on 7th of August 2022 with the presenting complaint of gross, painless haematuria along with passage of amorphous clots since 20 days. It was his first presentation to any health care facility for the above mentioned symptoms. Physical examination was unremarkable. Urine analysis suggested 8-10 red blood cells/HPF and few pus cells whereas the culture was negative for any growth. Ultrasound scan demonstrated an echogenic lesion arising from base of urinary bladder measuring 1.8cm x 1.1cm x 1.6cm showing some vascularity [Figure 1].

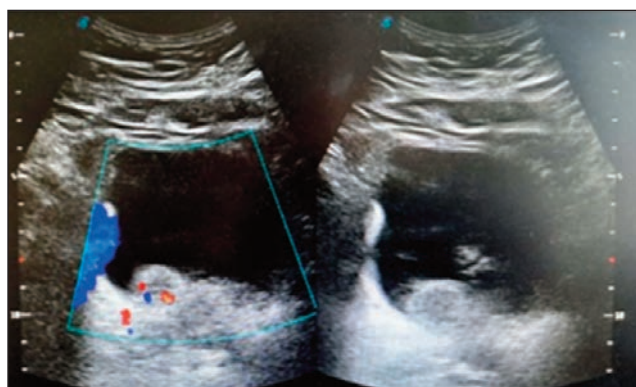


Figure-1: Ultrasound Image showing bladder growth.

On basis of ultrasound finding, Transurethral Resection of Bladder Tumour (TURBT) was done and the operative finding was single broad based spherical hypervascular growth seen on posterior wall of bladder measuring approximately 2cm x 2cm. The growth was also resected and sent for histopathology. Patient remained stable before, during and after the surgery. Histopathological examination of the TURBT specimen showed multiple fibrocollagenous tissue fragments arranged in nests and surrounded by thin walled blood vessels. Cells were round to oval exhibiting monomorphic round nuclei with ample

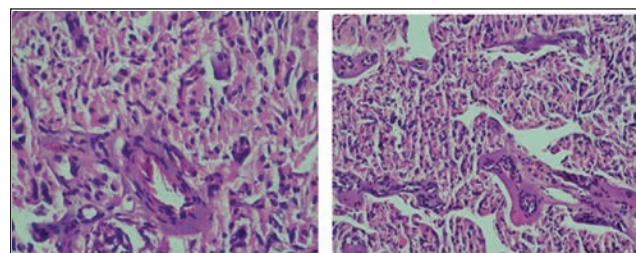


Figure-2: Histopathology specimen showing round to oval cells with round nuclei arranged in nests surrounded by thin walled blood vessels.

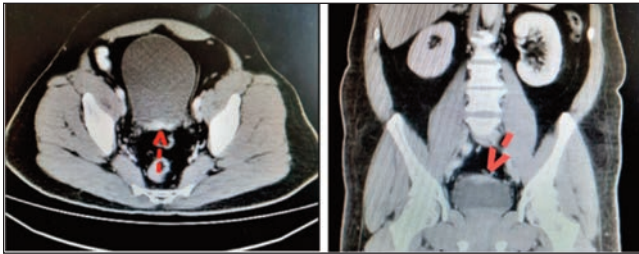


Figure-3: Red arrows in both pictures pointing at bladder growth arising from base and along the posterior wall

eosinophilic cytoplasm [Figure 2]. These features were consistent with paraganglioma, however no muscle involvement was seen. Immunohistochemistry was strongly positive for synaptophysin and chromogranin, while negative for cytokeratin and uroplakin-III that again was in favour of paraganglioma.

At 1 month postoperatively, plasma metanephrines and normetanephrines were checked; which were normal. A contrast enhanced computed tomography (CT) scan of kidney, ureter and bladder was also done which showed an irregular enhancing soft tissue at the base of urinary bladder and along the posterior wall measuring 3.9 cm in transverse diameter with maximum antero-posterior diameter of 1.1cm on axial section [Figure 3]. An MIBG (metaiodinebenzylguanidine) scan revealed the presence of this tumour in the urinary bladder and there was no evidence of extra-vesical spread.

On basis of biopsy and CT scan report, an open Partial Cystectomy was done and specimen was sent for biopsy. Histopathology report showed same paraganglioma of the bladder, as of TURBT. Currently, patient is doing well and is on regular follow-up with history, physical examination and serum nephtrines and metanephrines.

Discussion

Paragangliomas account for 6% of all extra-adrenal pheochromocytomas.¹ In the urinary tract, the commonest site is the bladder, followed by the urethra, the pelvis and the ureter accounting for 79.2%, 12.7%, 4.9% and 3.2% of all urologic paragangliomas respectively.^{4,5} The usual intra-vesical locations are at the dome or near the trigone. These tumours are of neural crest origin and arise from the chromaffin cells in the bladder wall.^{3,6,7} Das et al. reported that the commonest presentations of a bladder paraganglioma can range from macroscopic haematuria to severe uncontrolled hypertension leading to seizures upon micturition.⁸ Certain stimuli have been identified, pertaining to these unusual tumours. These include micturition, bladder distension, stool passage, sexual intercourse or bladder instrumentation.^{3,4,9} 17% of the bladder paragangliomas can be asymptomatic³ About 60% of the reported cases had painless haematuria as their

presenting complain; similar to the usual presentation of all varieties of bladder tumours.^{3,6,9} A Contrast CT scan is commonly used for the detection of primary tumour and metastatic disease. Magnetic resonance imaging (MRI) can also be used. However, the sensitivity and specificity of 131 Iodine metaiodinebenzylguanidine (MIBG) scan is highest for the detection of pheochromocytoma.⁵ Post-operative surveillance of a patient with paraganglioma should include investigations which help in the evaluation of the functional status as well as the assessment of the catecholamine synthesis, storage and secretion pathway.^{3,5} Plasma and/or urine catecholamine levels are important in the initial workup of symptomatic patients and also in the follow-up afterwards. Sensitivity and specificity of plasma metanephrines is more than the urinary metanephrines for these tumours.^{3,4,6} In all, 88 % of the bladder paragangliomas show markedly elevated urine metanephrine and serum catecholamine levels.^{10,11} Bladder paragangliomas usually become clinically evident during the third decade of life and have a female preponderance.³

On cystoscopy, paraganglioma appears as a yellow submucosal lesion.³ On histopathology, tumours are surrounded by highly vascular fibrous network and the tumour cells are polygonal with the granular cytoplasm arranged in a Zellballen pattern.^{1,9,12} Neuroendocrine markers, such as neuron-specific enolase, chromogranin and synaptophysin are positive on immunohistochemical analysis for these tumours and they are negative for urothelial marker cytokeratin.^{9,12} Complete surgical resection is the mainstay of the treatment. Majority of these tumours are usually muscle invasive, hence partial cystectomy is preferred over transurethral resection.^{3,4,6} These tumours are non-malignant, however the chance of recurrence is high.³ Total cystectomy is considered when the lesion is large and bladder preservation is impossible or in the presence of lymph node metastasis.^{3,4,6} These tumours are resistant to chemoradiotherapy (adjuvant or neoadjuvant), although it has been used in some settings.¹³

Conclusion

A rare case of a hypertensive male patient was presented who underwent TURBT after episodes of gross painless haematuria. The histopathology report showed paraganglioma of urinary bladder, so partial cystectomy was done after radiologically staging the disease. Currently, he is on regular follow-up with history, examination and measurements of plasma/ urinary metanephrines and doing well.

Consent: Consent for publication of the case report was provided by the patient.

Disclaimer: None.

Conflict of Interest: None.

Funding Sources: None.

References

1. Leestma JE, Price Jr EB. Paraganglioma of the urinary bladder. *Cancer* 1971;28:1063-73.
2. Sonmez G, Tombul ST, Golbasi A, Demirtas T, Akgun H, Demirtas A. Symptomatic paraganglioma of the urinary bladder: A rare case treated with a combined surgical approach. *Urol Case Rep* 2020;33:e101290. doi: 10.1016/j.eucr.2020.101290.
3. Al-Zahrani AA. Recurrent urinary bladder paraganglioma. *Adv Urol* 2010;2010:912125. doi: 10.1155/2010/912125.
4. Hanji AM, Rohan VS, Patel JJ, Tankshali RA. Pheochromocytoma of the urinary bladder: a rare cause of severe hypertension. *Saudi J Kidney Dis Transpl* 2012;23:813-6. doi: 10.4103/1319-2442.98167.
5. Dahm P, Gschwend JE. Malignant non-urothelial neoplasms of the urinary bladder: a review. *Eur Urol* 2003;44:672-81. doi: 10.1016/s0302-2838(03)00416-0.
6. Sheps SG, Jiang NS, Klee GG, van Heerden JA. Recent developments in the diagnosis and treatment of pheochromocytoma. *Mayo Clin Proc* 1990;65:88-95. doi: 10.1016/s0025-6196(12)62113-2.
7. Kratiras Z, Kaltsas A, Koufopoulos N, Adamos K, Chrisofos M. Paraganglioma of the Urinary Bladder: A Case Report on a Rare and Unexpected Tumor Location. *Cureus* 2023;15:e41998. doi: 10.7759/cureus.41998.
8. Das S, Bulusu NV, Lowe P. Primary vesical pheochromocytoma. *Urology* 1983;21:20-5. doi: 10.1016/0090-4295(83)90116-4.
9. Chen CH, Boag AH, Beiko DT, Siemens DR, Froese A, Isotalo PA. Composite paraganglioma-ganglioneuroma of the urinary bladder: a rare neoplasm causing hemodynamic crisis at tumour resection. *Can Urol Assoc J* 2009;3:E45-8. doi: 10.5489/cuaj.1160.
10. Whalen RK, Althausen AF, Daniels GH. Extra-adrenal pheochromocytoma. *J Urol* 1992;147:1-10. doi: 10.1016/s0022-5347(17)37119-7.
11. Nakajima A, Ide H, Kitamura K, Muto S, Yamaguchi R, Horie S. Rare case of temporally spontaneous regression of retroperitoneal paraganglioma. *Int J Urol* 2015;22:421-2. doi: 10.1111/iju.12724.
12. Zhou M, Epstein JI, Young RH. Paraganglioma of the urinary bladder: a lesion that may be misdiagnosed as urothelial carcinoma in transurethral resection specimens. *Am J Surg Pathol* 2004;28:94-100. doi: 10.1097/00000478-200401000-00011.
13. Ibuki N, Komura K, Koyama K, Inamoto T, Segawa N, Tanimoto K, et al. A pheochromocytoma of urinary bladder treated with neoadjuvant chemotherapy. *Hinyokika Kiyo* 2009;55:765-8.

Author Contribution:

AHQ: Study concept, proofreading, revision, final approval.

MH: Initial idea, Data collection and compilation, writing and final approval.