

## Combined medial and lateral bucket handle meniscus tears with associated complete anterior cruciate ligament tear: A case report

Muhammad Amir Sohail, Amna Bashir, Umair Ul Hassan

### Abstract

The majority of meniscal tears in bucket handles are associated with anterior cruciate ligament (ACL) impairment. Its a rare condition which is rarely encountered when the meniscus has a bucket handle on both sides of the compartment. Here we present the case of a 28-year-old male cricket player with a total ACL rupture, a double Posterior Cruciate ligament (PCL) sign on MRI (Magnetic Resonance Imaging), an uncommon occurrence of a complex bucket handle rupture of the medial meniscus with a double PCL sign. It was a complete ACL tear and displaced bucket handle medial meniscus that was also visible on the magnetic resonance imaging. In this report, double PCL sign was shown on MRI and that was confirmed during the arthroscopic procedure.

**Keywords:** Complete ACL tear, combined medial & lateral bucket handle, meniscus tears.

**DOI:** <https://doi.org/10.47391/JPMA.8153>

**Submission completion date:** 10-11-2022

**Acceptance date:** 25-05-2023

### Introduction

Major functions of the knee menisci include load transfer, stress absorption, joint stability, and joint lubrication. Partial or more specifically, complete meniscectomy results in long-term degenerative effects.<sup>1</sup> An anterior cruciate ligament injury can occur with a variety of meniscus injuries. In comparison to the lateral meniscus, medial meniscus tears are three times as common.<sup>2</sup> However, only around 30% of cases include bicompartamental bucket handle tears, which are extremely rare.<sup>3</sup> A bucket-handle meniscal tear (BHMT) is a longitudinal tear that is vertical or oblique and has an attached fragment that has moved away from the periphery of the meniscus. Only 10% of all meniscal lesions are bucket handle meniscal tears (BHMTs), which are rarely present.<sup>4</sup> It appears as the dislocated meniscal fragment in front of the PCL substance, giving the impression that there are two PCLs. This is referred to as the double PCL sign, which was first noticed by Weiss. et al.<sup>5</sup> A complete anterior cruciate ligament tear and

Department of Orthopaedics, Jinnah Hospital, Lahore, Pakistan.

**Correspondence:** Amna Bashir. e-mail: Amnabashir03@gmail.com

ORCID ID. 0000-0001-6692-1724

concurrent lateral and lateral bucket handle meniscus injuries are reported in this case study. Consent of the patient was taken before publishing this case.

### Case Report

A 28 years-old male presented in Jinnah Hospital Lahore, Pakistan in March 2022 with complaint of pain and intermittent locking of right knee for 4 months following a twisting injury while playing cricket. The pain became worse during walking and running. The patient was unable to walk on his own without an assistive device due to pain. On physical examination, there was swelling on both lateral and medial side of the right knee. Anterior drawer and Lachman test for knee stability were positive. Furthermore, McMurray test for both menisci was also positive. No bone fracture was visible on the plain radiograph.

Magnetic resonance imaging (MRI) showed full thickness tear of anterior cruciate ligament from the femoral attachment site. Complex medial meniscus rupture caused by a bucket handle tear with a double PCL sign and displaced meniscus along the anterior part of the intercondylar notch was also noted. The anterior horn of the lateral meniscus also had a complicated tear.

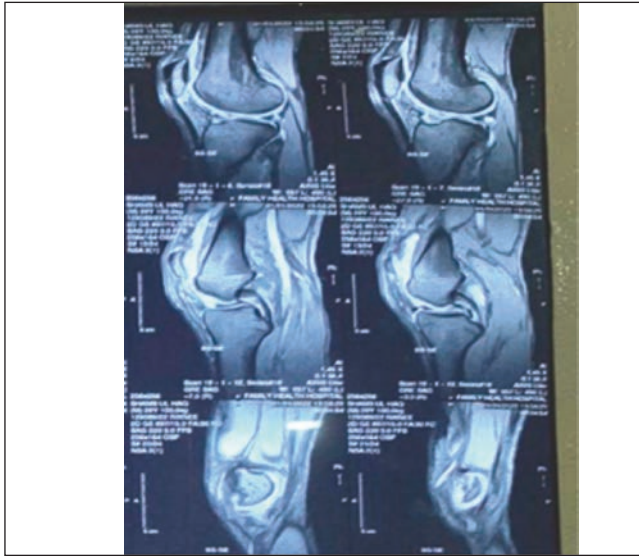
After taking the informed consent, the patient underwent an arthroscopic operation in supine position with applying the tourniquet, under spinal anaesthesia. Arthroscopic inspection of the whole knee joint revealed torn menisci, both lateral and medial with bucket handle deformity. Medial and lateral meniscus repair was done with all inside meniscus repair device. This was followed by identifying and re-constructing the torn anterior cruciate ligament with hamstring graft.

### Discussion

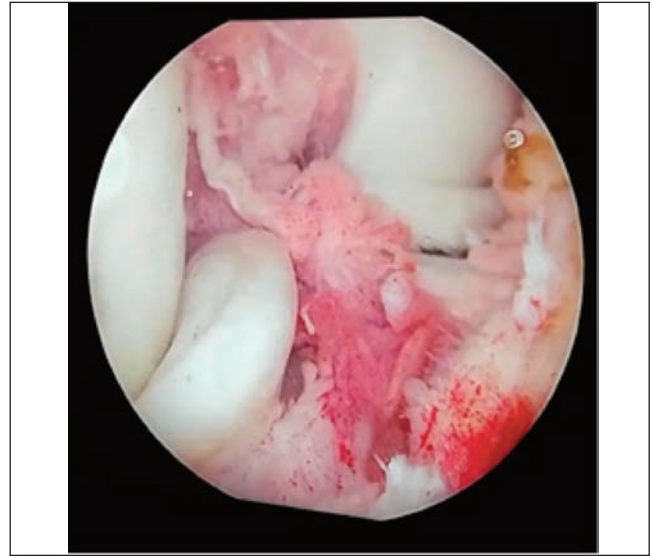The case of a 28-year-old male athlete with lateral and medial handle meniscus associated with tear has been presented.

Normally only one meniscus is torn along with ACL, bilateral Bucket handle meniscus tears are very rare. Therefore, double PCL sign was seen on MRI that was confirmed during arthroscopy.

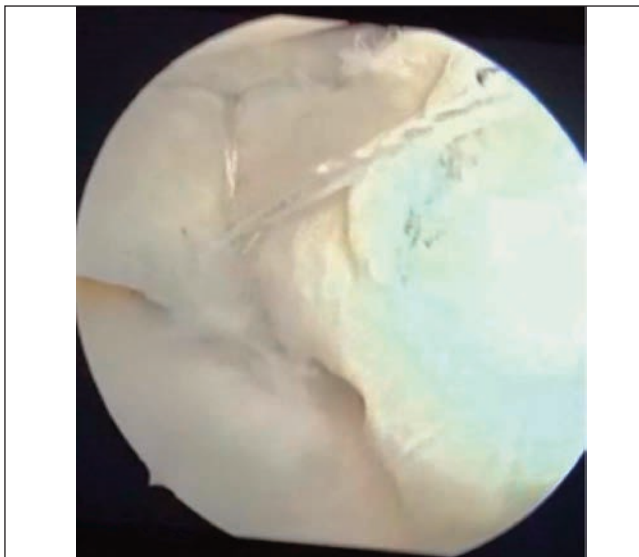
It is crucial to recognize this symptom in order to develop



**Figure-1:** Double PCL sign showing bucket handle tear.



**Figure-2:** Both medial and lateral meniscus bucket handle tear and complete ACL tear.

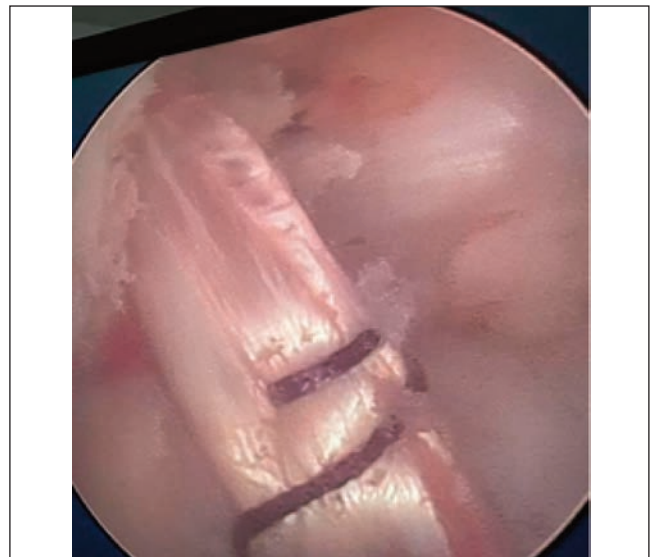

**Figure-3:** Meniscus Repair.

an appropriate preoperative diagnosis and treatment strategy. Santos et al. also described the symptom in a case with meniscus tears in both bucket handle compartments.<sup>3</sup> Due to more awareness and participation in athletic activities, the incidence of ACL rupture has increased.<sup>6</sup>

Another case described both compartment bucket-handle meniscus tears with an ACL injury.<sup>7</sup>

It has been estimated that 61 per 100,000 people experience an acute meniscal injury each year.<sup>8</sup> The similar authors calculate that 850,000 meniscal surgeries are carried out every twelve months in the US. BHMT injuries make up less than 10% of these injuries.<sup>9</sup>



**Figure-4:** Arthroscopic ACL Reconstruction.

MRI is thought to be the most effective imaging method for identifying meniscal tears in the knee and, as far as we are aware, the only imaging method that can forecast whether or not these tears will be repairable.<sup>10</sup> The double PCL sign was seen in our case. (Figure-1)

In a research done by Thoreux et al, 28 individuals were assessed who underwent knee arthroscopies in 2006 and were identified as having a BHMT at the time of surgery. An essential coronal imaging finding of a displaced meniscal fragment and one of the three abnormalities indicated below on sagittal slices led to the final diagnosis: (1) a double posterior cruciate ligament (PCL); (2) the flipped meniscus sign; or (3) a meniscal fragment within the intercondylar notch. (Figure-2).<sup>11</sup> According to the

**Table:** Presentation of the Triple-PCL sign in the previous case reports.

No.	Authors	Gender/Age (years)	Initial injury	Associated injury	Imaging/specific sign
1	Kakel et al (2010) <sup>13</sup>	Male/ 16	8 weeks	ACL tear	MRI/Triple-PCL sign, Quadruple-cruciate sign
2	Guillaume et al (2021) <sup>14</sup>	Female/ 37	Unknown	ACL tear	CT Arthrography/ Triple-PCL sign
3	Sales et al (2021) <sup>15</sup>	Male/ 16	10 months	ACL tear, Femoral condyle chondromalacia	MRI/TriplePCL Sign, Triple-cruciate sign
4	Santoso et al (2021) <sup>3</sup>	Male/ 21	12 months	ACL tear	MRI/Double PCL sign, Triple-PCL Sign, Triple cruciate sign
5	Present case	Male /28	4 months	Complete ACL tear	bucket handle tear with a double PCL sign

ACL: Anterior Cruciate Ligament; PCL: posterior Cruciate Ligament

outcomes of the arthroscopic examination and the MRI findings, the patient was subjected to the repair surgery. The medial meniscus and lateral menisci were repaired which would reduce the likelihood of subsequent osteoarthritic alterations. (Figure-3) The torn ACL was reconstructed with graft. (Figure-4)

One of the most crucial building blocks in the management of ACL repair is rehabilitation. Prior to undergoing ACL reconstruction surgery, all patients must complete a rigorous rehabilitation programme to increase their knee's useful range of motion and strengthen their quadriceps. The typical post-operative ACL rehabilitation regimen lasts 8 months, nevertheless the expedited programme takes over 4-5 months to complete.<sup>12</sup> According to the guidelines of our hospital, the patient in our study underwent a modified, accelerated ACL rehabilitation procedure.

The limitation of our case was the Low-resolution MRI machine in our institute due to which we were unable to see the triple PCL sign.

For evaluating the overall result, a randomized control trial at the national level with long-term follow-up is suggested. The comparisons between the cases are presented in Table.

## Conclusion

In a rare instance of both bucket-handle meniscus tears, several particular imaging findings, including the double-PCL sign, may appear. In this report, double PCL sign was seen on MRI which was confirmed during the arthroscopic procedure. It is crucial to recognize this symptom in order to have an appropriate pre-operative diagnosis and a suitable treatment strategy.

**Disclaimer:** None.

**Conflict of interest:** None.

**Funding disclosure:** None.

## References

- Fox AJ, Bedi A, Rodeo SA. The basic science of human knee menisci: structure, composition, and function. *Sports Health* 2012;4:340-51. doi: 10.1177/1941738111429419.
- Arastu MH, Grange S, Twyman R. Prevalence and consequences of delayed diagnosis of anterior cruciate ligament ruptures. *Knee Surg Sports Traumatol Arthrosc* 2015;23:1201-5. doi: 10.1007/s00167-014-2947-z.
- Santoso A, Poetera CY, Marindratama H, Anugrah JY, Anwar IB, Sibarani TSMHS. Both medial and lateral bucket-handle meniscus tears associated with chronic ACL injury: A rare presentation of triple-PCL sign. *Int J Surg Case Rep* 2021;87:106413. doi: 10.1016/j.ijscr.2021.106413.
- Wright J, Tamura C, Findlay I, Daneshfar A. Simultaneous bicompartamental bucket handle meniscal tears with a clinically competent Anterior Cruciate Ligament. *J Orthop Surg Res* 2010;5:68. doi: 10.1186/1749-799X-5-68.
- Weiss KL, Morehouse HT, Levy IM. Sagittal MR images of the knee: a low-signal band parallel to the posterior cruciate ligament caused by a displaced bucket-handle tear. *AJR Am J Roentgenol* 1991;156:117-9. doi: 10.2214/ajr.156.1.1898543.
- Anwar SF, Khan AM, Saif AB, Faraz SS. Functional Outcome Of Arthroscopy Assisted Reconstruction Of Anterior Cruciate Ligament Using Bone-Patellar Tendon-Bone Graft. *Pak Armed Forces Med J* 2019;69:1272-7.
- Cetik O, Cirpar M, Eksioglu F, Uslu M. Simultaneous bucket handle tear of both medial and lateral menisci of a knee with chronic anterior cruciate ligament deficiency. *Knee Surg Sports Traumatol Arthrosc* 2006;14:356-9. doi: 10.1007/s00167-005-0665-2.
- Thein R, Hershkovich O, Gordon B, Burstein G, Tenenbaum S, Derazne E, et al. The Prevalence of Cruciate Ligament and Meniscus Knee Injury in Young Adults and Associations with Gender, Body Mass Index, and Height a Large Cross-Sectional Study. *J Knee Surg* 2017;30:565-70. doi: 10.1055/s-0036-1593620.
- Magee TH, Hinson GW. MRI of meniscal bucket-handle tears. *Skeletal Radiol* 1998;27:495-9. doi: 10.1007/s002560050426.
- Jee WH, McCauley TR, Kim JM, Jun DJ, Lee YJ, Choi BG, et al. Meniscal tear configurations: categorization with MR imaging. *AJR Am J Roentgenol* 2003;180:93-7. doi: 10.2214/ajr.180.1.1800093.
- Thoreux P, Réty F, Nourissat G, Rivière X, Safa P, Durand S, et al. Bucket-handle meniscal lesions: magnetic resonance imaging criteria for reparability. *Arthroscopy* 2006;22:954-61. doi: 10.1016/j.arthro.2006.04.111.
- Biau DJ, Katsahian S, Kartus J, Harilainen A, Feller JA, Sajovic M, et al. Patellar tendon versus hamstring tendon autografts for reconstructing the anterior cruciate ligament: a meta-analysis based on individual patient data. *Am J Sports Med* 2009;37:2470-8. doi: 10.1177/0363546509333006.
- Kakel R, Russell R, VanHeerden P. The triple PCL sign: bucket handle tears of both medial and lateral menisci in a chronically ACL-deficient knee. *Orthopedics* 2010;33:772. doi: 10.3928/01477447-20100826-22.
- Guillaume S, Bodart A, Collart J. The Triple Posterior Cruciate Ligament Sign in Bicompartamental Bucket Handle Meniscal Tear. *J Belg Soc Radiol* 2021;105:28. doi: 10.5334/jbsr.2472.
- Sales E, Gupta S, Daines B, Baker A, Landgrabe M, Zeini IM, et al. Bicompartamental Bucket Handle Meniscal Tear with Chronic ACL Deficiency Causing a Rare Triple PCL and Triple Cruciate Sign: A Case Report. *JBJS Case Connect* 2021;11. doi: 10.2106/JBJS.CC.20.00694.