

## Covid-19 co-infection with Crimean Congo haemorrhagic fever (CCHF) in a CCHF endemic country: a case report

Sadaf Hanif Musani,<sup>1</sup> Muhammad Mehmood Alam,<sup>2</sup> Asad Latif<sup>3</sup>

### Abstract

Covid-19 pandemic affected the health care systems globally. In many countries, healthcare services were overwhelmed by the huge number of Covid cases; hence, shifting the focus from locally endemic infectious diseases. Such a case presented to us that was initially managed along the lines of critical Covid pneumonia with steroids, Remdesivir, and supplemental oxygen for hypoxic respiratory failure. The patient also received Baricitinib, to which he was non-responsive and thus offered invasive mechanical ventilation. Post intubation, the patient was managed for Covid-associated ARDS with lung protective ventilation. He later also developed liver dysfunction, renal failure, coagulation derangements, and shock. Workup for malaria and dengue were negative. Later, Crimean Congo PCR was sent which came positive; a possible cause of progressive deterioration. In CCHF endemic areas, it is crucial to rule out the CCHF infection among patients presenting with critical Covid pneumonia due to similar clinical presentation in both the infections.

**Keywords:** Covid-19, Crimean-Congo, Baricitinib.

**DOI:** 10.47391/JPMA.7996

**Submission completion date:** 21-11-2022

**Acceptance date:** 26-06-2023

### Introduction

Covid-19 pandemic caused global panic, forcing every country to utilise its full potential in fighting this public health threat. Due to this, health systems in many countries lost their focus on locally endemic diseases.<sup>1</sup> Ignoring the other potential viral threats due to Covid pandemic-related stress had serious consequences ranging from missing out the diagnosis of a potential viral-infected patient presenting with overlapping symptoms to an increased risk of outbreaks and mortality

.....  
<sup>1</sup>Department of Internal Medicine, Aga Khan University Hospital, Karachi, Pakistan, <sup>2</sup>Department of Internal Medicine, Indus Hospital Health Network, Karachi, Pakistan, <sup>3</sup>Department of Anaesthesia, Aga Khan University Hospital, Karachi, Pakistan.

**Correspondence:** Muhammad Mehmood Alam.

Email: mehmoodalam.2911@gmail.com

**ORCID ID.** 0000-0001-8182-3217

due to viral agents other than Covid.<sup>2</sup>

It is being emphasised that the differential diagnosis of Covid-19 must include several viral and bacterial diseases.<sup>3</sup> However, every country has different endemic diseases, hence, one should consider other potential diseases in the differential diagnosis while treating critical Covid cases.<sup>4</sup>

Crimean-Congo haemorrhagic fever (CCHF) is one of the priority diseases among endemic viral infections in Pakistan. Sporadic outbreaks of CCHF occur in Pakistan every year during specific periods of time.<sup>5,6</sup> Since the emergence of Covid-19 pandemic it is being observed that similarity of symptoms among the two infections, i.e. CCHF and Covid-19 infection, may result in difficulty in differentiating one from the other. Lack of acknowledgement of this fact may result in missing out the possibility of co-infection even in communities where CCHF is endemic.<sup>4</sup>

### Case Report

A 62-year-old male with no prior co-morbidity was brought to the emergency room of Aga Khan University Hospital, Karachi, on September 14, 2021, with cough, fever, and shortness of breath for 10 days. He was admitted to the special care unit via emergency room with a positive PCR for Covid-19, confirmed on September 15, 2021. He had no known prior co-morbidity and was vaccinated against Covid-19 virus about five months before his illness. Before being admitted to the hospital, the patient was managed at home with high dose Methylprednisolone, antibiotics, Remdesivir, and anticoagulation. Due to deteriorating condition, he was brought to the emergency department with paO<sub>2</sub> of 41.5mm Hg on blood gas and SaO<sub>2</sub> of 82% on room air. The patient was also offered non-invasive mechanical ventilation for hypoxic respiratory failure and respiratory distress. Initially, Bilevel-positive pressure ventilation was applied but due to poor tolerance to it, he was switched to high-flow nasal cannula (HFNC) (flow 40L/min FiO<sub>2</sub> 100%). At the time of hospital admission, the patient was haemodynamically and neurologically stable. Hence, he was managed as critical Covid pneumonia with acute respiratory distress syndrome (ARDS)/hypercoagulable

**Table-1:** Showing deterioration of liver and renal functions during hospital course.

Serum levels	Dates of Assessment												
	ICU Day 1	ICU Day 4	ICU Day 6	ICU Day 8	ICU Day 9	ICU Day 10	ICU Day 11	ICU Day 12	ICU Day 13	ICU Day 14	ICU Day 15	ICU Day 16	ICU Day 17
Total Bilir	0.8	*	*	*	*	1.8	2.0	2.4	3.3	4.8	7.6	8.8	11
ALT	71	*	*	*	*	207	10195	6458	2537	1172	674	404	260
AST	46	*	*	*	*	111	13879	6261	1972	568	250	168	263
Cr	1.2	0.7	0.5	0.6	0.7	3.5	4.8	5	6.6	4.7	4.8	3.5	4.8
BUN	25	30	35	45	44	*	100	135	154	99	85	71	105
K	4.2	4.6	5.1	4.1	4.4	*	4.6	4.4	4.2	3.8	4.1	3.8	6.0
Na	146	141	138	138	135	*	147	148	139	146	142	139	151
HCO3	27.7	28	2705	31.5	24.5	*	25.8	16.1	17.5	24.5	21.6	23	14

Total Bilir = Total Bilirubin, ALT=Alanine Aminotransferase, AST=Aspartate Aminotransferase, K=Potassium, Cr=Creatinine, Blood Urea Nitrogen =BUN, Na= Sodium, HCO3= Bicarbonate. \*Data not available.

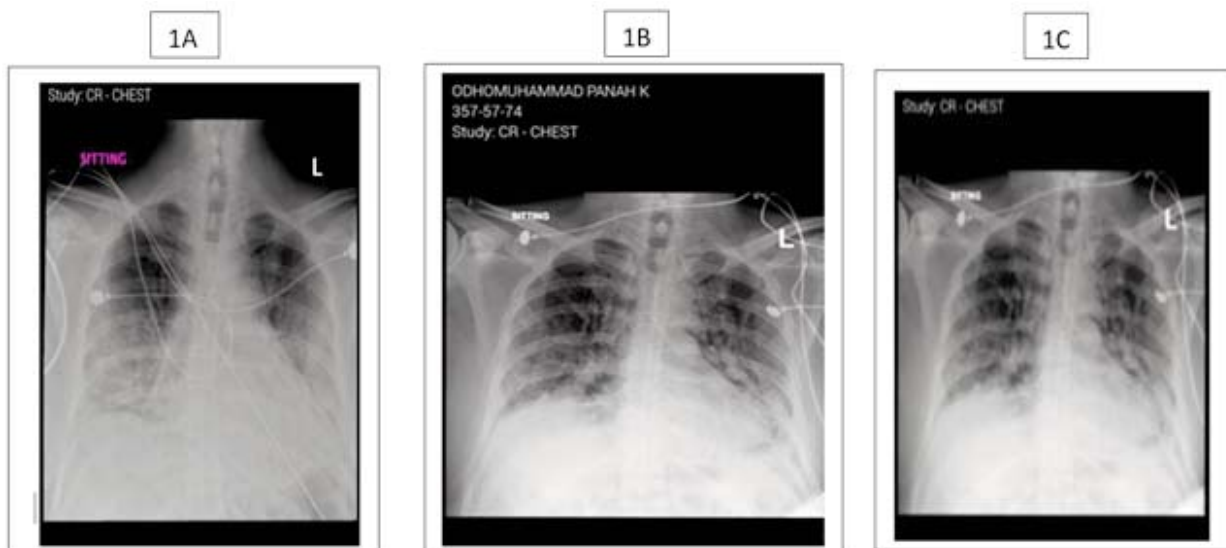
state and was admitted in the special care unit on HFNC (Figure 1A), where he was administered steroids, awake proning, and empiric antibiotics.

His condition remained the same for a few days with Procalcitonin 0.05 (Normal= less than 0.1 ng/mL) and IL-6 of 4.90 (Normal value=0.007 ng/ml or 7 pg/ml) with fluctuating oxygen levels on HFNC; his APACHE score on ICU admission was 31(Normal= 0-71). For the first few days of hospital admission the inflammatory markers showed an improving trend, but then the total leukocyte count escalated again. Furthermore, chest-X-ray showed worsening infiltrates. Echocardiography was reported negative for right ventricular strain to rule out pulmonary embolism as CT-scan of the chest with contrast was not possible due to High Flow Nasal Cannula (HFNC) and respiratory distress. Blood cultures and sputum cultures

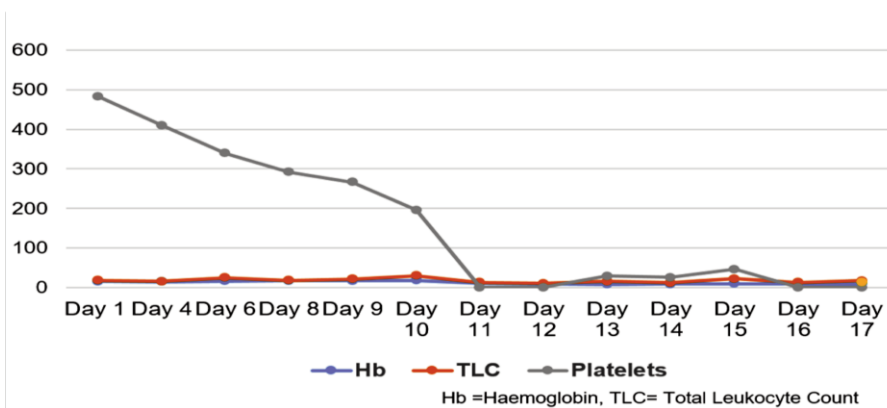
were also negative. Moreover, the patient also developed an episode of chest pain and sinus tachycardia; however, electrocardiogram (ECG) showed sinus tachycardia and troponin-I were significant for non-ST elevation myocardial infarction (NSTEMI) for which the cardiology department was also taken on board, who advised conservative management. (Table 1)

On the 10th day of hospital admission, Baricitinib was started at a dose of 4mg once a day and over the next 12 hours the patient was intubated due to type II respiratory failure with arterial blood gases (ABGs: 7.30/63.80/57.70/30.50/86.3%) and shifted to the ICU. Pre-Intubation X-ray of the chest (CXR) is shown in Figure 1B.

In the ICU, he was managed on the lines of critical Covid (severe ARDS)/septic shock/hypercoagulable state post



**Figure-1:** Showing X-ray chest on findings on hospital admission day 0[1A], admission day 10 (when intubation was done) [1B] and day 16 (one day before the death of the patient) [1C].



**Figure-2:** Showing progressive decline in platelets during hospital course.

intubation. The patient required dual vasopressor support for haemodynamic instability. Antibiotics were also escalated with the suspicion of hospital acquired pneumonia. Blood and tracheal samples were sent for cultures. The workup now showed significant derangement of liver enzymes, for which intravenous N-acetylcysteine infusion was started. On investigation biomarkers for viral hepatitis were negative and ultrasound of the abdomen was unremarkable; however, disseminated intravascular coagulation (DIC) markers were positive with raised fibrin degradation product, low platelets and high d-dimers. Heparin induced thrombocytopenia (HIT) antibody tested negative and, due to coagulation derangements, anticoagulation was held. In addition, serum creatinine level also deteriorated which was suggestive of acute kidney injury.

Due to thrombocytopenia, Haematology department was consulted and they held Baricitinib responsible for thrombocytopenia and deranged Alanine aminotransferase (ALT) and Aspartate aminotransferase (AST). DIC panel continued to be positive with raised d-dimer and Fibrin degradation products (FDP) levels, and thrombocytopenia with decreased fibrinogen levels. Due to worsening renal functions, initially two sessions of haemodialysis were done followed by continuous renal replacement therapy (CRRT). Despite transfusion of blood products (i.e., fresh frozen plasma and platelet concentrates) the coagulation profile remained deranged.

The unexplained progressive deterioration of renal and liver functions along with thrombocytopenia gave rise to suspicion of dengue infection but serology for dengue showed negative results (Figure 2). After negative serology results for dengue, CCHF PCR was also sent which turned out to be positive, despite no specific or relevant history of possible exposure to Congo virus

except history of recent travel to his home village with no specific exposure to husbandry. Later on, during the course of the illness, the patient's Glasgow Coma Scale could not be achieved and neurology input was sought; they advised MRI/CT brain but that could not be done due to haemodynamic instability. Furthermore, cultures for tracheal secretions showed drug resistant *Klebsiella* with intermediate drug sensitivity only to Minocycline. However, the patient could not

recover due to multi-organ failure (Figure 1C).

In this case the worsening of liver enzymes was thought to be secondary to Baricitinib but with progressive coagulopathy the suspicion of viral haemorrhagic fever was raised and out of all the available test for viral haemorrhagic fever were sent, Congo PCR came out to be positive.

## Discussion

This rare and incomprehensible presentation of critical Covid with CCHF in a country like Pakistan is worth reporting for many valid reasons. First, Covid pandemic is one of the biggest global health threats of current times posing new challenges for healthcare workers worldwide. Secondly, over the past few decades CCHF has become an endemic disease in many regions of Pakistan and, in many parts of the country, CCHF outbreaks occur regularly in specific seasons.<sup>5</sup> Third, the expected trend of seasonal outbreak of CCHF in Pakistan has abruptly changed since the Covid-19 pandemic or possibly masked by overlapping clinical presentation of these diseases. Hence, posing an additional challenge to healthcare workers who already lack enough knowledge and resources to manage these life-threatening viral infections.<sup>6, 7</sup> Even the CT findings are similar in Covid-19 patients and CCHF patients, i.e. ground-glass opacities on chest CT. Under recognition of these facts particularly during times of Covid-19 pandemic may result in confusion, lack of timely diagnosis, and high risk of mortality among patients suffering with co-infection of Covid-19 and CCHF virus or only CCHF.<sup>8</sup> Furthermore, the Covid pandemic has increased the risk for outbreaks of other endemic infectious diseases due to their compromised surveillance and exhaustion of resources.<sup>8</sup>

In the above-mentioned case, the patient was already

admitted as a known case of Covid-19 with respiratory distress. However, over the time, during ICU admission the patient developed other systemic clinical complications and eventually developed multi-organ failure. The only significant history was travel to his home village around seven days before hospitalisation which might have exposed him to livestock. However, the overall presentation was more convincing in favour of prior Covid infection superimposed by CCHF due to complaint of cough which started 10 days before hospital admission and positive PCR for Covid-19. The observed improvement in inflammatory markers followed by a new rise in Total Leucocyte Count also support the assumption that the clinical onset of CCHF in the patient started later in the ICU while the patient had already been diagnosed with Covid-19 infection. Moreover, the rise in leucocyte count was seen within 14 days after potential exposure or visit to the village in this particular patient, i.e. after maximum incubation.<sup>9</sup>

The non-specific medical history and non-specific clinical presentation were the major barriers leading to delayed diagnosis of CCHF. Case reports from Turkey and Iran have shown considerable improvement and complete recovery in co-infections of CCHF and Covid if diagnosed early, before multi-organ failure develops.<sup>10</sup> However, in this case the diagnosis of CCHF was delayed until multi-organ failure was already established. Moreover, administration of Baricitinib also raised the suspicion of drug-induced hepatic failure which further delayed the diagnosis of CCHF. Hence, this case highlights the importance of considering CCHF in differential diagnosis of suspected Covid patients, especially in regions where CCHF is an endemic disease.<sup>7</sup>

## Conclusion

This case here emphasizes that CCHF must always be included in the differential diagnosis of all patients suspected of Covid-19. Moreover, in CCHF endemic regions it is crucial to get necessary early and prompt investigations to rule out the possibility of co-infection of Covid and CCHF among all critical Covid-19 cases owing to similar overlapping symptoms. Early diagnosis can prompt early medical intervention in this regard.

**Acknowledgement:** The patient's son was informed, and he signed and gave consent for publication of this case report.

**Disclaimer:** None.

**Conflict of Interest:** None.

**Source of Funding:** None.

## References

1. Mehmood Q, Tahir MJ, Jabbar A, Siddiqi AR, Ullah I. Crimean-Congo hemorrhagic fever outbreak in Turkey amid the coronavirus disease 2019 (COVID-19) pandemic; a debacle for the healthcare system of Turkey. *Infect Control Hosp Epidemiol* 2022;43:1726-7. doi: 10.1017/ice.2021.343.
2. Jain S, Rocha ICN, Maheshwari C, Santos Costa ACD, Tsagkaris C, Aborode AT, et al. S. Chikungunya and COVID-19 in Brazil: The danger of an overlapping crises. *J Med Virol* 2021;93:4090-1. doi: 10.1002/jmv.26952.
3. Bordi L, Nicastrì E, Scorzolini L, Di Caro A, Capobianchi MR, Castilletti C, et al. Differential diagnosis of illness in patients under investigation for the novel coronavirus (SARS-CoV-2), Italy, February 2020. *Euro Surveill* 2020;25:2000170. doi: 10.2807/1560-7917.ES.2020.25.8.2000170.
4. Ozaras R, Dilek A, Sunbul M, Leblebicioglu H. Association between Crimean-Congo hemorrhagic fever (CCHF) and coronavirus disease 2019 (COVID-19): A systematic review. *Infect Control Hosp Epidemiol* 2022;43:1727-8. doi: 10.1017/ice.2021.388.
5. Atif M, Saqib A, Ikram R, Sarwar MR, Scahill S. The reasons why Pakistan might be at high risk of Crimean Congo haemorrhagic fever epidemic; a scoping review of the literature. *Virol J* 2017;14:63. doi: 10.1186/s12985-017-0726-4.
6. Hussain B, Iqbal A, Abubakar M. Crimean-Congo Hemorrhagic Fever (CCHF): An emerging disease in Pakistan. *Veterinary Sciences: Research and Reviews* 2016;2:11-22. DOI: 10.17582/journal.vsr/2016.2.11.22.
7. Naderi HR, Sheybani F, Bojdi A, Khosravi N, Mostafavi I. Fatal nosocomial spread of Crimean-Congo hemorrhagic fever with very short incubation period. *Am J Trop Med Hyg* 2013;88:469-71. doi: 10.4269/ajtmh.2012.12-0337.
8. Ahmed W, Malik MW, Wattoo MM, Nadeem F, Ahmed Chaudhry MS, Afzal MS, et al. Impact of COVID-19 pandemic on surveillance of Crimean-Congo haemorrhagic fever (CCHF) in Pakistan. *Travel Med Infect Dis* 2021;41:102011. doi: 10.1016/j.tmaid.2021.102011.
9. Albayrak A, Alay H, Yilmaz SI. Comorbidity of Crimean-Congo Hemorrhagic Fever and COVID-19. *Rev Soc Bras Med Trop* 2021;54:e0429. doi: 10.1590/0037-8682-0429-2021.
10. Büyüktuna SA, Hasbek M, Öksüz C, Baysal C, Öz M, Elaldı NA, et al. COVID-19 co-infection in a patient with Crimean Congo hemorrhagic fever: a case report. *Mikrobiyoloji bulteni* 2021;55:445-51. Doi: 10.5578/mb.20219813.