

Retrospective Diagnosis of Ca Thyroid on Thyroid Pertechnetate Scan –A part of Routine Post Thyroidectomy Work up For Nontoxic Multi Nodular Goiter

Kahkashan Bashir Mir¹, Ayesha Ammar², Sadaf Batool³, Naseer Ahmad⁴, Adnan Saeed⁵, Mohammad Faheem⁶, Aamna Hassan⁷

¹⁻⁶Atomic Energy Cancer Hospital (AECH)-NORI

⁷Department of Nuclear Medicine, Shaukat Khanum Memorial Cancer Hospital and Research Center, Lahore

Correspondence: Aamna Hassan. e-mail: aamnah@skm.org.pk

ORCID ID. 0000-0003-0026-0729

Abstract

Unsuspected thyroid cancer can be detected in multinodular goiter (MNG) where the risk of malignancy is 7-9%. Fine needle aspiration (FNAC) is performed in case of suspicious findings on ultrasound. With benign FNAC results there is no need for surgery unless the patient has pressure symptoms or cosmetic concerns, but the risk of overlooked malignancy is always present. We present the case of a patient with unexpected detection of papillary thyroid cancer on thyroid scan.

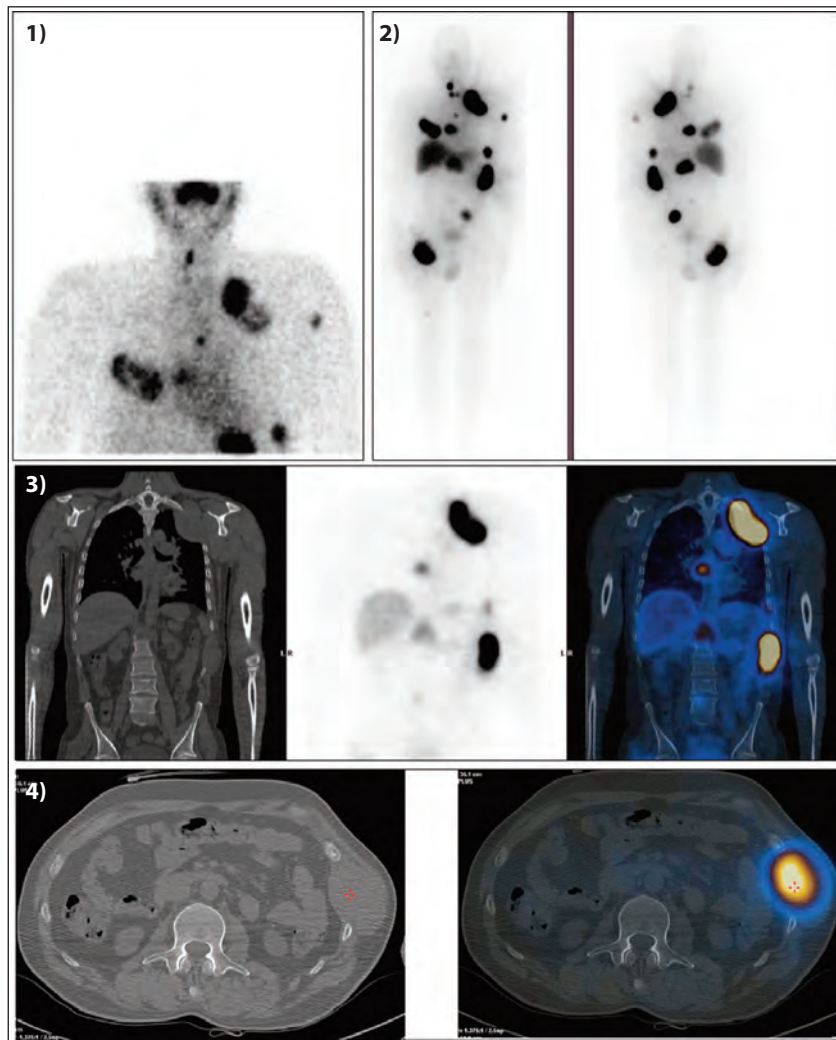


Figure: 1) ^{99m}Tc Pertechnetate, Thyroid scan showing small residual thyroid tissue. A few suspicious, avid areas are noted in visualized field of view (Blue arrows)
2) RAI-131, post ablative scan showing multiple tracer avid areas in neck, abdomen, pelvis and long bones. 3) SPECT CT images showing I-131 avid areas in ribs and spine.
4) SPECT CT images showing increased radiotracer uptake in rib overlying an expansive soft tissue mass.

Keywords: Thyroid Cancer Papillary, Multi-nodular Goitre, Thyroid Neoplasm, Biopsy Fine Needle, Goitre.

DOI: <https://doi.org/>

A 45-year-old male patient presented to our hospital 3 weeks post thyroidectomy. He had a history of progressively increasing multinodular goiter for 13 years. FNAC showed adenomatous colloid nodules, Bethesda category II. Due to pressure symptoms, he underwent total thyroidectomy.

On routine post-op work up, before starting hormone replacement therapy, TSH levels and a Thyroid scan were performed.

Thyroid scan with ^{99m}Tc pertechnetate showed small residual thyroid tissue as shown in Figure 1. Surprisingly, a few areas of increased tracer uptake were noted in the imaged fields. Histopathology review of thyroidectomy specimen showed papillary Ca thyroid.

After complete staging work up, patient was given 200 mci radioactive I-131. Stimulated Thyroglobulin (Tg) level was >2500 ng/ml and AntiThyroglobulin Antibodies (ATG) level was 3129 IU/ml. Post ablative scan after 7 days showed small residual thyroid tissue and functioning thyroid metastases in bilateral ribs (along with soft tissue components), spine, pelvis and right femur as shown in Figure 2, 3, 4). The patient was discharged after 7 days when he was within safe limits.

Multinodular goiter (MNG) is an enlarged thyroid caused by multiple thyroid nodules. The risk of malignancy in MNG is approximately 7-9%.¹ To exclude the diagnosis of thyroid cancer, fine-needle aspiration cytology (FNAC) of most suspicious nodule is performed in routine. Although the sensitivity of ^{99m}Tc -pertechnetate in detecting metastases is low, extra-thyroid ^{99m}Tc pertechnetate on thyroid scan uptake may indicate metastases from Ca Thyroid.^{2,3} Therefore, any suspicious area on ^{99m}Tc pertechnetate thyroid scan should be adequately addressed.

DOI: <https://doi.org/10.47391/JPMA.24-06>

References

1. Mathiopoulou L, Chrisoulidou A, Boudina M, Mitsakis P, Mandanas S, Pazaitou-Panayiotou K. ^{99m}Tc pertechnetate thyroid scan leads to serendipitous detection of metastatic thyroid cancer. *Clin Nucl Med.* 2012;37:604-6.
2. Long B, Yao LF, Chen SC, Shui J, Ye XM, Yi HQ, Lou C. Clinical significance of extra-thyroid ^{99m}Tc -pertechnetate uptake before initial radioiodine therapy for differentiated thyroid carcinoma. *J Int Med Res.* 2021;49:3000605211012667.
3. Bombil I, Bentley A, Kruger D, Luvhengo TE. Incidental cancer in multinodular goitre post thyroidectomy. *S Afr J Surg.* 2014;52:5-9.