

## Intramedullary Subependymoma of Lower Thoracic Cord

Hafiza Hifza Bashir<sup>1</sup>, Hafiza Fatima Aziz<sup>2</sup>, Muhammad Shahzad Shamim<sup>3</sup>

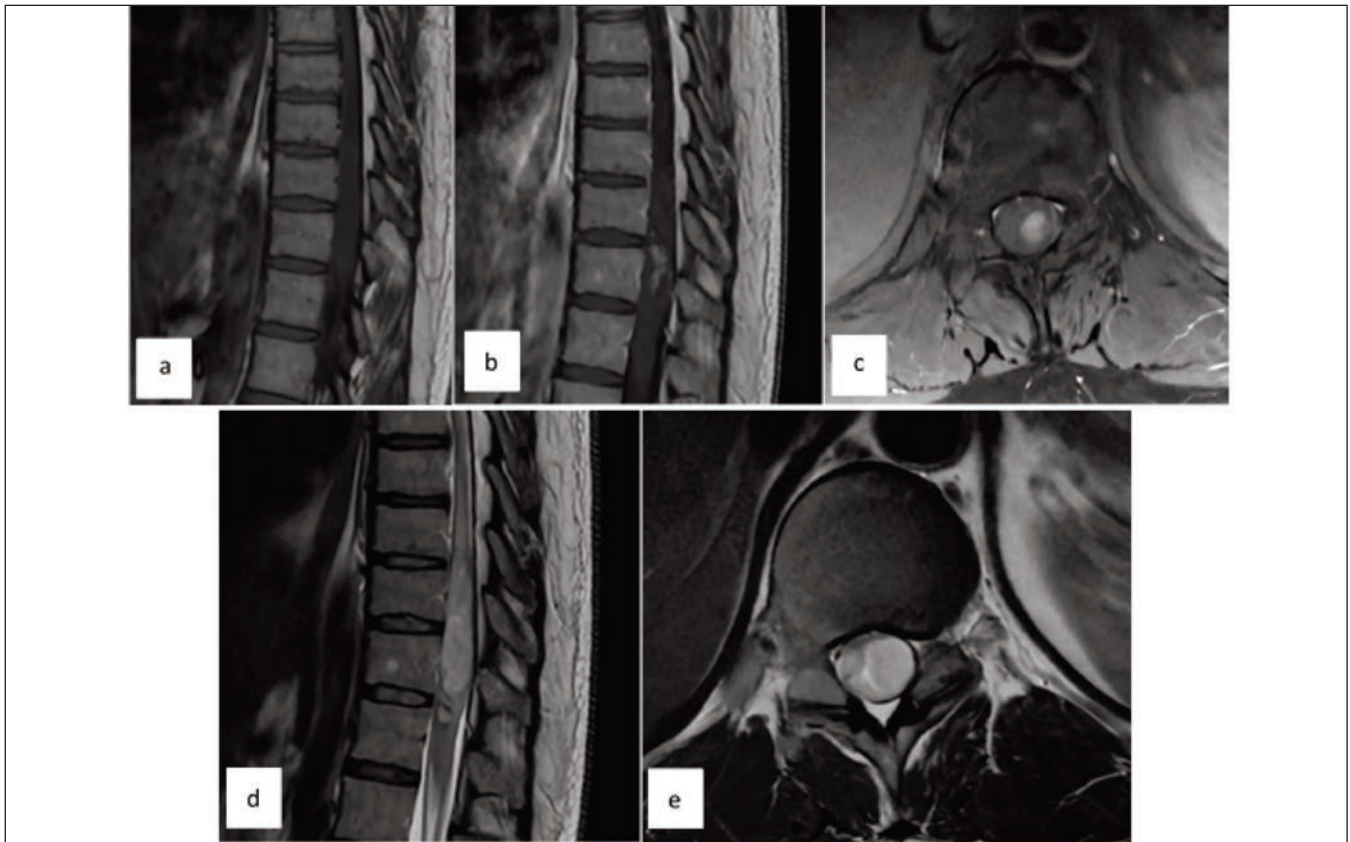
### Abstract

Spinal subependymoma (SSE) is a rare intramedullary, benign tumour. Surgical excision is the preferred approach. However, the interwoven pattern of neural tissue within the tumour dictates the extent of resection. Where gross total resection is linked with possible neurological deficits, subtotal resection or close observation may support better functional outcomes. The evidence for the management of SSE is based mostly on case reports. Herein, we review the existing literature regarding treatment options and clinical outcomes of spinal subependymoma.

DOI: <https://doi.org/10.47391/JPMA.23-66>

### Introduction

Spinal subependymoma (SSE) are rare WHO grade I tumours. Iwasaki et al., reported the prevalence as 2% of all symptomatic cases.<sup>1</sup> Most evidence for SSE comes from case reports and series; therefore, enough epidemiological data is not available to ascertain its incidence. Intracranial location for subependymoma (SE) is common; and only about 17-20% are in spine.<sup>1</sup> SSE are intramedullary tumours with a predilection for cervical and cervicothoracic junction.<sup>2</sup> Like all intramedullary lesions, surgical intervention comes with added morbidity. As a benign pathology that exhibits slow growth and no reported



**Figure a-e:** Biopsy proven subependymoma. Intramedullary expansile lesion, isointense on T1 (a) with subtle post-contrast enhancement (b,c). The lesion is hyperintense on T2 with interwoven isointense areas; The ribbon sign, represent spinal cord tissue (d,e).

<sup>1</sup>Liaquat National Hospital and Medical College, Karachi, Pakistan; <sup>2,3</sup>Section of Neurosurgery, Department of Surgery, Aga Khan University, Karachi, Pakistan.

**Correspondence:** Muhammad Shahzad Shamim.

e-mail: [shahzad.shamim@aku.edu](mailto:shahzad.shamim@aku.edu)

ORCID ID: 0000-0001-8305-8854

malignant conversion, SSE is expected to have long-term survival.<sup>2</sup> In this review, we have summarised the existing literature on surgical management and clinical outcomes of spinal subependymoma.

## Review of Evidence

We searched PubMed and Google Scholar for evidence on the surgical management of spinal SE and its clinical outcomes. After the first case published in 1954 by Boykin et al., till a systematic review in 2019, a total of 105 cases have been published.<sup>3</sup> Presenting age varies widely from 6-77 years with the mean age falling in the fifth decade of life with no gender predilection.<sup>2,4</sup> The majority of SSE occur in cervical and cervicothoracic junction (63-80%), followed by thoracic and lumbar spine.<sup>2,4,5</sup> Clinical manifestations include sensory (80-100%), motor (64-76%) and sphincter and erectile dysfunction (25-38%).<sup>2-6</sup> SSE arise from the central spinal canal as a fusiform eccentric dilation with few reports on extramedullary location.<sup>2,7</sup> Comparable to other common intramedullary tumours, they are iso to hypointense on T1 and hyperintense on T2. Post-gadolinium enhancement varies from no enhancement to patchy or nodular patterns (65 vs 35% with no enhancement) (Figures a-e)<sup>2-6</sup> Hersh et al., identified lines of T2 isointense cord tissue separating regions of T2 hyperintense tumour; which was described as the 'ribbon sign'. (Figures a-e) It was identified in 9/10 SSE (90 %) in their case series. The cord tissue traversing the tumour affect the feasibility of tumour resection and hence post-operative outcome.<sup>8</sup>

Soleiman et al., published a systematic review on 105 patients including a subgroup analysis done for post-operative neurological status in 78 cases on the last follow-up.<sup>2</sup> Forty (51%) patients deteriorated after surgery and the extent of resection was linked with post-op deficits; 72% with gross total resection (GTR) vs. 15% with sub-total resection (STR). Only 14 (18%) patients improved while 24 (30%) had no change in neurological status. Mean follow-up was 14 years, reported in 82 cases. The relative risk for permanent deficits with partial resection was 37% less compared to complete resection ( $p=0.057$ ). Recurrence was reported in 3 cases at 7 years, 9 years, and 12 years. In this review, the total resection rate was 65%, with a high rate of worsening neurological function after surgery (57%).<sup>2</sup>

Wu et al., reported surgical outcomes of 13 patients, GTR was accomplished using a clearly defined dissection plan in 9 (69.2%) cases, however due to extensive adhesions or poor tumour-spinal cord interfaces STR was performed in 4 (30.8%) cases. Seven patients experienced a worsening of their neurological functions after surgery. The average follow-up time was 67.8 months (44-108 months). On telephonic interviews, 11 patients had significantly improved from their pre-operative presentation. Patients were graded as per the McCormick classification and 3 patients were classified as grade Ib, 8 patients as grade II

and 2 as grade III. However at the most recent follow-up, 5 patients were back to grade<sup>1,5</sup> to grade Ib, and 3 to grade II. Follow-up MRI showed no recurrence in 9 GTR patients after 70.3 months, and in 4 STR patients after 62 months.<sup>4</sup>

Yuh et al., retrospectively reviewed 10 patients with SSE. Five patients demonstrated a clearly defined intra-operative plane leading to GTR. However, in 5 cases partial resection was performed owing to ill-defined dissection plane. Two patients had post-operative neurological decline, and only one of them recovered one month following surgery. After STR, two patients received adjuvant radiation; median follow-up was 31.5 months, and none of the patients experienced recurrence. The authors proposed tumour's eccentric location and ill-defined plane as highly suggestive of a diagnosis of subependymoma.<sup>6</sup>

Zhou et al., described 5 cases of SSE. Four of the tumours showed eccentric, well-circumscribed masses, while one lesion had an infiltrating appearance. Due to strong attachment with surrounding structures, STR was achieved in four cases, whereas GTR was only achieved in one. The average follow-up was 57.6 months with no recurrence.<sup>5</sup>

## Conclusion

Spinal subependymoma is a rare, benign tumour. Extent of resection is dependent on finding a good plane around the tumour, although even residual tumours have excellent long term outcomes. Role of radiation therapy is not clearly established.

## References

1. Iwasaki M, Hida K, Aoyama T, Houkin K. Thoracolumbar intramedullary subependymoma with multiple cystic formation: a case report and review. *Eur Spine J* 22(Suppl 3):S317-S320
2. Soleiman HA, Ironside J, Kealey S, Demetriades AK. Spinal subependymoma surgery: do no harm. Little may be more!. *Neurosurg Rev*. 2020;43:1047-53.
3. Boykin FC, Cowen D, Iannucci CA, Wolf A. Subependymal glomerate astrocytomas. *J Neuropathol Exp*. 1954;13:30-49.
4. Wu L, Yang T, Deng X, Yang C, Zhao L, Fang J, Wang G, Yang J, Xu Y. Surgical outcomes in spinal cord subependymomas: an institutional experience. *J Neurooncol*. 2014;116:99-106.
5. Zhou S, Xiong J, Pan J, Zhang T, Geng D, Zhang J. Neuroradiological features of cervical and cervicothoracic intraspinal subependymomas: a study of five cases. *Clinic radiol*. 2016 ;71:499-e9.
6. Yuh WT, Chung CK, Park SH, Kim KJ, Lee SH, Kim KT. Spinal cord subependymoma surgery: a multi-institutional experience. *J Korean Neurosurg Soc*. 2018 1;61:233-42.
7. Matsumura A, Hori A, Spoerri O. Spinal subependymoma presenting as an extramedullary tumor: case report. *Neurosurg*. 1988;23:115-7.
8. Hersh AM, Liu A, Rincon-Torroella J, Sair HI, Lubelski D, Bettogowda C, Shimony N, Lo SF, Sciubba DM, Jallo GI. The ribbon sign as a radiological indicator of intramedullary spinal cord subependymomas. *World Neurosurg*. 2023; 175: e473-e480 .