

Isolated Deep Venous Thrombosis - case series, literature review and long term follow up

Ayeesha K. Kamal, Ahmed Itrat, Sana Shoukat, Asumal Khealani, Kamran Kamal
Department of Neurology, The Aga Khan University Hospital, Karachi.

Abstract

Cerebral Venous Sinus thrombosis may rarely be isolated to a cortical vein or to the deep venous system. When the deep venous system is involved, prognosis is generally poor. In addition, long term follow up is not reported. We conducted a retrospective review of all patients admitted to a major tertiary care center, with the diagnosis of isolated deep venous thrombosis. Two patients were identified with isolated involvement of the deep venous system, they are reviewed in detail with long term follow up. Two young South Asian women in their thirties with rapid onset of neurologic signs and symptoms are reported. Even when one patient required intubation and mechanical ventilation for stupor, both had excellent neurologic recovery. Over 6 years of follow up there has been no recurrence. In spite of stupor at presentation, complete recovery is possible without long term recurrence.

Introduction

Isolated thrombosis of the deep venous system is a rare disease. Since the deep venous system drains mainly the subcortical structures and the diencephalon, deep venous thrombosis often presents with progressive stupor. The rarity of well described cases and the lack of long term prognostic data, may lead to underdiagnosis and a nihilistic therapeutic approach. We add two more cases with long term follow up to the written literature, whose clinical course and long term observation make them unique. In addition, a literature review is performed.

A total of 51 patients with cerebral venous thrombosis were identified. Of these, we describe here the presentation, clinical picture, radiological findings and course of two patients who were found to have deep cerebral venous thrombosis with patent sinuses. All imaging details were independently confirmed by a neuroradiologist (KK). Furthermore, we also performed a literature search on the existing data available on cerebral venous thrombosis.

Case Report

Patient 1: A 35 year old mother of 3 presented with severe headache, neck ache and ataxia on walking, three days prior to admission. Before coming to the E.R she had vomited 2-3 times. She had been using oral contraceptive pills for three

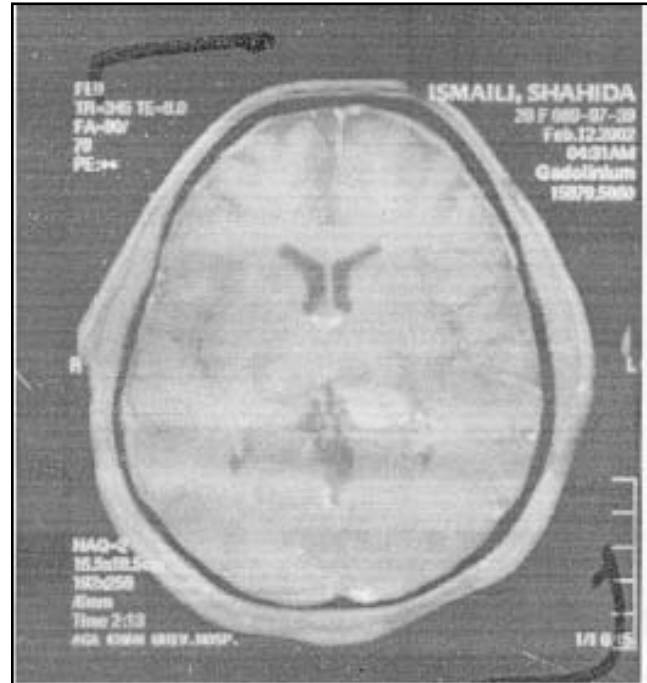


Figure 1. Axial post-gadolinium T1 weighted image shows homogenous enhancement in the thalami bilaterally.

months prior to admission. On neurologic examination, she was found to have a facial paresis with a left pronator drift and ataxia. Deep tendon reflexes were brisk but the plantars were bilaterally downgoing. MRI brain showed a hyperintense area in right basal ganglia and thalamus and a mild mass effect but no enhancement on contrast. It was thought likely to be either a cortical infarct or a glioma. On MRV, the deep cortical veins were found to be absent. She was started on IV heparin. Hypercoagulable workup including ANA, AdsDNA, ASMA, AMA and anticardiolipin A were negative. Thyroid profile and factor V was normal and ESR was 3mm/hour. She was placed on oral anticoagulation for 3-4 months. A follow up MRI showed a hypointense area suggesting volume loss in right thalamus and the infarcted area had resolved. She remains free of neurologic recurrences to date. The follow up period is 6 years.

Patient 2: A 22 year old woman presented with complaint of 2 day history of headaches and blurring of vision. She visited her general physician who recorded a Blood

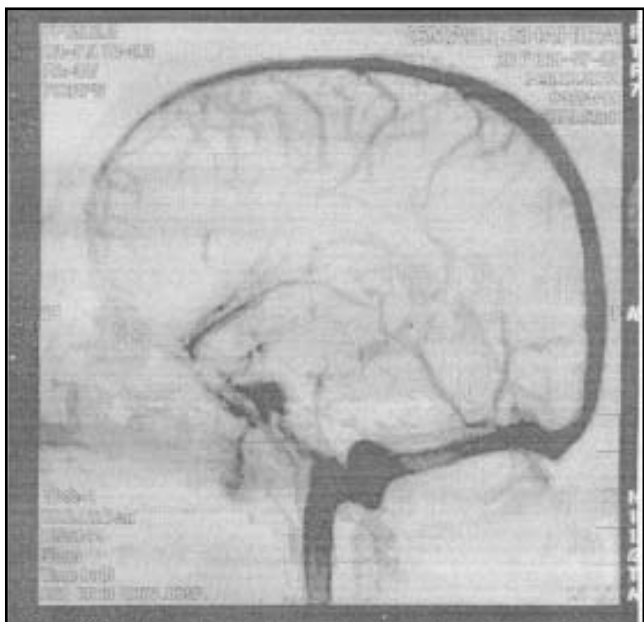

Figure 2. MRV of the intracranial venous structures shows very faint visualization of the internal cerebral veins, the vein of Gallen, the straight sinus and the right transverse sinus.

Pressure of 200/110 and placed her on antihypertensive medications. She rapidly deteriorated on the third day and was brought to the Emergency Room. On examination, she was found to be mute with gradual onset of stupor, bilateral papilloedema, poorly reactive pupils, upgoing plantars. Cerebral Non Contrast CT revealed cerebral oedema with bilateral thalamic edema. EEG showed diffuse theta and delta slowing suggesting generalized neuronal dysfunction. She was intubated because of inability to control airway and progressively depressed mental status. A provisional diagnosis of deep venous thrombosis was made and IV heparin was started on the 4th hospital day. The patient slowly began to regain consciousness after initiation of heparin. She was following commands on the 5th hospital day and was extubated on the 6th. She was placed on warfarin and this was discontinued after a year. She is neurologically intact, except for mild upgaze restriction at 6 years without recurrences.

Discussion

An isolated deep cerebral venous thrombosis would result in severe dysfunction of the diencephalon and may reflect as decreased mental status or even coma. These patients have a cataclysmic clinical course with the symptoms rapidly deteriorating. On the other hand, partial obstruction of deep cerebral veins, or isolated thrombosis of cortical veins would present with varying manifestations. They may stutter or prevent subacutely as the cases that developed Parkinsons or cognitive decline show.¹ The spectrum of clinical symptoms reflects the degree of venous congestion, which depends not only on the extent of thrombosis in the deep veins but also on the territory of the involved vessels and the establishment of venous collaterals.

The presentation of signs and symptoms in patients with deep cerebral venous thrombosis is abrupt as compared to the gradual progression seen when sinuses are involved.²

The risk factors for the development of DCVT are no different from those described for cerebral venous thrombosis with sinus involvement.³ In our cases, patient 1 was using oral contraceptives, a known risk factor, while abnormal coagulation parameters were found in patient 2 though a cause could not be elicited.

The deteriorating signs and symptoms were found in both patients as reported. However, unlike the patients described in other series, there was a remarkable recovery. Patient 1 had worsening headaches and marked ataxia and neurological signs. But by the 5th day, she recovered completely and was discharged. Similarly Patient 2 was intubated because of decreasing mental status and unresponsiveness, but she maintained her ventilation and improved and was extubated within a span of 6 days. This rapid and complete reversal of symptoms in both the patients has not been documented in previous studies. These patients have remained in long term six years of neurologic follow up with no sequelae to date.

The pathophysiology of deep venous thrombosis seems to be similar to that reported in cases of cerebral venous thrombosis. Unlike arterial ischemia, cerebral tissue in venous ischemia may acutely have large areas of vasogenic oedema with the potential for complete reversibility.⁴ At times cytotoxic oedema in venous infarction may be due to concomitant seizure activity. Although we did not have DWI based prognosis, the clinical recovery seems to correlate well with these pathophysiological observations.

The standard of care in cerebral venous thrombosis is unfractionated heparin to prevent clot propagation.⁵ The use of Heparin in our cases proved beneficial as both the patients showed dramatic recovery. In extreme conditions and cases not responsive to iv heparin the use of thrombolytics should be considered, as reports are favorable in those not responding to standard unfractionated heparin.⁶

In summary, based on these observations and those described in case reports, the diagnosis of isolated deep venous thrombosis should be considered in young women, with an acquired or genetic hypercoagulable state, with a lesion in the diencephalons or deep subcortical gray, an MRV may demonstrate the absence of the deep venous system. Despite a cataclysmic course, recovery may be expected and heparin or aggressive intervention should be considered. The risk of recurrence is low.

References

1. van den Bergh, W.M., I. van der Schaaf J. van Gijn, The spectrum of presentations of venous infarction caused by deep cerebral vein thrombosis. *Neurology*, 2005. 65: 192-6.
2. Rafique MZ, Bari V, Ashrat K, Ahmed MN. Cerebral deep venous thrombosis: case report and literature review. *J Pak Med Assoc*, 2005. 55: 399-400.
3. Waddy SP. Disorders of coagulation in stroke. *Semin Neurol*, 2006. 26: 57-64.
4. Wasay M, Azeemuddin M. Neuroimaging of cerebral venous thrombosis. *J Neuroimaging*, 2005. 15: 118-28.
5. Albers GW, Amarenco P, Easton JD, Sacco RL, Teal P, et al., Antithrombotic and thrombolytic therapy for ischemic stroke: the Seventh ACCP Conference on Antithrombotic and Thrombolytic Therapy. *Chest*, 2004. 126(3 Suppl): 483S-512S.
6. Ciccone, A., et al., Thrombolysis for cerebral vein and dural sinus thrombosis. *Cochrane Database Syst Rev*, 2004: p. CD003693.