

## **Computed Tomographic Imaging of Cerebral Venous Thrombosis**

Mohammad Kamran Kamal

Department of Radiology, The Aga Khan University Hospital, Karachi.

### **Abstract**

Cerebral venous thrombosis (CVT) is an entity which is not rare and can have devastating consequences if not diagnosed and treated in a timely manner. Although, the gold standard for diagnosing this entity is a catheter angiogram, magnetic resonance venography, by virtue of its non-invasiveness and detailed demonstration of the cerebral venous structures, has become the diagnostic modality of choice for this entity. However; in a resource-strapped country like Pakistan, CT scan remains the primary first (and sometimes the only) diagnostic modality used in patients with neurological problems. Therefore; it is important to recognize the signs of cerebral venous thrombosis on CT scan in order to initiate timely therapy. These CT findings of CVT are discussed in this paper. The CT findings of CVT have been divided into direct and indirect findings

and the same have been described for noncontrast and post-contrast CT scans separately. A brief discussion of CT venography, which has come around as a promising tool for diagnosing CVT as a result of newer innovations in CT technology, is also included here.

### **Introduction**

Cerebral venous thrombosis (CVT) is an important neurovascular condition that can have devastating consequences for the patient. It can develop secondary to multiple etiologies and can present in varied ways.<sup>1</sup> The various etiologies, manifestations, diagnostic findings, treatment options and outcomes of CVT have been discussed extensively in literature.<sup>2</sup> This paper attempts to focus on the findings seen on computed tomography (CT) in CVT. Though MR imaging is considered by most to be the imaging modality of choice to detect and follow-up CVT, CT

imaging is still important as it is much more readily available than MR, specially in less developed countries, like Pakistan.<sup>3</sup> Also, there are newer techniques emerging in CT due to recent advances in technology that have further refined CT imaging for CVT.<sup>4</sup>

### Computed Tomographic Imaging

As CT is usually the primary imaging modality utilized to evaluate most patients presenting with neurological signs or symptoms, this is usually the initial imaging test that a patient with CVT gets. CT scan findings in CVT were first described by Buonanno and Kingsley in two separate papers in 1978.<sup>5,6</sup> Since then, there have been several other papers describing various CT findings in CVT and the diagnostic value of this modality for CVT.<sup>7-12</sup> The sensitivity and specificity of CT scan in the diagnosis of CVT is 68% and 52%, respectively. It may be totally normal in up to 26% of patients with proven CVT.<sup>13</sup>

CT scanning of the head may be done without or with the administration of intravenous iodinated contrast material. The majority of the CT findings in CVT are appreciated on contrast-enhanced CT scans.<sup>10</sup> Contrast-enhanced scanning helps pick up CVT at an earlier stage and is; therefore, recommended for timely initiation of treatment. In addition to the more conventional axial CT imaging for CVT, CT venography has come up as an effective tool for diagnosing CVT.

The following is a description of the findings of CVT on axial CT imaging followed by a brief discussion of CT venography.

The imaging findings pointing towards a diagnosis of CVT may be divided into direct and indirect findings with the direct findings representing the actual cortical or dural sinus thrombus and the indirect findings representing the adverse effects of the CVT due to venous outflow disturbances.

#### Noncontrast Axial CT Scan - Direct Findings

1. Dense Cord Sign: This represents a thrombosed cortical vein.<sup>14</sup>
2. Dense Dural Sinuses: This represents an acute thrombosis of the dural sinuses.<sup>14</sup> (Figure 1)
3. Dense Jugular Vein: This represents an acute thrombosis of a jugular vein.<sup>14</sup>
4. Dense Triangle or Delta Sign: This represents an acute thrombosis of the posterior superior sagittal sinus.<sup>14</sup> (Figure 2)

In the first two weeks, thrombotic blood is usually hyperdense on an unenhanced CT scan compared to the brain parenchyma; therefore, these signs are usually present during the first two weeks only. After two weeks, a thrombus will become isointense to brain parenchyma and therefore will only be visible on a postcontrast CT.

The specificity and sensitivity of these signs are very low as slow venous flow could appear hyperdense, especially in young patients and people with a high hematocrit level.<sup>8,15</sup>

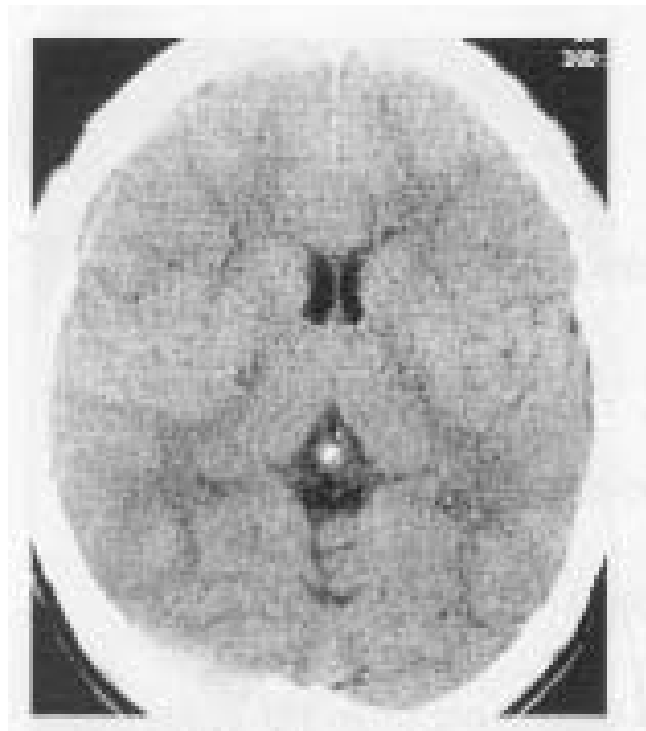


Figure 1. Noncontrast axial head CT scan shows a dense right transverse sinus.

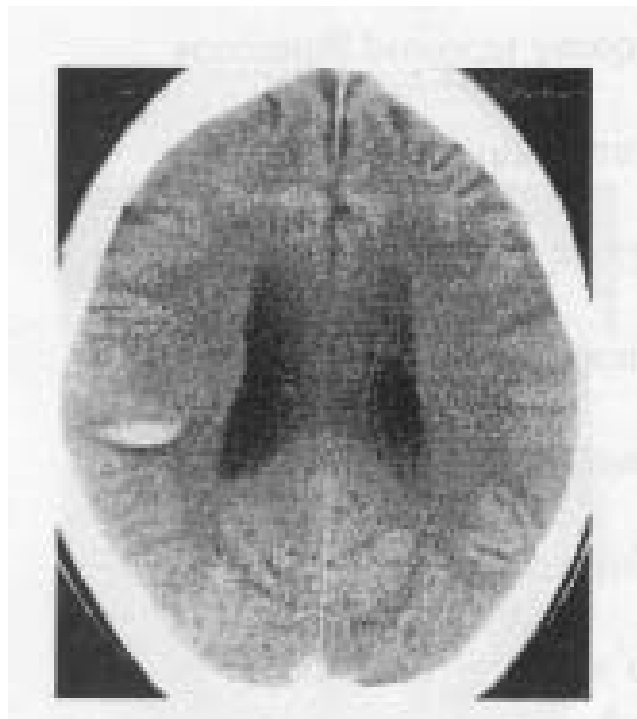

Figure 2. Noncontrast axial head CT scan shows a subcortical hemorrhagic venous infarct in the right parietal region in a patient with a dense triangle or delta sign.

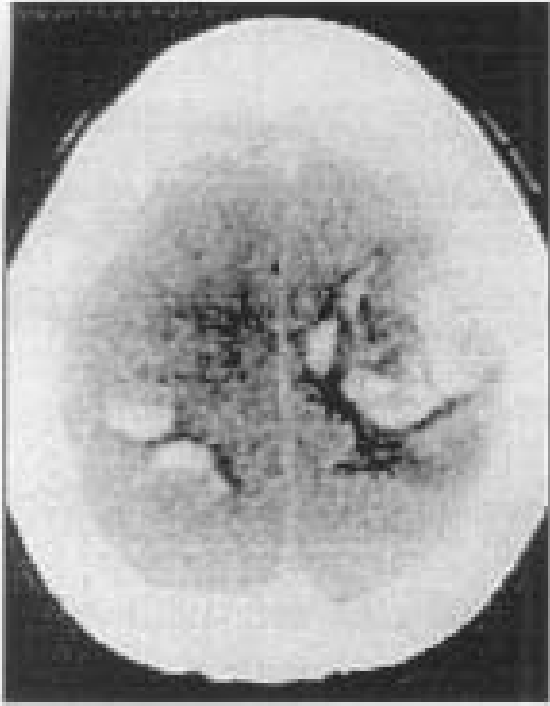


Figure 3. Noncontrast axial head CT scan shows bilateral multifocal hemorrhages.

### Noncontrast Axial CT Scan - Indirect Findings

1. Nonhaemorrhagic Infarcts: This is the most common indirect finding in CVT and can be cortical, subcortical or deep. Multiple infarcts which do not follow any single arterial territory should raise the suspicion of CVT. Bilateral thalamic infarcts are highly suggestive of deep venous system thrombosis.<sup>14</sup> Bilateral parasagittal hypodense lesions on CT are a common finding in venous thrombosis of the superior sagittal sinus.<sup>16</sup>
2. Haemorrhagic Venous Infarcts: Venous backlog leads to infarcts which are often haemorrhagic. These are present in 10% to 50% of cases with CVT.<sup>17,18</sup> (Figure 2).
3. Multifocal Haemorrhages: Multiple areas of haemorrhages are again due to venous backlog and subsequent venous bleeding. These are present in 2% to 10% of cases with CVT.<sup>14</sup> (Figure 3).
4. Subdural/Subarachnoid Haemorrhage: These have been seen in patients with CVT and are presumed to have the same etiology as for parenchymal haemorrhages, described above.<sup>14</sup>
5. Slit-like Ventricles: This is thought to be secondary to pressure effects of venous congestion and may be seen in CVT. They may be a normal finding in young adults.<sup>14</sup> Other etiologies to consider would be

pseudotumor cerebri, diffuse post-traumatic oedema, diffuse inflammation, benign intracranial hyper tension and bilateral isodense subdural collections.

6. Diffuse Cerebral oedema: This may be seen as a diffuse low density of the brain parenchyma and is thought to be secondary to venous congestion.<sup>14</sup>
7. Other Findings: Tertiary findings that may occur due to haemorrhages or infarcts include focal oedema, mass effect, midline shift and hydrocephalus.<sup>19,20</sup>

### Postcontrast Axial CT Scan - Direct Findings

1. Empty Delta Sign: This is the most commonly seen direct finding of CVT on CT imaging and is present in 10% to 30% of cases with CVT.<sup>14</sup> This is a triangular filling defect and represents opacification of collateral veins in the superior sagittal sinus wall with nonopacification of the clot within the sinus. Due to the orientation of the superior sagittal sinus and the usually employed axial plane of imaging it can be seen only in the posterior third of the superior sagittal sinus. A false positive empty delta sign can be produced by fenestration or septa within the superior sagittal sinus.<sup>21</sup> (Figure 4).
2. Nonopacification of or a Filling Defect in a Dural Sinus: Nonopacification of or a filling defect in a dural sinus is suggestive of dural sinus thrombosis.<sup>22</sup> (Figure 4).

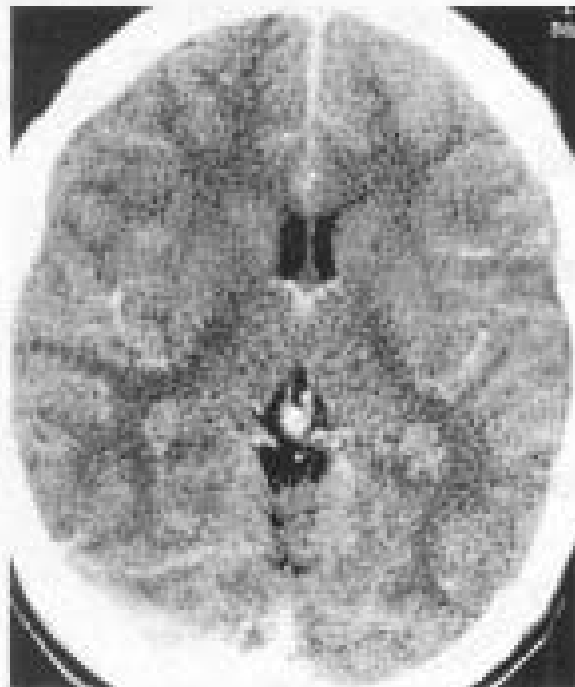


Figure 4. Noncontrast axial head CT scan shows an empty delta sign at the confluence of the superior sagittal sinus and the right transverse sinus.

## Postcontrast Axial CT Scan - Indirect

### Findings

1. Parenchymal Enhancement: This is the most common abnormality on postcontrast axial CT scanning, after the empty delta sign, in a patient with CVT. This most likely represents luxury perfusion an area of infarct. CVT may rarely present as an enhancing space occupying lesion if there is a sufficient amount of edema and mass effect secondary to an infarct.<sup>14</sup>
2. Tentorial Enhancement: This is secondary to venous stasis or hyperaemia of the dura mater.<sup>14</sup>

### CT Venography

CT venography can be used to detect CVT.<sup>23</sup> It is similar to CT angiography except that optimal venous imaging requires a longer delay after the administration of contrast medium than for CT angiography to allow enough time for the contrast material to reach and optimally opacify the venous structures. The data acquired from such axial CT scanning can then be analyzed by itself or reformatted in a number of ways to take additional advantage of new technology. Multiple intensity projection (MIP) images can be derived after removing the overprojecting bones and brain parenchyma and these can be rotated in any plane to perform three dimensional (3D) imaging. This gives far more detail about the cerebral venous structures than obtained by simple axial CT scanning.

CT venography can be performed immediately following a noncontrast CT scan if there is a suspicion of CVT. It is a quicker and cheaper test to perform compared to magnetic resonance venography (MRV) which until now has been considered as the ideal non-invasive test for the diagnosis of CVT. CT venography is superior to MRV in the identification of cerebral veins and dural sinuses and is about equivalent in establishing the diagnosis of CVT.<sup>24</sup> It also has a higher sensitivity for depicting the intracerebral venous circulation as compared with digital subtraction angiography.<sup>25</sup>

Thrombosis is identified as a lack of flow/contrast in a venous structure.

Manual removal of overprojecting bones to get reformatted images can be time consuming and is operator dependent. This problem has been addressed by the recent development of a technique called matched mask bone elimination (MMBE) which automatically gets rid of any

unwanted overprojecting tissues.<sup>4</sup>

### References

1. Canhao P, Ferro JM, Lindgren AG, Bousser MG, Stam J, Barinaqarrementeria F, et al. Causes and predictors of death in cerebral venous thrombosis. *Stroke*. 2005;36:1720-5.
2. Crassard I, Bousser MG. Cerebral venous thrombosis. *J Neuroophthalmol*. 2004;24:156-63.
3. Allroggen H, Abbott RJ. Cerebral venous sinus thrombosis. *Postgrad Med J*. 2000;76:12-5.
4. Majoie CB, van Straten M, Venema HW, den Heeten GJ. Multisection CT venography of the dural sinuses and cerebral veins by using matched mask bone elimination. *AJNR Am J Neuroradiol*. 2004;25:787-91.
5. Buonanno F, Moody DM, Ball MR, Laster DW. Computed cranial tomographic findings in cerebral sinovenous occlusion. *J Comput Assist Tomogr* 1978;2:281-90.
6. Kingsley DPE, Kendall BE, Moseley IF. Superior sagittal sinus thrombosis, an evaluation of the changes demonstrated on computed tomography. *J Neurol Neurosurg Psychiatry* 1978;41:1065-68.
7. Brismar J. Computed tomography in superior sagittal sinus thrombosis. *Acta Radiol* 1980;21:321-26.
8. Eick JJ, Miller KD, Bell KA, Tutton RH. Computed tomography of deep cerebral venous thrombosis in children. *Radiology* 1981;140:399-02.
9. Ford K, Sarwar M. Computed tomography of dural sinus thrombosis. *Am J Neuroradiol* 1981;2:539-543.
10. Rao KC, Knipp HC, Wagner EJ. Computed tomographic findings in cerebral sinus and venous thrombosis. *Radiology* 1981;140:391-98.
11. Chiras J, Bousser MG, Meder JF, Koussa A, Bories J. CT in cerebral thrombophlebitis. *Neuroradiology* 1985;27:145-54.
12. Bousser MG, Chiras J, Bories J, Castaigne P, et al. Cerebral venous thrombosis: a review of 38 cases. *Stroke* 1985;16:199-13.
13. Anxionnat R, Blanchet B, Dormont D, Bracard S, Chiras J, Maillard S, et al. Present status of computerized tomography and angiography in the diagnosis of cerebral thrombophlebitis cavernous sinus thrombosis excluded. *J Neuroradiol*. 1994;21:59-71.
14. Wasay M, Azeemuddin M. Neuroimaging of cerebral venous thrombosis. *J Neuroimaging* 2005;15:118-28.
15. Provenzale JM, Joseph GJ, Barboriak DP. Dural sinus thrombosis: findings on CT and MR imaging and diagnostic pitfalls. *AJR Am J Roentgenol* 1998;170:777-83.
16. Visutaratna P, Oranratanachai K, Likasitwattanukul S. Clinics in diagnostic imaging. *Singapore Med J* 2005;46:238-44
17. Chiras J, Dubs M, Bories J. Venous infarctions. *Neuroradiology* 1985;27:593-600.
18. Deslegte RG, Kaiser MC, Vanderbaan S, Smit L. Computed tomographic diagnosis of septic sinus thrombosis and their complications. *Neuroradiology* 1988;30:160-65.
19. Kim KS, Walezak TS. Computed tomography of deep cerebral venous thrombosis. *J Comput Assist Tomogr* 1986;10:386-90.
20. Goldberg AL, Rosenbaum AE, Wang H, Kim WS, Lewis VL, Hanley PF. Computed tomography of dural sinus thrombosis. *J Comput Assist Tomogr* 1986;10:16-20.
21. Teasdale E. Cerebral venous thrombosis: making the most of imaging. *J R Soc Med* 2000;93:234-37.
22. Schuknecht B, Simmen D, Yuksel C, Valavans A. Tributary venous occlusion and septic cavernous sinus thrombosis: CT and MR findings. *AJNR Am J Neuroradiol* 1998;19:617-26.
23. Casey SO, Alberico RA, Patel M, Jimenez JM, Ozsvath RR, Magviric WM, et al. Cerebral CT venography. *Radiology* 1996;198:163-67.
24. Ozsvath RR, Casey SO, Lustrin ES, Alberico RA, Hassankhani A, Patel A. Cerebral venography: comparison of CT and MR projection venography. *Am J Roentgenol* 1997;169:1699-07.
25. Wetzel SG, Kirsch E, Stock KW, Kolbe M, Kaim A, Raidue EW. Cerebral