

Pre-operative Voriconazole in patients undergoing surgery for Central Nervous System fungal infections: Special Report

Ghani Haider, Muhammad Shahzad Shamim, Muhammad Faheem Khan, Muhammad Ehsan Bari, Syed Ather Enam

Abstract

Fungal infections of the central nervous system (CNS) are uncommon. Despite several advancements in diagnosis and treatment of these infections, the mortality rates remain high. The current retrospective study was planned to define the demographic and clinical features of patients with CNS fungal infections. Conducted at Aga Khan University Hospital, Karachi, and comprising CNS fungal infections operated between January 2000 and December 2015. The study analysed whether a short course of pre-operative anti-fungal therapy may improve outcomes in these patients. There were 47 cases confirmed on histopathology and/or microbiology. Outcome measures used were Glasgow coma score (GCS), Glasgow outcome score (GOS) and Karnofsky performance score (KPS). The overall 30-day mortality was 20(42.5%). Fungal infections of the CNS can occur in both immune-compromised and immune-competent patients. Early diagnosis, radical surgery, pre-operative anti-fungal therapy for at least 2 weeks, pre- and post-operative Voriconazole therapy results in more favourable outcomes.

Keywords: Central nervous system, Fungal infection, Craniotomy, Voriconazole.

Introduction

Fungal infections of the central nervous system (CNS), initially thought to be a disease of immune-compromised patients, are now increasingly reported in immune-competent patients as well.¹⁻⁶ The incidence appears to be on the rise over the last few decades which may be attributed to several factors, including improved diagnostic evaluation, longer life expectancy of general population, increasing prevalence of diabetes mellitus, longer survival of immune-compromised population including transplant recipients, wider use of immunosuppressive drugs and increased number of human immunodeficiency virus (HIV) infected patients,

.....
Section of Neurosurgery, Department of Surgery, Aga Khan University, Karachi, Pakistan.

Correspondence: Muhammad Shahzad Shamim.
Email: shahzad.shamim@aku.edu

etc.^{1-5,7-9} Hot and dry climate with high content of fungal spores in agricultural dust may be responsible for the endemic level of this infection.^{2,3,5}

Patients may present with meningitis, meningio-encephalitis, cerebro-vasculitis, cerebral abscesses or granulomas.^{1-3,8-11} If the disease presents with mass effect, or if there is a doubt about the diagnosis, surgery is usually the next step in management. Surgical goals are optimally safe resection and acquisition of tissue for diagnostic evaluation. Some patients tend to get worse following surgery, with several case series reporting events such as widespread vasospasm, cerebral oedema and acute meningio-encephalitis after surgery.^{2,3,12} This has been postulated to be due to angio-invasiveness of the organism which leads to widespread inflammatory reactions and infarctions, consequently leading to high morbidity and mortality.^{1,13,14} The case-fatality ratio of patients with CNS fungal infections is high, which stands especially true for CNS aspergillosis in which the mortality for certain patient groups is reported to be as high as 100%.^{1,3,8,15-20}

The current study was planned to define the demographic and clinical features of patients with CNS fungal infections and to analyse whether a short course of pre-operative anti-fungal therapy may improve outcomes in these patients.

Methods

The retrospective chart review was conducted at Aga Khan University Hospital, Karachi, and comprised all consecutive cases of CNS fungal infections operated between January 2000 and December 2015. Data of all patients who had surgery and had confirmed CNS fungal infection on the basis of histopathology or microbiology (staining, cultures and sensitivity), were included. Data of patients with unconfirmed diagnosis and those without mass effect (meningitis, thin extradural extension of sino-nasal disease, post-operative fungal infections) were excluded. Patients were categorised as immune-compromised based on the presence of HIV, chronic renal failure, chronic steroid use, diabetes mellitus, malignancy, haematological diseases or

tuberculosis. All other patients were categorised as immune-competent was obtained. Since this was a retrospective chart review, approval from the departmental review committee (DRC). Approval from the ethical review committee (ERC) was exempted. Patient confidentiality was maintained at all stages.

Data was retrieved through patient files using two databases. Our laboratory data for histopathology and microbiology for all patients diagnosed with CNS fungal infection and our medical records office which classifies all cases according to the International Classification of Disease (ICD-9). Patient demographics, relevant clinical history, symptoms on presentation, co-morbidities, immune status, physical examination findings, location and pattern of lesions, radiological imaging and impression, causative organism, pertinent laboratory investigations, management strategies, including both medical management by fungicidal agents and surgical management including details of surgery and outcome, were recorded using a self-designed form. Outcome measures used were mortality, Glasgow coma score (GCS), Glasgow outcome score (GOS) and Karnofsky performance score (KPS). These factors were noted pre-operatively, in the immediate post-operative period, at discharge and at each follow-up visit.

Data was analysed using SPSS v21. Mean and standard deviation were calculated for continuous data. Frequency and percentage were calculated for qualitative data and predictors of mortality were assessed using Chi-square/Fisher's exact test. P-value <0.05 was considered statistically significant.

Results

Of the 47 patients identified, 34(72.3%) were males and 13(27.7%) females. The overall mean age was 36±18 years (range: 13-74 years). Headache was the most common presenting symptom 38(80.9%) patients followed by visual abnormality 19(40.4%) patients. Vomiting, fever, seizures and neurologic weakness were observed in 12(25.5%) patients each. The mean duration of signs and symptoms at the time of presentation was 66.7±86.9 days (range: 2 hours to over a year). Patients with co-morbid conditions numbered 20(42.6%). Hypertension was present in 9(19.1%) patients, diabetes mellitus in 6(12.8%) and chronic steroid use in 8 (17%). Besides, 9(19.1%) patients had history of chemotherapy or immunotherapy while chronic kidney disease was found in 3(6.4%).

All patients underwent pre-operative magnetic resonance imaging (MRI) of brain with and without

Table-1: Frequency of each type of fungus isolated on culture.

Isolated Fungus	Frequency (%)
Aspergillus Flavus	22 (46.8)
Aspergillus Fumigatus	4 (8.5)
Rhizopus	3 (6.4)
Fonsecaea Pedrosi	2 (4.3)
Aspergillus Oryzae	1 (2.1)
Aspergillus Terreus	1 (2.1)
Chaetomium species	1 (2.1)
Rhinocladiella Aquaspersa	1 (2.1)
Madurella	1 (2.1)
Cryptococcus	1 (2.1)
Not isolated	10 (21.3)

contrast. Most commonly involved region was the anterior fossa and frontal lobe in 16 (34%) patients and temporal lobe in 7(14.9%) patients. Posterior cranial fossa(infra-tentorial space) was a rarely involved location. Cerebellar involvement was seen in 3 (6.4%) cases and brainstem was involved in 1 (2.1%) patient only.

A total of 39 (83%) patients were operated as elective cases whereas emergency procedures were carried out in the rest of the patients. Sub-total resection of fungal mass was carried out in 15(31.9%), gross total resection in 5(10.6%), and only a biopsy was performed in the rest. Cerebrospinal fluid (CSF) diversion with external ventricular drain or ventriculo-peritoneal shunt was performed in 3(6.4%) and 2(4.3%) patients respectively. Fungal species were successfully isolated on culture for 37(78.7%) patients (Table-1).

Poly-therapy was employed in 36 (76.6%) patients while mono-therapy was initiated in the rest. All patients received post-operative anti-fungal therapy based on the results of fungal smear, culture, histopathological staining or clinical impression or suspicion of treating physicians (surgeon or infectious diseases specialist), while 18(38.3%) patients had received pre-operative anti-fungal therapy for a mean duration of 18.7±58.9 days. The therapy was continued post-operatively for a mean duration of 175±198 days. Amphotericin B was used in 40(85.1%) patients, Itraconazole in 30 (63.8%) and Voriconazole in 20(42.6%) patients. Patients who received pre-operative anti-fungal therapy had significantly better post-operative KPS compared to those who did not receive pre-operative therapy (p=0.033). More specifically, patients receiving pre-operative anti-fungal for 14 days or more had a significant mortality

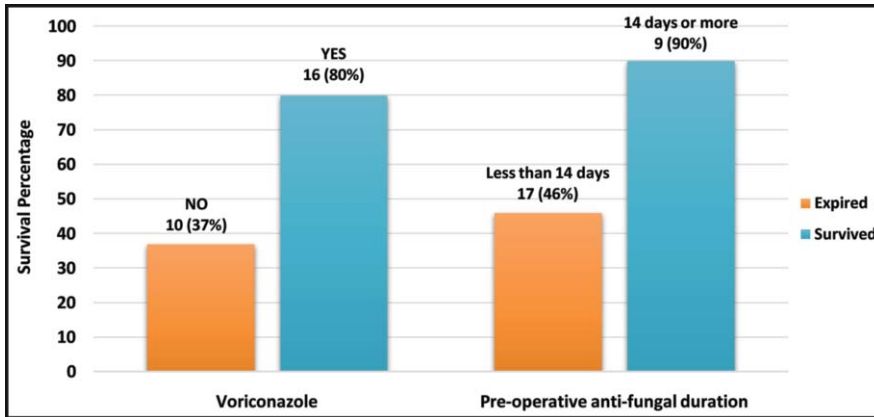


Figure: Association of Voriconazole therapy and treatment duration of pre-operative anti-fungal with survival percentage.

benefit ($p=0.015$) compared to the rest. Other predictors associated with significant mortality benefit and better KPS were Voriconazole therapy ($p=0.007$), American Society of Anesthesiologists (ASA) level 2 or less ($p=0.016$) and absence of post-operative complications ($p=0.014$).

Only 16(34%) patients had an unremarkable post-

Table-2: Association between patient characteristics and mortality.

		Mortality		p-value
		Yes (%)	No (%)	
Prolonged Signs & Symptoms	More than 30 days	10 (50)	10 (50)	0.528
	30 days or less	11 (41)	16 (59)	
Gender	Male	15 (44)	19 (56)	>0.05
	Female	6 (46)	7 (54)	
Hemiparesis	Yes	7 (70)	3 (30)	0.086
	No	14 (38)	23 (62)	
Co-morbid conditions	Yes	11 (55)	9 (45)	0.250
	No	10 (37)	17 (63)	
ASA Level	2 or less	8 (30)	19 (70)	0.016
	3 or more	13 (65)	7 (35)	
Re-operation	Yes	8 (67)	4 (33)	0.100
	No	13 (37)	22 (63)	
Pre-op Anti-fungal duration	Less than 14 days	20 (54)	17 (46)	0.015
	14 or more days	1 (10)	9 (90)	
Anti-fungal poly-therapy	Yes	14 (39)	22 (61)	0.181
	No	7 (64)	4 (36)	
Itraconazole	Yes	12 (40)	18 (60)	0.319
	No	9 (53)	8 (47)	
Voriconazole	Yes	4 (20)	16 (80)	0.007
	No	17 (63)	10 (37)	
Amphotericin-B	Yes	19 (48)	21 (52)	0.436
	No	2 (29)	5 (71)	
Post-op complication	Yes	18 (58)	13 (42)	0.014
	No	3 (19)	13 (81)	

operative course while the rest had some form of complication. A total of 22(46.8%) patients required re-admission due to various reasons such as breakthrough seizures or renal impairment, and 12(25.5%) patients required re-operation. Post-operative neurologic, renal and pulmonary complications occurred in 23(49.9%), 18(38.3%) and 2(4.2%) patients respectively. Mechanical ventilation was required in 5(10.6%) patients. Overall 30-day mortality was 20(42.5%) patients, and reasons included stroke, systemic fungal infection and renal failure secondary to amphotericin B. Mean length of hospital stay was 13.5 ± 10.5 days.

Among the survivors, 19(40.4%) showed improvement or complete recovery from disease at 1-year follow-up. One (2.12%) patient recovered from fungal pathology, but died of some other cause (Table-2).

Discussion

A recent study described the role of radical surgery and post-operative anti-fungal treatment for 6 weeks in improving outcome in these patients.² Most patients in our study were immune-competent, young male patients, similar to the series of Naik, et al.² Moreover, similarity was noted in all the baseline features and demographics recorded in our set of patients with those from various studies reported from South Asian, Middle-Eastern and Sub-Saharan countries.^{1-4,19,21} However, the demographics appear to have a different pattern in reports published from Western countries.^{17,18,22}

Clinical characteristics at presentation included fever, headaches, seizures, hemiparesis, focal neurologic deficit, visual abnormality and cranial nerve deficits. These findings were similar to characteristics reported in existing international literature.^{1-3,6,11,18,23,24} The duration between presentation and beginning of signs and symptoms showed large variations, ranging from a few hours to weeks to even over a year. This is generally not seen in literature. However, it is based on patient recall, and its clinical relevance is doubtful, and any statistically significant association between the clinical duration and any of the outcome measures (mortality, GOS, KPS) was not found ($p>0.05$). Being immuno-compromised has been established as a predisposing factor to fungal infection of CNS.^{1,3,14,16} Most of our patients did not have co-morbidities and were immune-competent. In patients who did have co-morbid conditions, we could not

establish any significant association between having a particular co-morbid condition and pattern of disease or outcome. Understandably, patients who had fixed neurological deficits such as hemiparesis at the time of presentation were more likely to have poor post-operative KPS ($p=0.039$), GOS ($p=0.007$) and higher mortality ($p=0.086$).

Aspergillus was the most commonly isolated causative organism.^{2,3,10} The frequency of Cryptococcus in our series may be lower than expected but that may be explained on the basis that it is more likely to cause meningitis and commonly affects patients with HIV infection, and there was only one patient in our series with HIV.²⁴ Nonetheless, no association between the type of causative fungus and any of the outcome measures, including mortality, was found ($p>0.05$).

Since its approval by the Food and Drug Administration (FDA), Voriconazole has become the drug of choice for fungal infections of the CNS.^{6,14,17,22} Our study further supports this practice. Voriconazole therapy was found to be strongly associated with better survival and KPS ($p<0.014$) (Figure). Our study also supports published literature that whenever feasible, radical surgery offers better outcomes for these patients.^{1-3,6,7,14,16,17,19} Patients who underwent gross or even sub-total resection were found more likely to have better post-operative KPS compared to those who only had biopsy ($p=0.067$). As expected, patients with ASA category 2 or less had lesser overall mortality ($p=0.016$) and patients who required re-operation for any reason were likely to have poor KPS on post-operative follow-up ($p=0.02$).

Some authors have proposed that operating under cover of anti-fungal therapy may offer better outcome.^{2,19,21,23,25} Our study supports this notion as patients who received pre-operative anti-fungal therapy were likely to have better post-operative KPS ($p=0.033$). More specifically, patients receiving pre-operative anti-fungal for at least 14 days had a significant survival benefit ($p=0.015$). However, we did not find a significant difference in outcome between patients receiving anti-fungal mono-therapy and poly-therapy. This may be because of the antagonist effects of amphotericin-B and -azole group.²¹ A total of 40 patients received amphotericin-B, out of whom 18 developed renal complications ($p=0.034$), and 61.1% of those who developed renal complications died because of it ($p=0.074$).¹⁹

Despite advancements, fungal involvement of the CNS remains a management challenge for the

treating physicians. Poor neurologic status at the time of presentation, CSF involvement, decreased immunity, and renal failure are all associated with morbidity and poor outcome.^{2,3,15} In our study, the in-hospital mortality soon after the surgery was high. Out of 20 patients who died, 12(60%) expired during hospital stay or within 2 weeks of surgery.¹⁹ Our overall mortality rate was 42.5% which is similar to the 36.4% reported by Naik et al, and 50% reported by Sharma et al.^{2,9}

The retrospective design of the current study is a limitation. A larger study using more extensive multivariate analysis may be able to reveal more information regarding the management of CNS fungal infections.

Conclusion

Fungal infections of the CNS can occur in both immune-compromised and immune-competent patients and a high index of clinical suspicion is needed to detect these infections. Early diagnosis, radical surgery, pre-operative anti-fungal therapy for at least 2 weeks and Voriconazole pre- and post-operation result in more favourable outcomes.

Disclaimer: None.

Conflict of Interest: None.

Source of Funding: None.

References

1. Nadkarni T, Goel A. Aspergilloma of the brain: an overview. *J Postgrad Med.* 2005; 51:37-41.
2. Naik V, Ahmed FU, Gupta A, Garg A, Sarkar C, Sharma B, et al. Intracranial Fungal Granulomas: A Single Institutional Clinicopathologic Study of 66 Patients and Review of the Literature. *World Neurosurg.* 2015; 83:1166-72.
3. Rajshekhar V. Surgical management of intracranial fungal masses. *Neurol India.* 2007; 55:267-73.
4. Shamim MS, Enam SA, Ali R, Anwar S. Craniocerebral aspergillosis: a review of advances in diagnosis and management. *J Pak Med Assoc.* 2010; 60:573-9.
5. Sundaram C, Murthy JMK. Intracranial aspergillus granuloma. *Pathology research international.* Patholog Res Int. 2011; 2011:157320.
6. Revankar SG, Sutton DA, Rinaldi MG. Primary central nervous system phaeohyphomycosis: a review of 101 cases. *Clin Infect Dis.* 2004; 38: 206-16.
7. Sharma BS, Khosla VK, Kak VK, Banerjee AK, Vasishtha RK, Prasad KM, et al. Intracranial fungal granuloma. *Surg Neurol.* 1997; 47:489-97.
8. Young RF, Gade G, Grinnell V. Surgical treatment for fungal infections in the central nervous system. *J Neurosurg.* 1985;63:371-81.
9. Sharma RR. Fungal infections of the nervous system: current perspective and controversies in management. *Inter J Surg.* 2010; 8:591-601.
10. Panackal AA, Williamson PR. Fungal infections of the central nervous system. *Continuum (Minneapolis).* 2015; 21:1662-78.

11. Haran RP, Chandy MJ. Intracranial aspergillus granuloma. *Br J Neurosurg.* 1993; 7:383-8.
 12. Shamim MS, Siddiqui AA, Enam SA, Shah AA, Jooma R, Anwar S. Craniocerebral aspergillosis in immunocompetent hosts: surgical perspective. *Neurol India.* 2007; 55:274-81.
 13. Sethi PK, Khanna L, Batra A, Anand I, Sethi NK, Torgovnick J, et al. Central nervous system fungal infections: Observations from a large tertiary hospital in northern India. *Clin Neurol Neurosurg.* 2012; 114:1232-7.
 14. McCarthy M, Rosengart A, Schuetz AN, Kontoyiannis DP, Walsh TJ. Mold infections of the central nervous system. *New Eng J Med.* 2014; 371:150-60.
 15. Ellenbogen JR, Waqar M, Cooke RPD, Javadpour M. Management of granulomatous cerebral aspergillosis in immunocompetent adult patients: a review. *Br J Neurosurg.* 2016; 30:280-5.
 16. Giacchino M, Chiapello N, Riva C, Scolfaro C, Pultrone M, Valera M, et al. Intracranial aspergillosis in children successfully treated with antifungal therapy and surgical intervention. *Pediatr Infect Dis J.* 2006; 25:379-81.
 17. Kourkoumpetis TK, Desalermos A, Muhammed M, Mylonakis E. Central nervous system aspergillosis: a series of 14 cases from a general hospital and review of 123 cases from the literature. *Med.* 2012; 91:328-36.
 18. Pongbhaesaj P, Dejthevaporn C, Tunlayadechanont S, Witoonpanich R, Sungkanuparph S, Vibhagool A. Aspergillosis of the central nervous system: a catastrophic opportunistic infection. *Southeast Asian J Trop Med Public Health.* 2004; 35:119-25.
 19. Siddiqui AA, Shah AA, Bashir SH. Craniocerebral aspergillosis of sinonasal origin in immunocompetent patients: clinical spectrum and outcome in 25 cases. *Neurosurg.* 2004; 55:602-13.
 20. Lin S-J, Schranz J, Teutsch SM. Aspergillosis case-fatality rate: systematic review of the literature. *Clin Infect Dis.* 2001; 32:358-66.
 21. Mohindra S, Mukherjee KK, Chhabra R, Gupta SK, Gupta R, Khosla VK. Invasive intracranial aspergillosis: the management dilemmas. *Surg Neurol.* 2008; 69:496-505.
 22. Lyons MK, Blair JE, Leslie KO. Successful treatment with voriconazole of fungal cerebral abscess due to *Cladophialophora bantiana*. *Clin Neurol Neurosurg.* 2005; 107:532-4.
 23. Agarwal R, Kalita J, Marak RSK, Misra UK. Spectrum of fungal infection in a neurology tertiary care center in India. *Neurol Sci.* 2012; 33:1305-10.
 24. Dubey A, Patwardhan RV, Sampth S, Santosh V, Kolluri S, Nanda A. Intracranial fungal granuloma: analysis of 40 patients and review of the literature. *Surg Neurol.* 2005; 63:254-60.
 25. Wasay M, Patel J, Azam I, Khan MA, Smego RA. Preoperative antifungal therapy may improve survival in patients with *Aspergillus* brain abscess. *Clin Neurol Neurosurg.* 2009; 111:565-7.
-