

Pheochromocytoma – An incidental finding in a child with acute appendicitisSyed Maaz Tariq,¹ Amber Tahir Siddiqui,² Syed Ali Haider,³ Mohammad Hasan⁴**Abstract**

Pheochromocytoma, a rare tumour, arises mainly in the adrenal gland. It consists of chromaffin cells or sympathetic para-ganglia if extra-adrenal. It is an occurrence of rare nature with an incidence of two to eight cases per million annually. Incidence of paediatric pheochromocytoma is estimated at 0.11 benign and 0.02 malignant pheochromocytomas per million children. Children with it present with sustained hypertension in contrast to the adult triad of tachycardia, headache, and diaphoresis. We report a case in which the patient initially presented with right iliac fossa pain indicating appendicitis but later when evaluated and assessed, pheochromocytoma was diagnosed as well. The incidental nature of the finding, keeping in mind the rare occurrence makes the outcome interesting and intriguing at the same time.

Keywords: Pheochromocytoma, Appendicitis, Hypertension.

Introduction

Pheochromocytoma is a rare catecholamine secreting tumour which is of chromaffin cells of adrenal medulla (90%) or extra-adrenal sympathetic para-ganglia. The rate of incidence is two to eight cases per million persons annually.¹

The National Registry of Childhood Cancers reports an incidence of 0.11 benign and 0.02 malignant pheochromocytomas per 1 million children. Unlike the adult triad of tachycardia, headache, and diaphoresis, paediatric pheochromocytomas present with sustained hypertension as the primary feature. Larger tumours may cause mass effects such as abdominal pain and distention or back pain.²

Approximately 12% of paediatric pheochromocytomas are malignant. They can be sporadic or inherited as an autosomal dominant trait. Pheochromocytoma may be associated with other syndromes like von Hippel-Lindau

.....
^{1,3,4}Jinnah Sindh Medical University, ²Jinnah Postgraduate Medical Center, Karachi.

Correspondence: Syed Maaz Tariq. Email: maaztariqsyed@gmail.com

(VHL) syndrome (10-20% risk of pheochromocytoma), multiple endocrine neoplasia (MEN) syndrome (>50% risk of pheochromocytoma), neurofibromatosis-1 (1% risk), and familial paraganglioma syndrome (20% risk).²

Case Report

On 7th October, 2017, a 13 year old male child presented in the Emergency Department of Jinnah Postgraduate Medical Center, Karachi with complaint of pain in right iliac fossa associated with fever and vomiting since two days. The pain was sudden in onset, sharp in character, severe enough to hinder everyday activities, relieved by lying down and not radiating to any other body part. Fever was acute in onset, high grade, continuous, and not associated with rigors or chills. There were 4 episodes of vomiting which were not related to food intake, contained only fluid, and were associated with nausea and reduced appetite.

Upon examination at the time of admission, his sensorium was 15/15 on Glasgow Coma Scale, blood pressure was 210/110 mm of Hg in the upper limbs and 220/130 mm of Hg in the lower limbs. Pulse was 123 beats per minute. Modified Alvarado Score was 8. Abdomen was soft, tender at right iliac fossa, guarding and rebound tenderness was positive, and gut sounds were audible. The patient was negative for any other history or examination finding.

Routine investigations including complete blood count, serum electrolytes, liver, renal, lipid, and coagulation profiles, blood glucose levels, blood calcium levels, and urine analysis were carried out. Chest X-ray was unremarkable. ECG showed sinus tachycardia and Echo was unremarkable. Ultrasound abdomen showed acute appendicitis.

CT scan abdomen with IV contrast suggested retrocaecal appendix with signs of early acute appendicitis was also suggested. A large heterogenous lesion was seen, with cystic and necrotic areas within it, in the left suprarenal region. Left adrenal gland was not separately visualized.

CT pyelogram was done which showed a well-defined

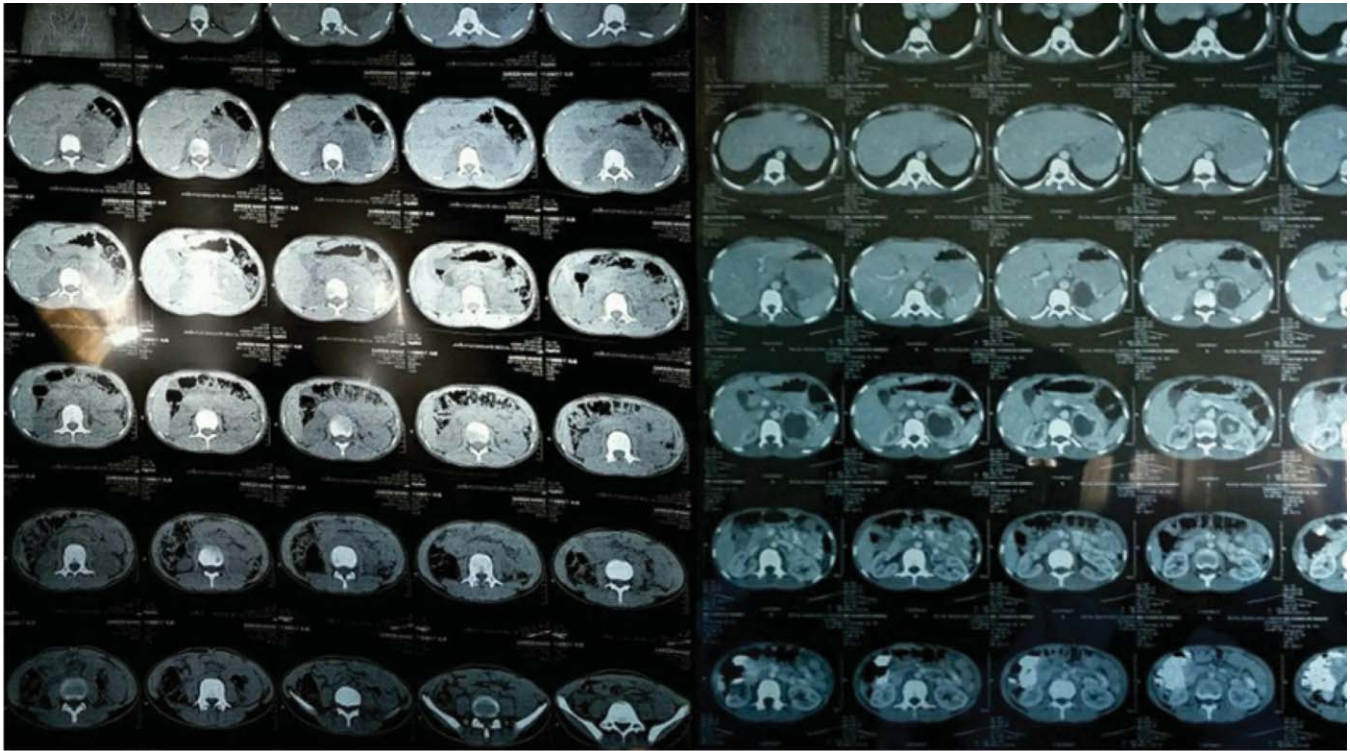


Figure:- CT scan of abdomen showing a mass on left adrenal gland suggesting pheochromocytoma.

lesion, with thick irregular peripheral wall, with slightly thick internal septations, in the left suprarenal region arising from the left adrenal gland. It showed linear as well as popcorn type calcification and measured 6.5 x 5.5 x 6.3 cm (AP x TS x CC). The lesion was abutting the splenic vein and body and head of pancreas. Medially it was abutting the crus of diaphragm. CT scan neck and chest was unremarkable.

Based on the findings of CT abdomen, CT pyelogram, and continuous hypertension pattern noticed in routine in patient's vital monitoring, a diagnosis of pheochromocytoma was made. Keeping in view the initial presenting complaint of the child, it was considered as an incidental finding. 24 hour urinary vanillylmandelic acid (VMA) was 8.10 mg/24hr (normal <3.9 mg/24hr)³.

Initially, the patient was managed conservatively for appendicitis with IV antibiotics. Hypertension was managed with atenolol 100mg daily and terazosin 2mg daily. In the opinion of the attending surgeon, the benefits of the surgical procedure outweighed its risks in this hemodynamically unstable patient, hence elective surgery was done only after optimizing the blood pressure. Appendectomy and left sided

adrenalectomy was done on 6th post admission day. A 8x8 cm mass was excised involving the entire left adrenal gland; solid and cystic with adhesions over pancreas, spleen, and kidney hilum. Histopathology confirmed the clinical and radiological diagnosis. Histopathological report confirmed the mass to be benign. Post-operative recovery was uneventful and the patient was discharged on 10th post op day. The patient has been normotensive since then. A written consent was taken from the patient's family before writing of this manuscript.

Discussion

Our case suggests a benign, intra-adrenal pheochromocytoma as an incidental finding in a hypertensive teenage boy who presented with acute appendicitis. The diagnosis was confirmed on biochemical assay as well as imaging.

To the best of our knowledge, there are only two cases reported in literature where pheochromocytoma was an incidental finding,^{4,5}. In the former the surgery for appendicitis was postponed due to the suspicion whereas in the latter case, it was diagnosed in the autopsy as the patient died due to heart failure after inducing anaesthesia for hysterectomy. Paediatric

pheochromocytoma has only been reported twice in local literature; one presented with hypertensive encephalopathy and other with intracranial bleed, the former being the only case to be reported from a national setting.^{6,7}

Pheochromocytoma is a rare adreno-medullary catecholamine-secreting tumour among children and adolescents. The peak age of incidence is 9 to 12 years with a 2:1 ratio of boys to girls. In children, these tumours are more frequently multiple, bilateral, and extra-adrenal.⁸ Malignancy is more common in extra-adrenal pheochromocytomas (40%) than in intra-adrenal (10%). In children of age less than 10 years, 70% of pheochromocytomas are associated with germline mutation, which decreases to 60% by age 18 years. Altered apoptosis of sympathetic neuronal cell precursor in familial genetic syndromes predisposes to the development of pheochromocytomas.²

Common clinical findings include sustained with paroxysmal hypertension, retinopathy, classic adult triad, history of hypertensive crisis, and seizures⁹. Diagnosis of pheochromocytoma is based on biochemical profile and imaging. Biochemical assay includes elevated plasma fractionated metanephrines or elevated 24-h urinary fractionated metanephrines¹⁰. Our case reported elevated 24-h urinary VMA. Although, the literature limits its use due to a poor sensitivity of 76%, 24-h urinary VMA has a specificity of 96 % for pheochromocytoma¹¹. The sensitivity of urinary catecholamine supplemented with nuclear scanning with ¹³¹ metaiodobenzylguanidine (MIBG) 95.3%¹². Although MIBG is a superior imaging modality as compared to US and CT scan as it allows whole body screening for extra adrenal tumours and metastasis, it has its limitations including high cost, lack of availability, excessive time consumption and provision of insufficient information for surgery. Hence, CT remains primary imaging modality for intra-adrenal tumours and MRI forms primary imaging modality for extra-adrenal tumours¹¹.

Surgery forms the mainstay of treatment. Long term follow-up is essential as functional tissue might manifest at other sites after many years of initial presentation¹³. This is only one of the very few cases reported overall and first from Pakistan where the patient presented with appendicitis and an undiagnosed pheochromocytoma which manifested as hypertension. Scenarios like these are a dilemma where despite a high Alvarado score, the surgery was delayed due to unexplained hypertension. If operated with undiagnosed pheochromocytoma, haemodynamic crisis may have resulted in drastic consequences including patient's death as reported in

literature⁵.

Pheochromocytoma still remains to be a diagnosis that is frequently overlooked¹⁴. Undiagnosed pheochromocytoma is a serious issue, especially when a patient presents in emergency with a different problem as in our case like appendicitis which requires prompt surgical treatment and our report serves as a reminder to this dreadful problem.

Conclusion

Pheochromocytoma is a rare finding. We report a case of incidentaloma in a child who presented initially with symptoms of appendicitis. The incidental nature of pheochromocytoma in our case and this combined with the rare occurrence raises the importance of properly investigating and explaining every symptom before reaching to the final diagnosis in patients with sustained hypertension. CT scan and 24-h urinary VMA test is employed in investigation but it is now gradually being replaced by MIBG scan. Resource deficient settings do not have the facility of MIBG scan. Lack of sufficient number of reports of cases like this in the literature makes our report an important contribution from educational point of view.

Disclaimer: None to declare.

Conflict of Interest: None to declare.

Financial Support: None to declare.

References

1. Mitsis A, Hadjilouka C, Skarpari M, Myrianthefs M. An unusual case of pheochromocytoma mimicking both acute coronary syndrome and central nervous system infection. Case report and literature review. *Hellenic J Cardiol* 2017; 58: 372-7
2. Edmonds S, Fein DM, Gurtman A. Pheochromocytoma. *Pediatr Rev* 2011; 32: 308-10.
3. VMA (Vanillylmandelic Acid), 24-Hour Urine with Creatinine [39517X]: Quest Diagnostics. [Online] [Cited 2018 Jan 20]. Available from: URL: <http://www.questdiagnostics.com/testcenter/BUOrderInfo.action?tc=14555&labCode=AMD>
4. Tarant NS, Dacanay RG, Mecklenburg BW, Birmingham SD, Lujan E, Green R. Acute appendicitis in a patient with undiagnosed pheochromocytoma. *Anesth Analg* 2006; 102: 642-3.
5. Dabbous A, Siddik-Sayyid S, Baraka A. Catastrophic hemodynamic changes in a patient with undiagnosed pheochromocytoma undergoing abdominal hysterectomy. *Anesth Analg* 2007; 104: 223-4.
6. Aftab S, Yasmeen T, Hamid MH, Sarwar M, Sipra H, Qureshi A, et al. Pheochromocytoma: a rare cause of childhood hypertensive encephalopathy. *J Coll Physicians Surg Pak* 2012; 22: 536-8.
7. Sun P, Guan X, Li W, Li P, Li S, Zhang P. Anaesthetic management for pheochromocytoma resection in a 5-year-old boy with cerebral haemorrhage and intestinal obstruction. *J Pak Med Assoc* 2017; 67: 1933-5.
8. Ross JH. Pheochromocytoma: special considerations in children. *Urol Clin* 2000; 27: 393-402

9. Mishra A, Mehrotra PK, Agarwal G, Agarwal A, Mishra SK. Paediatric and adolescent pheochromocytoma: clinical presentation and outcome of surgery. *Indian Pediatr* 2014; 51: 299-302
 10. McHenry CR. Pheochromocytoma: A clinical enigma. *AACE Clin Case Rep* 2017; 3: e180-e1.
 11. Mahmoud HG, Salama M, Fathy H, Talaat O. Presentation, Imaging, Surgical Management and Outcome of Pheochromocytoma: NCI experience. *J Am Sci* 2017; 13: 31-5
 12. Guller U, Turek J, Eubanks S, DeLong ER, Oertli D, Feldman JM. Detecting pheochromocytoma: defining the most sensitive test. *Ann Surg* 2006; 243: 102-7.
-