

### Spigelian Hernia: a rarity

Kamran Ahmad Malik, Pradeep Chopra

Department of General Surgery, Sultan Qaboos University Hospital, Muscat, Oman.

#### Abstract

Spigelian hernias are rare and generally difficult to diagnose because of their location and vague non-specific symptoms. They are situated between the muscular layers of the abdominal wall and can be easily overlooked because of abdominal obesity. The diagnosis has been considerably aided by the introduction of ultrasonography and computed tomography (CT). These hernias require surgical treatment. We report a 31 years old patient from the Sultan Qaboos University Hospital who presented with colicky lower abdominal pain associated with a tender swelling above and lateral to the inguinal canal. A diagnosis of Spigelian hernia was made and confirmed on exploration. The hernia was reduced and the defect repaired. Her recovery was uneventful.

#### Introduction

Spigelian hernia is a protrusion of preperitoneal fat, a sac of peritoneum or an organ, through a congenital defect or weakness in the Spigelian fascia. It is essential to recapitulate the anatomy of the anterior abdominal wall to properly understand Spigelian hernia. Adriaan Van der Spieghel was first to describe the semilunar line and hence the hernia got its name. Henry-Francis Le Dran described spontaneous rupture along the semilunar line in 1742, but Josef T.K. Linkosch was first to refer this condition as a hernia in 1764.<sup>1</sup>

Spigelian hernias are rare accounting for 1-2% of all hernias, with a slightly higher incidence in the female sex. Spigelian line marks the transition from muscle to aponeurosis in the transverses abdominis muscle of the abdomen. It is a lateral convex line between the costal arch and the pubic tubercle. The part of the aponeurosis that lies between the semilunar line and lateral border of the rectus muscle is called the spigelian fascia or zone. Anteriorly throughout its length, the semilunar line is reinforced by the aponeurosis of the external oblique. Posteriorly in the cephalad two thirds it is reinforced by the transversus abdominis muscle which is muscular almost to the midline in the upper abdomen. This support prevents herniation and hence very rare above the umbilicus.

Spigelian hernia is defined as a protrusion of preperitoneal fat, a sac of peritoneum or an organ, through

a congenital defect or weakness in the spigelian fascia.<sup>1</sup> It is usually located between the different muscle layers of the abdominal wall; therefore it is also called as interparietal, interstitial, intermuscular, intramuscular or intra-mural hernia. The majority of spigelian hernias are found in a transverse band lying 0-6 cms cranial to a line running between both anterior superior iliac spines referred to as the spigelian hernia belt where the spigelian fascia is the widest.<sup>2</sup> Hernias that penetrate the spigelian fascia within the Hasselbach's triangle (bounded by rectus abdominis muscle medially, inferior epigastric artery laterally and by inguinal ligament inferiorly) caudal and medial to the inferior epigastric vessels are called low spigelian hernias. Most spigelian hernias occur below the level of the umbilicus close to the level of the arcuate line (inferior margin of posterior leaflet of rectus sheath within the abdomen), though they have being reported to occur above the level of the umbilicus. Incisional hernias through the spigelian fascia or line conventionally are not considered as spigelian hernia, though some authors have described them as spigelian hernia.<sup>3</sup>

We report this rare variety of hernia, found in one of our patients, with review of literature to discuss the diagnosis and management, as such kind of hernias are clinically elusive with fatal outcome if ignored.

#### Case Report

A 31 years old lady presented with 5 hours history of colicky abdominal pain associated with nausea and a palpable lump at the right lower quadrant of the abdomen. She denied any disturbances in her bowel habits. She had similar complaints 3 months back, which resolved spontaneously and she was thoroughly investigated then. Abdominal ultrasonography, barium studies for both upper and lower gastrointestinal systems were all normal at that time. This time on examination a 6 x 4 cms well delineated swelling above and lateral to the right inguinal canal was palpable. It was sub-cutaneous, firm, tender and irreducible with absent cough impulse.

Clinical impression of an irreducible Spigelian hernia with high index of suspicion of strangulation was made on the basis of her past history of similar complaint, which was reduced on conservative treatment at that time, and the peculiar location of the lump. Her routine

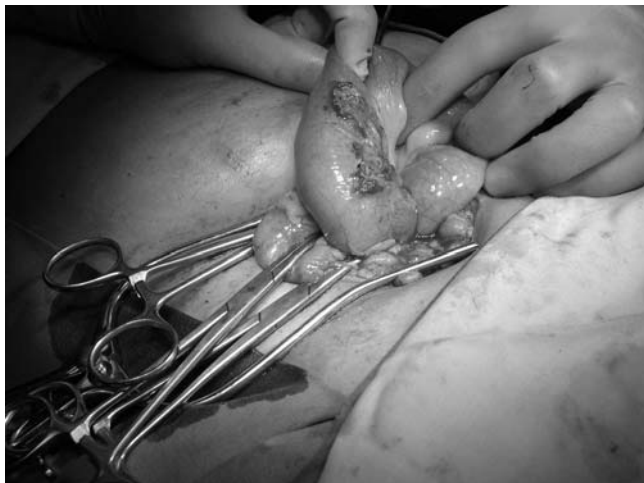

Figure 1.

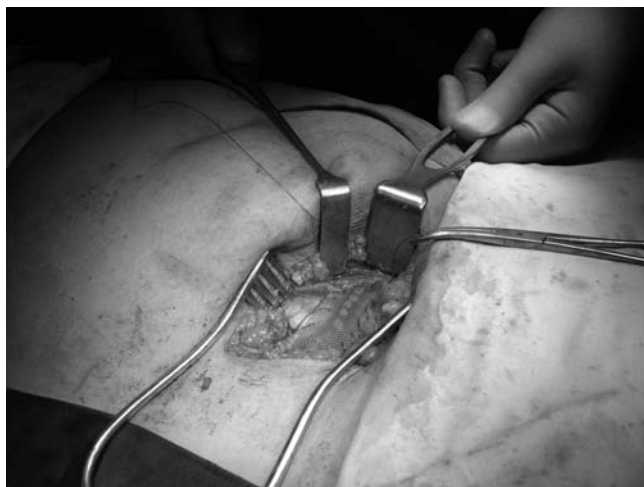


Figure 2.

investigations were within normal range. X-ray abdomen did not show any air-fluid levels to suggest intestinal obstruction.

After adequate preparation she was explored, as we were suspecting strangulation of the gut, under general anaesthesia by an oblique incision over the swelling and was found to have herniation of small bowel (Figure 1), which was viable and healthy, through a defect along the lateral border of rectus sheath. Defect was about an inch, which was repaired with prolene 2/0 suture, and wall was strengthened by applying prolene mesh (Figure 2). Post operatively the patient had an uneventful recovery. She remained well when seen in the Surgical Outpatient 4 weeks after her surgery. Her follow up in our Surgical Outpatient Department about 10 months after surgery was unremarkable.

### Discussion

Spigelian hernia is a rare ventral hernia. Clinical

examination is the mainstay of diagnosis. In its earliest form it is simply a protrusion of preperitoneal fat through the Spigelian aponeurosis. The hernia can also be part of an extra peritoneal organ, but a peritoneal sac is found in most cases. If the peritoneal sac has content, it is usually greater omentum, small intestine, or part of the colon. Spigelian hernias are rarely known to contain an acutely inflamed appendix, Crohn's appendicitis, even an incarcerated Meckel's Diverticulum.<sup>4</sup> Bilateral Spigelian hernias are rare. Richter type of Spigelian hernia has also been reported. Such type of hernias have also being reported following laparoscopic procedure, through a pre-existing fascial weakness, that became manifested as a result of the pneumoperitonem.<sup>5</sup> The symptoms that cause a patient to consult a physician are usually abdominal pain, a mass in the anterior abdominal wall or signs of incarceration with or with out intestinal obstruction. The pain varies in type, severity and location depending on the content of the hernia. Pain can often be provoked or aggravated by maneuvers that increase intraabdominal pressure and is relieved by rest. If the hernia produces a palpable mass along the spigelian aponeurosis the diagnosis is generally easy to make provided the possibility of this hernia is considered. Patients, who do have pain, but have no visible or palpable mass present the greatest difficulty in diagnosis. This condition exists when the hernial sac content is reduced at the time of examination or when a small interparietal hernia cannot be detected on palpation. Physical examination should be carried out while the patient alternately tenses and relaxes the abdominal muscles. When the abdominal muscles are tensed all patients with spigelian hernias have a tender spot over the hernial orifice in the spigelian aponeurosis. On palpation the hernia is pressed against the ring which is firm when the intra-abdominal pressure is raised. This finding is not pathognomonic of spigelian hernia but offers a useful method for screening. Plain abdominal x-rays are not particularly sensitive in diagnosing spigelian hernias.

This hernia is uncommon and clinical diagnosis can be difficult. The appearance of the lesion is comparable with others in and around the abdominal wall, including rectus sheath hematoma, seroma, parietal abscess, lipoma, peritoneal tumor implants and pseudocyst at the end of the ventriculoperitoneal shunts. Clinical and sonographic differentiation is emphasized. Ultrasonic scanning is now a valuable diagnostic tool in both palpable and non palpable spigelian hernias. It is rapid, accurate, non invasive and easy to perform. A CT scan is only required if there is a doubt in making the diagnosis. A Spigelian hernia may be confused with a lipoma or a parietal abscess.<sup>6</sup>

Spigelian hernia should be treated by surgical repair

because of the risk of strangulation.<sup>7</sup> Spangen recommended simple closure of the defect in the form of hernioraphy.<sup>1</sup> Nozoe ET al<sup>8</sup> performed a simple hernioplasty by suturing the internal oblique and transversus muscles to the rectus sheath. Development of mesh and concept of tension free application to other hernias by Liechtenstein led to its use by many for spigelian hernias. Tension free fascia lata graft or mesh repair is also employed for the repair of spigelian hernias.<sup>2</sup> The advent of laparoscopy has made these conventional approaches old-fashioned in experienced hands.<sup>9</sup> Spigelian hernias are ideally suited to preperitoneal laparoscopic repair because the defect in the Spigelian aponeurosis is more clearly identified in the preperitoneal plane. The best results are offered by the extra peritoneal laparoscopic approach.<sup>10</sup>

Spigelian hernias are clinically elusive often until strangulation occurs. Ultrasound examination of the semi lunar line is simple and accurate method of diagnosis. Surgery should always be advised. Apart from the discomfort these hernias cause, they strangulate frequently and hence should be repaired.

## References

1. Spangen L. Spigelian hernia, *Surg Clin North Am* 1984; 64:351-66.
  2. Ray NK, Sreeramulu PN, Krishnaprasad K. Spigelian hernia: Fascia lata repair is an alternative option in absence of prolene mesh. *JIMA-June 2002*, 100:370-1.
  3. Rehman JM, Seow CS, O'Dwyer PJA. A case of a spigelian hernia at an unusually high anatomical location. *R Coll Surg Edin* 2000; 45:196-7.
  4. Lin PH, Kofforon AJ, Heilizer TJ, Lujan HJ. Right lower quadrant abdominal pain due to appendicitis and an incarcerated Spigelian hernia. *Am Surg* 2000; 66:725-7.
  5. Slakey DR, Teplitsky S, Cheng SS. Incarcerated Spigelian hernia following laparoscopic living-donor nephrectomy. *JSLs* 2002; 6:217-19.
  6. Raveenthiran V, Pichumani S. Richter's hernia in spigelian hernia. *Indian J Gastroenterol* 2000; 19:36-7.
  7. Vos DI, Scheltinga MR. Incidence and outcome of surgical repair of Spigelian hernia. *Br J Surg* 2004; 91:640-4.
  8. Nozoe T, Funahashi S, Kipamura M, Ishikawa H, Suehiro T, Iso Y, et al. Ileus with incarceration of spigelian hernia. *Hepatogastroenterology* 1999; 46:1010-2.
  9. Gedebo TM, Neubauer W. Laparoscopic repair of bilateral spigelian and inguinal hernias. *Surg End* 1998; 12:1424-5.
  10. Moreno-Egea, Flores B, Girela E, Martin JG, Aguayo JL, Canteras M. Spigelian hernia: bibliographical study and presentation of a series of 28 patients. *Hernia* 2002; 6:167-70.
-