

Spinal cord injury without radiographic abnormality (SCIWORA) in adults: A report of two cases

Adil Aziz Khan,¹ Shafaq Mahmood,² Tayyaba Saif,³ Aleesha Gul⁴

Abstract

Spinal cord injury without any radiographic abnormality (SCIWORA) is rare in adults. We describe here two case reports of adult patients, who presented to us with quadriplegia, following a road traffic accident. Plain radiography and computed tomography (CT) of cervical spine were normal. Hence the patients were diagnosed as cases of adult SCIWORA. However, subsequent magnetic resonance imaging (MRI) of the two patients revealed cervical cord injury in the form of cord contusion and disc protrusion, respectively. Patient with cord contusion was managed medically, whereas the patient with disc lesion was treated with discectomy. Patient treated with discectomy showed marked improvement. Therefore, patients having no osseous injury on X ray and CT scan should have an MRI study done to look for surgically correctable pathology. As in such rare patients of SCIOWRA an early diagnosis and timely intervention is crucial; with MRI playing a pivotal role.

Keywords: Post-Traumatic Myelopathy, Spinal cord injuries, Adults, Magnetic resonance imaging, SCIWORA.

Introduction

The term Spinal cord injury without radiographic abnormality (SCIWORA) is defined as a syndrome of post traumatic myelopathy that is demonstrable through magnetic resonance imaging (MRI) of the spinal cord, with no evidence of osseous injury on radiographic or computerized tomography (CT) study. SCIWORA was first described by Pang and Wilberger in 1982 specifically in children under 8 years of age with a reported incidence ranging from 4-66%.¹

The incidence of SCIWORA in adults is as low as 0.08%-15% except for the elderly population (>60 years) where the incidence is comparatively higher due to degenerative pathologies.² The rarity of adult SCIWORA poses a diagnostic challenge for clinicians and relies

¹Department of Neurosurgery, Rawalpindi Medical College and Allied Hospitals, Rawalpindi, ²⁻⁴Final Year Medical Student, Rawalpindi Medical College, Rawalpindi, Pakistan.

Correspondence: Shafaq Mahmood. Email: shafaq.mahmood93@gmail.com

immensely on clinical skills to identify intra neural injury despite normal X-ray films and CT scans in the presence of progressive neurological deficits. Hence, for a timely diagnosis and management, its awareness among clinicians is extremely important to optimize the prognostic outcome of a patient.³ Keeping in view, we report here two cases of adult SCIWORA who presented to us with quadriplegia following a road traffic accident (RTA).

Case Report

Case 1:

A 38 years old male presented to us with history of severe neck and right shoulder pain following a road traffic accident. On examination his vitals were normal. He had a GCS of 15/15. His neck movements were painful. Urinary and bowel function were normal. His sensory system was intact. On motor examination, muscle bulk and tone were normal. Motor strength as per MRC (medical research council) grading was 0/5 in both upper and lower limbs. Reflexes were exaggerated in both upper and lower limbs. Plantars were mute bilaterally. Rest of the systemic examination was unremarkable. We classified our patient as AIS- grade B according to American spinal injury association impairment (ASIA) scale.

His X-ray cervical spine (AP- lateral view) showed no soft

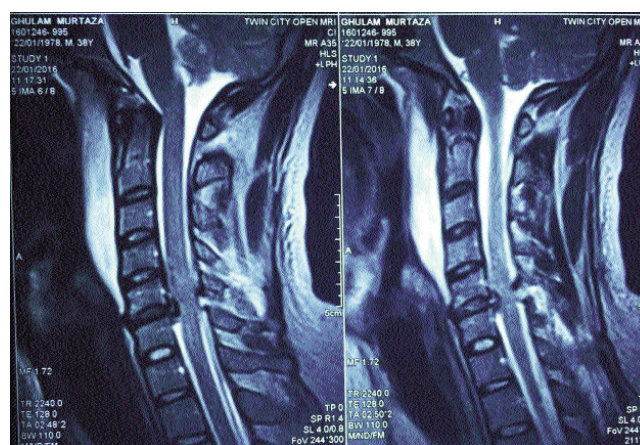

Figure-1: Plain MRI cervical spine.

tissue swelling, loss of alignment or fractures and thus did not correlate with the clinical findings. Subsequently, his (plain) CT scan of the cervical spine was also unremarkable. Later on, MRI cervical spine (plain) was performed which showed straightening of the cervical spine and C5-C6 disc protrusion with annular tear causing ventral thecal sac cord compression at this site. No bony injury was seen. Joints and paravertebral soft tissue were normal (Figure-1).

On the basis of clinical presentation and MRI, patient was diagnosed as a case of SCIWORA. He was initially managed conservatively with complete bed rest and rigid neck immobilization. Medical management was instituted and I/V steroids were started. He was scheduled for surgery after 2 days on the first available elective list. He was operated on the 3rd post admission day and C5-C6 disectomy was done by the anterior approach. Patient was discharged on the 7th post-operative day. Follow up after two weeks of surgery showed that he had recovered with an MRC grade-3 power in both upper limbs. He is still being followed up on monthly basis.

Case 2:

A 45 years old male presented to us following a road traffic accident with severe neck and left leg pain along with multiple skin bruises. On examination his vitals were stable and GCS was 15/15. There was complete loss of urinary and bowel functions. On examination of limbs, his sensory system was intact. Motor examination revealed gross hypotonia in upper limbs whereas lower limbs were hypertonic. Muscle bulk was normal. Motor power as per MRC grading was 0/5 in both upper and lower limbs. Reflexes were absent in upper limbs and normal in lower limbs. Right Plantar was upgoing and left was mute. He was classified as AIS-grade C.

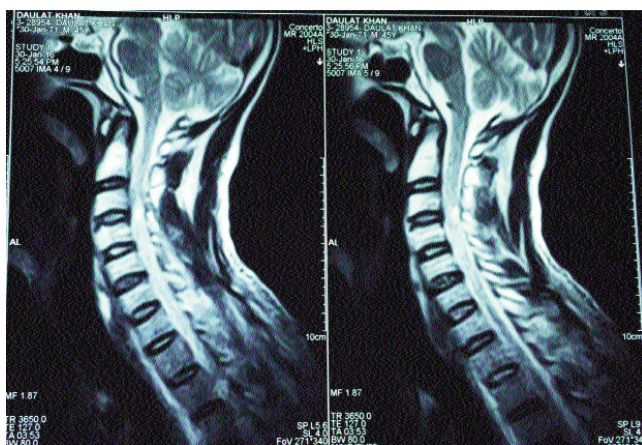


Figure-2: Plain MRI cervical spine.

X-ray (AP lateral view) and CT scan of cervical spine were normal. His (plain) MRI cervical spine revealed C3-C4 cord contusion (Figure-2). Based on it, a clinical diagnosis of SCIWORA was made. He was managed conservatively with rigid neck immobilization and I/V steroids. His repeated examination after one week of medical therapy did not show any improvement. Treatment was continued and patient was kept on follow up on monthly basis.

Consent of both patients was taken prior to the writing of the manuscript.

Discussion

Spinal cord injury without a concomitant vertebral abnormality on radiography and tomography is commonly seen in paediatric population. However, it is a very rare phenomenon in adults with less than 100 cases reported till date.⁴ With an increased availability and usage, MRI has now become an investigation of choice for the diagnosis of SCIWORA. It also helps to determine the severity of cord lesion and thus acts as a useful prognostic tool.⁵

Most cases of SCIWORA occur in cervical spine owing to its hypermobility and increased vulnerability to trauma.⁶ RTA and fall from height have been reported as the most common causes by far.⁷ Pang and Wilberger described hyperflexion, hyperextension, longitudinal distraction and ischaemia as the most probable mechanisms involved in the development of SCIWORA. However, the exact pathophysiology is still not confirmed.⁴

SCIWORA can have a wide spectrum of neurological dysfunction, ranging from mild, transient spinal cord concussive deficits to permanent, complete injuries of the spinal cord.⁸ Onset of neurological deficits may be acute or delayed ranging from a few minutes to 24h and even up to 4 days.⁹ Both of our patients developed quadriplegia but the onset was delayed by 6 hours in second patient. Hence, performing MRI in an apparently normal patient with no evidence of cervical spine injury on X-ray and CT is of significant value for making a timely diagnosis.⁶ Till now, no strict rule has been established for treating SCIWORA and an obvious difference of opinion exists among clinicians regarding its surgical and conservative management. Kalra et al. suggested conservative management of cervical spine injury by neck immobilization and high dose steroids.⁸ Whereas, Saruhashi et al. indicated neck immobilization only for those patients who showed good response to steroids while patients with severe or progressive symptoms should undergo surgical intervention.⁷

However, our patients were initially managed

conservatively. But later on, surgical decompression was carried out in first patient with disc prolapse which resulted in a favourable outcome. Hence, it can be concluded that mixed intra neural and extra neural injuries should be managed surgically as compared to purely intra neural injuries which shows good results even with conservative management, as suggested by Sharma et al.⁴

It has been postulated that patients with SCIWORA have a better prognosis than the patients with concomitant osseous injury.⁵ Survival in these patients depends on several factors viz. age, extent of damage, degree of primary and secondary injury, complications associated with trauma and patterns of intra parenchymal cord lesions identified on MRI.¹⁰ Liao et al. described four patterns of parenchymal cord injuries, namely, concussion, oedema, contusion and transection.¹⁰ Many authors^{4,5,11,12} have highlighted the role of MRI in prognosticating the outcome of patients with SCIWORA. According to Sharma et al. cord oedema has the best prognosis and cord haemorrhage has the worst.⁴

On the other hand, Singh et al. concluded that only normal looking cord on MRI is a sign of good prognosis whereas the prognosis progressively worsened with intramedullary lesions.⁵ Similarly, in our patients we observed that the patient with cord contusion failed to improve, however the patient with disc prolapse improved significantly after surgical intervention. According to the literature, MRI is superior to CT in providing better visualization of neurological and soft tissue structures due to excellent contrast between disc, vertebral body and cerebrospinal fluid. Hence, it is strongly recommended for evaluation of acute traumatic disc prolapse which is often missed on CT scan. If left untreated, it can severely compromise the neurological outcome of a patient by causing new or worsening injury to the cord.¹³ In our first patient, early detection of disc herniation on MRI enabled us in making a decision in favour of prompt surgical decompression that significantly improved the neurological status of our patient post operatively. Thus considering its benefits, we recommend performing an early MRI in all the patients presenting with spinal trauma to avoid any delay in making diagnosis and initiating accurate treatment in these patients.

Conclusion

A high degree of suspicion of SCIWORA is imperative

in the patients of spinal cord injury who present with a neurological deficit and apparently normal radiographs and computed tomography. Moreover, clinicians should have a low threshold for performing MRI study in these patients as it is a sensitive method of revealing ligamentous damage and disc protrusion, which are hallmarks in the mechanics of cord injury.

Disclaimer: The abstract has not been presented or published in a conference, or published in an abstract book.

Conflict of Interest: None to declare.

Funding Disclosure: None to declare.

References

1. Khatri K, Farooque K, Gupta A, Sharma V. Spinal cord injury without radiological abnormality in adult thoracic spinal trauma. *Arch Trauma Res* 2014; 3: e19036.
2. Bazán PL. Significance of sciwora in adults. *Coluna* 2015; 14: 134-7.
3. Crawford S, Bleetman T. Adult spinal cord injury without radiological abnormality. *J Accid Emerg Med* 2000; 17: 374-5.
4. Sharma S, Singh M, Wani IH, Sharma S, Sharma N, Singh D. Adult spinal cord injury without radiographic abnormalities (sciwora): clinical and radiological correlations. *J Clin Med Res* 2009; 1: 165-72.
5. Singh AP, Bharati S, Ahmed S, Mishra L, Singh KD. Spinal cord injury without radiographic abnormality. *Indian J Crit Care Med* 2006; 10: 187-90.
6. Ayaz SB, Gill ZA, Matee S, Khan AA. Spinal cord injury without radiographic abnormalities (sciwora) in a preschool child: a case report. *J Postgrad Med Inst* 2014; 28: 228-30.
7. Saruhashi Y, Hukuda S, Katsuura A, Asajima S, Omura K. Clinical outcomes of cervical spinal cord injuries without radiographic evidence of trauma. *Spinal Cord* 1998; 36: 567-73.
8. Kalra V, Gulati S, Kamate M, Garg A. Sciwora-spinal cord injury without radiological abnormality. *Indian J Pediatr* 2006; 73: 829-31.
9. Ergun A, Oder W. Pediatric care report of spinal cord injury without radiographic abnormality (SCIWORA): case report and literature review. *Spinal Cord* 2003; 41: 249-53.
10. Liao CC, Lui TN, Chen LR, Chuang CC, Huang YC. Spinal cord injury without radiological abnormality in preschool-aged children: correlation of magnetic resonance imaging findings with neurological outcomes. *J Neurosurg* 2005; 103: 17-23.
11. Sidram V, Tripathy P, Ghorai SP, Ghosh SN. Spinal cord injury without radiographic abnormality (sciwora) in children: a kolkata experience. *Indian J Neurotrauma* 2009; 6: 133-6.
12. Yalbuздag SA, Kaya T, Sengul I, Karatepe AG, Adilbelli ZH. Sciwora at thoracic level in an adult: a case report. *J Clin Anal Med* 2015; 6(suppl 5): 629-31
13. Kumar Y, Hayashi D. Role of magnetic resonance imaging in acute spinal trauma: a pictorial review. *BMC Musculoskelet Disord* 2016; 17: 310.