

Spontaneous evisceration of umbilical hernia in a patient with congenital nephrotic syndrome

Nilüfer Goknar, Gokhan Gundogdu, Mehmet Kucukkoc, Aysegul Dogan Demir, Aysel Vehapoglu, Faruk Oktem

Abstract

Congenital nephrotic syndrome is a term used to describe a condition in babies who develop severe proteinuria and hypoalbuminaemia within their first three months of life. They generally have oedema and ascites from birth which, because of increased intra-abdominal pressure, can result in an umbilical hernia. The report presents a five-month old infant with congenital nephrotic syndrome who had spontaneous umbilical hernia rupture with evisceration. The approach to umbilical hernias is usually conservative, but in selected cases elective surgery may be indicated.

Keywords: Umbilical Hernia, Evisceration, Nephrotic Syndrome.

Introduction

Umbilical hernia (UH) is a common paediatric diagnosis with high incidence of spontaneous closure.¹⁻³ Prematurity and race are risk factors that predispose to UH. African infants experience it 10 times more commonly than whites and 75% of infants weighing less than 1500g have UH.⁴ Compared with adult patients, paediatric cases rarely experience complications as incarceration or strangulation.⁵ Rupture with evisceration is very rare but a potentially fatal complication and the organ usually eviscerated is the bowel. The age of the child, the defect size, ulceration of the umbilical skin and increased intra abdominal pressure are known precipitating factors.⁴

Congenital nephrotic syndrome (CNS) is an autosomal recessive disease that occurs sporadically around the world.⁶ Infants with CNS are born prematurely, with low birth weight for age. The disease manifests itself with massive proteinuria, hypoproteinaemia, and gross peripheral oedema starting within the first weeks of life.⁷ The most common complications are infections. Also seen are failure to thrive, umbilical hernias, and developmental delay. The disease course is rapidly progressive, and end stage renal failure generally occurs within the first decade of life.⁸ Ascites, a common condition accompanying CNS secondary to hypoalbuminaemia, is an important cause of

umbilical hernias, but umbilical hernia rupture has not yet been reported in the literature.

We present here a congenital nephrotic syndrome patient complicated by umbilical hernia (UH) evisceration. Consent was taken from the parents for publishing the case.

Case Report

A five-month-old girl had congenital nephrotic syndrome diagnosed when she was a newborn. The case was first seen in November 2011 in our institute. Her spot urine protein/creatinine ratio was 32 and serum albumin level was 1.7mg/dl. She was being given captopril (4mg/kg/day), indomethacin (3mg/kg/day) and infusions of albumin (1g/kg) three times a week. Her daily urine output was 3cc/kg/day. Genetic analysis disclosed a mutation on the NPHS1 (nephrin) gene (variation: c.3478C>T, the change on the protein: p.R1160X). Ascites, severe oedema, and umbilical hernia had been present since birth. The size of the hernia increased during crying periods, and she was a restless baby with long crying periods. Three weeks before, she had been taken to paediatric surgery for consultation and, since the defect size was found to be less than 15 mm, she was assigned to outpatient follow-up.

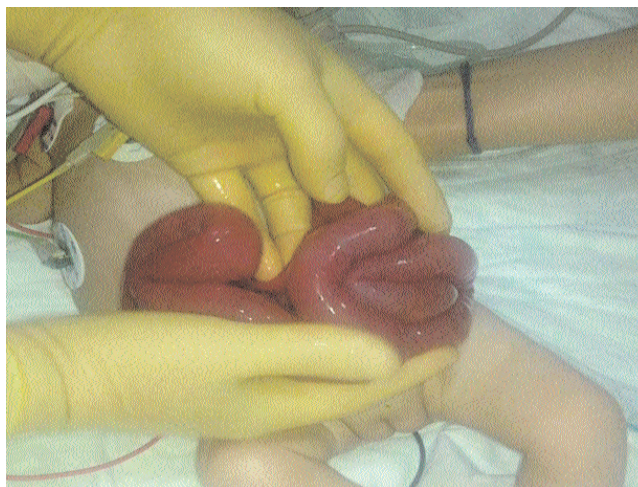


Figure: Preoperative appearance of the eviscerated UH.

.....
Bezmialem Vakif University, Istanbul, Turkey.

Correspondence: Nilüfer Goknar. Email: nilufergoknar@gmail.com

On the day of admission, the family noticed fluid discharge from the patient's hernia. After her admission, abdominal content was eviscerated from the hernia sac. Physical examination revealed that the patient was hypotonic and that abdominal contents had herniated through the umbilicus. Anasarca type oedema was predominant. Laboratory examinations revealed leukocytosis with neutrophilia, mild anaemia (Hb: 8.4g/dl), hypoalbuminaemia (1.4g/dl), an elevated c-reactive protein level (7.33mg/dl), and normal renal function tests (creatinine: 0.01mg/dl). An operation in the intensive care unit (ICU) was performed in which the small bowel as well as the ascending, transverse, and descending colons were eviscerated (Figure). During the reduction of the eviscerated bowel into the abdomen, a small perforation occurred in the small intestine and was immediately repaired.

The patient was managed with intravenous fluid replacement, antibiotics, and appropriate analgesics. She required only one erythrocyte transfusion, but to manage hypoalbuminaemia, albumin infusion was initiated. She stayed in the ICU for ten days and was then transferred to the nephrology department. On the 14th day of her hospitalization, she was started on enteral feeding, which resulted in flatulence on that same day. Six days later, she was discharged with captopril and indomethacin treatment.

The institutional approval and informed consent from the parents of children was taken for publishing this case report.

Discussion

Umbilical hernias are seen frequently in the paediatric population. The prevalence in white children at birth ranges from 10-30% and at 1 year of age decreases to 2-10%.¹ UH occurs because of the failure of the umbilical ring to contract and close after ligation of the umbilical cord. Anatomically, the umbilical fascia derives from the transversalis fascia and should provide support to the base of the umbilicus. When this fascia is weak or absent, a direct hernia occurs.⁵ The majority of hernias are asymptomatic and thus surgery is not routinely indicated.⁷ The indications for surgery include psychological or cosmetic problems plus treatment or prevention of incarceration.³ In addition, girls older than 2 years of age and boys older than 4 years can have elective surgery if their hernias are wider than 1.5cm.¹⁰

Spontaneous evisceration is an extremely rare complication of UH. Thomson et al² presented a literature review of 19 cases with spontaneous evisceration of abdominal contents through UH. Except one case which

had bladder evisceration, the other organs were bowel and/or omentum. The average age was 13 months (range: 2 months to 11 years). The size of fascial defect ranged from 1.3 to 6 cm. Precipitating causes included umbilical ulceration or sepsis (4), crying (3), respiratory infection (3), intussusceptions (1), and ascites (1). One case had Hurler syndrome which is a mucopolysaccharidosis and generally seen with umbilical hernias. She was three years old and the parents noticed an increase in size of UH, becoming more transparent and shiny and a reddish discoloration before evisceration. Damage to the umbilical skin right before rupture is an important risk factor for evisceration. Overall mortality of UH evisceration has been reported to be only 10% (the death of two infants). These two cases were young infants (three months and six week old) and had treatment delay secondary to late admission to hospital.²

In our patient, umbilical hernia was complicated with rupture because of increased intra-abdominal pressure due to excessive crying, ascites, and severe oedema. During the operation, bowel rupture also occurred. Surprisingly, with primary restoration the patient survived and feeding was begun on the fourteenth day. In general, surgery for patients with CNS has high risk and is usually not advised because of their short life expectancy. On the other hand, spontaneous rupture of a UH is very low, so in most cases conservative management is appropriate. An early operation might be indicated in cases of increased abdominal pressure due to crying, ascites, or respiratory problems. Surgical management of UH might prevent high-risk emergency surgery and the probability of faecal contamination.

Conclusion

In conclusion, umbilical hernia evisceration and spontaneous rupture of bowel content is a rare complication that causes high infant mortality, but it occurred in our patient because of severe oedema and the resultant increased abdominal pressure. Since most UHs of less than 15 mm ultimately close spontaneously, a conservative approach to umbilical hernias is typically justified, but surgery should be considered in specific circumstances that warrant such treatment.

Disclaimer: The abstract has been presented in the congress of Cocuk Nefroloji 2012 in poster session.

Conflict of Interest: None.

Funding Disclosure: None.

References

1. Zendejas B, Kuchena A, Onkendi EO, Lohse CM, Moir CR, Ishitan? MB, et al. Fifty-three-year experience with pediatric umbilical

- hernia repairs. *J Ped Surg* 2011; 46: 2151-6.
 2. Thomson WL, Wood RJ, Millar AJ. A literature review of spontaneous evisceration in pediatric umbilical hernias. *Pediatr Surg Int* 2012; 28: 467-70.
 3. Lassaletta L., Fonkalsrud EW, Tovar JA, Dudgeon D, Asch MJ. The management of umbilical hernias in infancy and childhood. *J Pediatr Surg*.1975; 10: 405-9.
 4. Pandey A, Kumar V, Gangopadhyay AN, Upadhyaya VD. Eviscerated urinary bladder via ruptured umbilical hernia: a rare occurrence. *Hernia*.2008; 12: 317-9.
 5. Weik J, Moores D. An unusual case of umbilical hernia rupture with evisceration. *J Pediatr Surg* 2005; 40: 33-5.
 6. Niaudet P. Genetic forms of nephrotic syndrome. *Pediatr Nephrol* 2004; 19: 1313-8.
 7. Jalanko H. Congenital nephrotic syndrome. *Pediatr Nephrol* 2009; 24: 2121-8.
 8. Savage JM, Jefferson JA, Maxwell AP, Hughes AE, Shanks JH, Gill D. Improved prognosis for congenital nephrotic syndrome of the Finnish type in Irish families. *Arch Dis Child*.1999; 80: 466-9.
 9. Marinkovi? S, Bukarica S. Umbilical hernia in children. *Med Pregl* 2003; 56: 291-4.
 10. Haller JA Jr, Morgan WW Jr, White JJ, Stumbaugh S. Repair of umbilical hernias in childhood to prevent adult incarceration. *Am Surg* 1971; 37: 245-6.
-