

Lipohypertrophy

Sanjay Kalra,¹ Fatema Jawad²

Abstract

This communication focuses on lipohypertrophy (LH), which is a commonly seen, yet easily preventable insulin site reaction. LH can be detected at an early stage by regular inspection and palpation. This can prevent the excessive requirement of insulin, and the glycaemic variability that is encountered when insulin is injected into areas with LH. This article describes the etiology, clinical features and preventive measures of LH.

Keywords: Insulin injection, Insulin technique, Insulin site reaction, Prevention.

Definition

Lipohypertrophy (LH) is a thickened, soft to firm, 'rubbery' swelling caused by hypertrophy of adipose tissue at sites of repeated insulin injection.^{1,2} LH is a common insulin site reaction (ISR), which occurs as a complication of insulin therapy. Other common ISRs include pain, bleeding and bruising while ISRs that are rarely encountered include lipoatrophy, acanthosis nigricans, insulin injection induced hyperpigmentation, and amyloidosis.¹⁻³

Prevalence

The prevalence of LH is variable, and depends upon various factors. Large published studies report prevalence rates of 64.4%.⁴ As LH is diagnosed by means of clinical examination, there may be significant inter-observer variation in the reporting of this condition.

Etiology

Various etiologic factors have been postulated to cause LH. While earlier it was thought to be due to the anabolic effect of locally injected insulin, LH is now thought to be caused by repeated trauma. Frequent injections of insulin at a particular site, without changing the needle, predispose to adipose tissue hypertrophy. Non-rotation and non-change of insulin injection site and needle are the principal etiology factors.^{1,4}

¹Department of Endocrinology, Bharti Hospital, Karnal, India, ²Consultant Diabetologist, SIUT, Karachi, Pakistan.

Correspondence: Sanjay Kalra. Email: brideknl@gmail.com

Patients who have high daily insulin requirement, take frequent injections of insulin, or are on basal-bolus therapy are more likely to have LH. LH is also more often noticed in patients who have not been educated by a diabetes nurse.

Clinical Features

LH presents as a thickened, soft to firm, or 'rubbery' swelling at the site of insulin injection administration.¹ While larger lesions can be diagnosed on inspection alone (Figures-1, 2, 3), smaller ones can be detected only by palpation. The swelling is painless, non-discoloured, non-tender, movable in all directions, but cannot be pinched together.

Patients often report that they prefer to inject at the site of LH lesion, as these injections are painless. However, there is reduced and variable absorption of insulin injected into LH lesions. This may lead to an increased requirement of insulin, and may also cause high glycaemic variability. The resultant episodes of

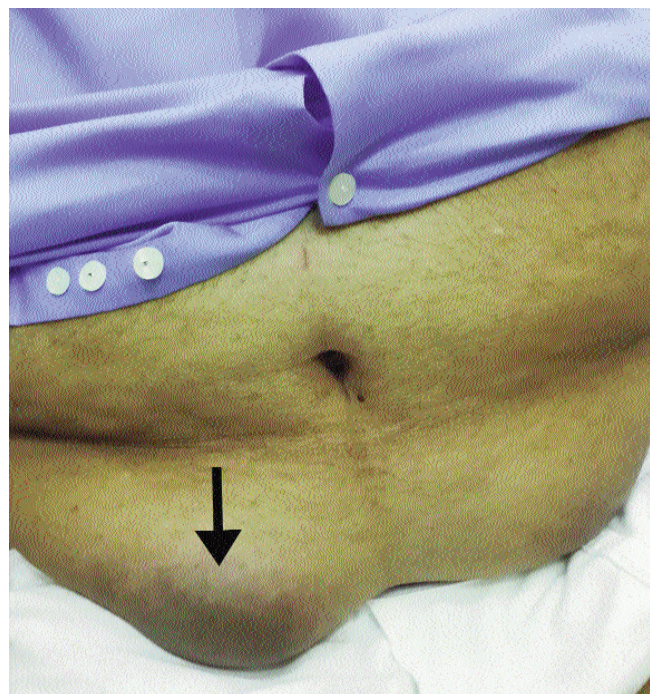


Figure-1: Large LH.

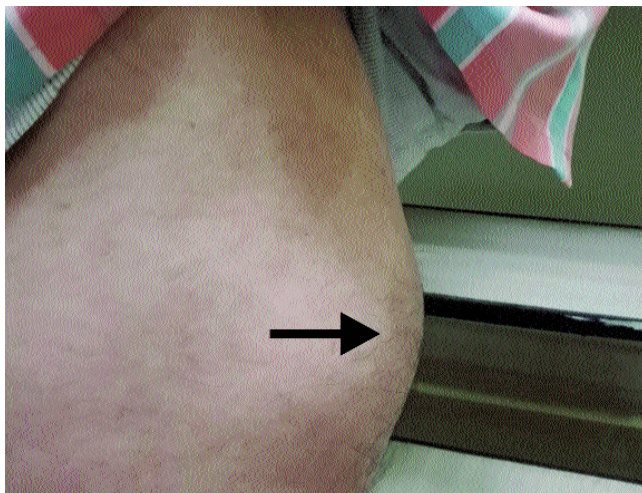

Figure-2: LH Front of thigh.

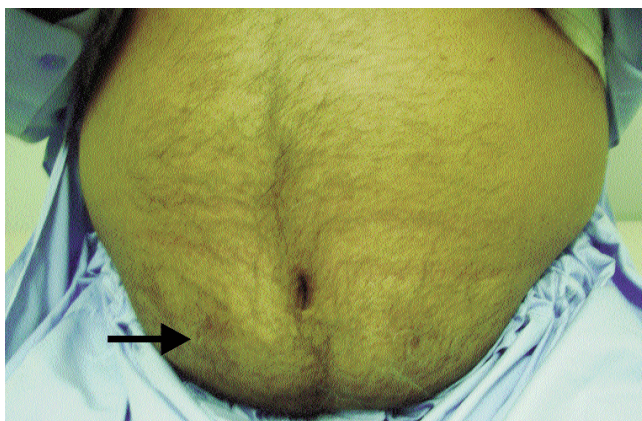


Figure-3: LH Abdominal wall.

unexplainable hypoglycaemia and hyperglycaemia may lead to unnecessary diagnostic and frustrate attempts to achieve optimal glycaemic control.¹

Change in site of injection, from LH lesions to healthy subcutaneous tissue, may result in sudden hypoglycaemia due to enhanced insulin absorption.

Insulin doses must be reduced, under appropriate glucose monitoring, when such a shift is performed. The patient must be educated and counseled in detail about hypoglycaemia prevention, detection, and management.

Prevention

The best management of LH is prevention. Regular inspection and palpation of insulin injection sites must be carried out, both by the patient and by the health care provider (HCP). The HCP should ensure adequate lighting, comfortable ambient temperature, and apposite privacy while examining the patient. The patient should preferably be in supine position, and the injection site should be disrobed. Ideally, palpation must be performed using a lubricant gel.

Early detection of LH is helpful because this allows institution of good injection practices, including site rotation, and avoidance of needle reuse. It also allows the patient to identify healthy subcutaneous tissue that can be used for injecting insulin, with maximal absorption capacity.

Focus on correct rotations, as well as avoidance of reuse, along with general good injections practices, is an essential to LH prevention. Correct site rotation is defined as administering insulin injections at least 1 cm apart, in a systematic manner, to avoid repeated local tissue damage, while ensuring stable insulin absorption.¹ Injection technique training should be made an integral part of diabetes education, which should be continued on ongoing basis.

References

1. Tandon N, Kalra S, Balhara YS, Baruah MP, Chadha M, Chandalia HB, et al. Forum for Injection Technique (FIT), India: The Indian recommendations 2.0, for best practice in Insulin Injection Technique, 2015. *Indian J Endocr Metab* 2015; 19: 317-31.
2. Sawatkar GU, Dogra S, Bhadada SK, Kanwar AJ. Insulin injection: cutaneous adverse effects. *Indian J Endocr Metab* 2015; 19: 533-4.
3. Kalra S, Balhara YP, Baruah MP, Chadha M, Chandalia HB, Chowdhury S, et al. Addendum 2: Forum for Injection Technique, India. *Indian J Endocr Metab* 2014; 18: 800-3.
4. Blanco M, Hernandez MT, Strauss KW, Amaya M. Prevalence and risk factors of lipohypertrophy in insulin-injecting patients with diabetes. *Diabetes & metabolism*. 2013; 39: 445-53.