

Congenital lobar emphysema

Irum Latif, Samina Shamim, Shah Ali

Abstract

Congenital lobar emphysema is a rare variety of congenital malformation of lung characterized by over distension of a lobe of the lung due to partial obstruction of the bronchus. It is one of the rare causes of infantile respiratory distress requiring surgical resection of affected lobe. We are reporting the case of an 8-week-old baby who presented with respiratory distress related to CLE affecting the left upper lobe. Lobectomy was performed under general anaesthesia followed by an uneventful recovery.

Keywords: Congenital lobar emphysema, Congenital malformation, Lung.

Introduction

Congenital Lobar emphysema (CLE) is a rare anomaly with an incidence of 1:20,000 to 1:30,000 live births.¹ It is due to over inflation of a lobe resulting from intrinsic deficiency of bronchial cartilage and elastic tissue with most common involvement is of the left upper lobe followed by right upper lobe and right middle lobe.² The bronchial obstruction can also be due to external compression by an aberrant vessel or internal narrowing by mucosal flaps or the wall may be kinked by herniation in the mediastinum.³ Some of the cases are autosomal dominant while others may be sporadic.⁴ Males are more affected with a male to female ratio of 3:1. The reason for male predominance is unknown.^{4,5} It usually presents in the neonatal period but diagnosis may be delayed up to 5-6 months in 5% patients.³ It can also be diagnosed on antenatal ultrasound.⁶ The signs of presentation range from mild tachypnoea, wheeze to severe dyspnoea with cyanosis.⁴ Congenital heart disease has an association with congenital lobar emphysema.⁷ In literature 12-20% concomitant CHD have been reported.⁹ The treatment of congenital lobar emphysema is surgical excision of the affected lobe.¹⁰ We share our experience of successfully managing a case of congenital lobar emphysema. As this is a rare disorder presentation

similar to common lower respiratory tract infections but can be easily detected on antenatal anomaly scan, which helps in early diagnosis and timely management.

Case Report

For reporting this case, informed consent was taken from parents with full confidentiality maintained regarding identity of the patient and family.

A two-month old male baby was seen in the outpatient department of Liaquat National Hospital Karachi, on 20th July 2014. There was a history of mild cough for 5-days followed by increase in respiratory rate, noisy breathing and reluctance to feed for one day. There was

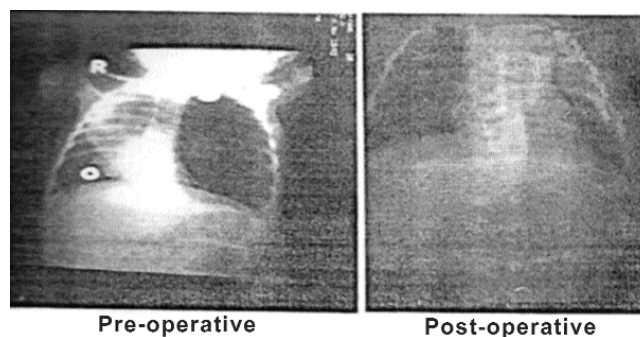


Figure-1a: Chest X-Ray.

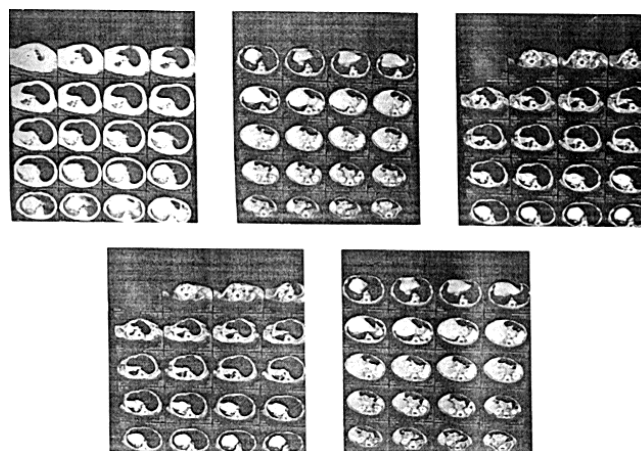


Figure-1b: Chest CT Scan.

.....
Liaquat National Hospital, Institute for Postgraduate Medical Studies and Health Science, Karachi, Pakistan.

Correspondence: Irum Latif. Email: drirumlatif@yahoo.com

no history of cyanosis, convulsions or fever. Past history was unremarkable except mother noticed occasional episodes of fast breathing and nasal obstruction for which she consulted a local doctor where reassurance was given. Baby was delivered by LSCS due to non progress of labour. Post natal period was unremarkable. Antenatally mother had several ultrasound scans but no lung pathology was detected or reported.

On examination, the baby had respiratory distress with high respiratory rate using accessory muscle of respiration. He was irritable and restless but not febrile. The infant had pulse of 160/min, Respiratory rate 70/min and maintaining oxygen saturation of 85% on room air. Chest examination revealed asymmetry with bulging of left hemithorax with decreased air entry on the left side of chest and scattered rhonchi and creptitations were audible on right side. Rest of the examination was unremarkable. The initial clinical diagnosis was bronchiolitis or pneumonia with or without pneumothorax for which urgent X-ray was advised (Figure-1a). X-Ray Chest findings were markedly hyperinflated lung with trans mediastinal herniation and with displacement of mediastinum and thymus towards right side. Compressive atelectasis of the lower lobe was seen with flattening of hemidiaphragm.

For further evaluation CT-Chest was advised (Figure-1b) which gave findings of Hyperinflation with vascular attenuation and widely separated vascular markings seen involving left upper lobe. It was associated with shifting of mediastinum and transmediastinal herniation of left upper lobe. There was compression atelectasis of left lower lobe. Mild fibrosis with atelectasis was seen in right upper and lower lobes. Findings were due to congenital lobar emphysema involving left upper lobe.

The baby underwent left thoracostomy with left upper lobe lobectomy. Post operatively patient remained vitally stable and maintaining oxygen saturation at room air. On follow up he is well with appropriate growth for age.

Discussion

Congenital lobar emphysema is although a rare disorder of lung development, it is due to partial obstruction of lobar Bronchus which results in overaeration of affected lobe with irreversible destructions of alveolar septa.^{2,3} Its presentation is similar to pneumonia and bronchiolitis as both of these conditions present with tachypnoea but fever is one of the important clinical signs that differentiates it from

CLE.⁴ The clinical manifestation may vary from mild tachypnoea to severe respiratory distress.^{3,5} With progressive destruction it becomes more difficult for the air to leave the alveoli than to enter as the obstructed bronchus impairs the complete emptying of alveoli during passive phase of expiration.² As the CLE varies from severe respiratory distress to mild tachypnoea, the time of diagnosis also varies. The presentation depends upon the extent of emphysema.⁸ The diagnosis is established by radiography. The infant presents with respiratory distress usually in the neonatal period or in early 2 months of life. In 5% cases diagnosis is delayed. Antenatal ultrasound in 20 to 24 weeks pregnancy⁷ can diagnose CLE which was missed in our case. The time of diagnosis also varies as in more than 90% cases the clinical finding becomes apparent in the first 2 months of life, as also seen in our patient. The diagnosis of CLE is not suspected / considered on clinical grounds. This is because when a child with typical presentation of cough, respiratory and feeding difficulty with tachypnoea and use of accessory muscles, the initial disease of Pneumonia or bronchiolitis is made, as per IMNCI guidelines for developing countries.¹⁰ Due to absence of fever in this case but obvious respiratory distress an urgent X-ray was advised. The diagnosis of CLE was established by radiography, and CT scan confirmed the diagnosis. As CLE has an association with CHD so Echocardiography should be done to exclude ATRIAL SEPTAL DEFECT II. As the treatment of CLE is surgical excision of the affected lobe, lobectomy was done in our case. The child had an uneventful recovery and was discharged on 5th post operative day, breathing in room air and taking oral feeds. Long term prognosis is good but crowding of ribs / scoliosis/ chest deformity can occur. As this condition is autosomal dominant.⁴ So it can run in the family parents of such a baby will need genetic counseling for the next pregnancy.⁴ In our case mother was advised to undergo a specific anomaly scan in subsequent pregnancies. Prognosis of congenital lobar pneumonia is excellent as reported in literature.¹⁰

Conclusion

Early diagnosis and treatment improves the prognosis of CLE. An afebrile infant with respiratory distress should be subjected to radiography for early diagnosis of CLE. The mother should be advised to have an anomaly scan in future pregnancies.

References

1. Jilani ML, Malik BA, Mahmood T, Aslam M, Afzal M. Congenital

- lobar emphysema: a diagnostic challenge but treatable congenital disorder of lungs. *J Pakistan armed forces*. 2011;1.
2. Kulkarni SS, Karkhanis VZ, Joshi JM. Congenital Lobar Emphysema presenting at late childhood: A rare case report. *Lung India*. 2014; 31:302-4.
 3. Abdellah O, Mohamed H, Bouabdellah Y, Bouharrou A. A case of congenital lobar emphysema in the middle lobe. *J ClinNeonatal*. 2013; 2:135-7.
 4. Nath MP, Gupta S, Kumar A, Chakrabarty A. Congenital lobar emphysema in neonates: Anaesthetic challenge. *Indian J Anaesth*. 2011;55:280-3.
 5. Abushahin AM, Tuffaha AS, Khalil NK, Ismael AM. Bilateral congenital lobar emphysema: A rare cause of respiratory distress in infancy. *Ann Thoracic Med*. 2012; 7:250-2.
 6. Shivaprasad B, Lakshmi V, Shanmugasundaram R. Neonatal Lobar Emphysema presenting as opaque lung. *Sch J Med Case Rep*. 2014; 2:672-3.
 7. Tempe DK, Viramani S, Javetkar S, Banerjee A, Puri SK, Datt V. Congenital lobar emphysema: Pitfalls and management. *Ann Card Anaesth*. 2010; 13:53-8.
 8. Kliegman RM, Bonita MD. Congenital malformation of lung. In: Kliegman RM, Bonita MD, Stanton, GemeJS, Schor N, Behrman RE, eds. *Nelson text book of pediatrics 19th ed*, Philadelphia, PA : Elsevier Saunders, 2011; pp 387-8.
 9. Dogan R, Dogan OF, Yilmaz M, Demircin M, Pasaoglu I, Kiper N, et al. surgical management of infant with congenital lobar emphysema and concomitant heart disease. *HeartSurg Forum*. 2004; 7:E644-9.
 10. World Health Organization. *Integrated management of neonatal and childhood illnesses*. WHO, 2015.
 11. Gul Z, Liaqat F, Khan HA, UI Haq SZ, Tehreem M. Congenital lobar emphysema. *Gomal J Med Sci*. 2013; 11:236-8.
-