

Angiokeratoma of tongue: a series of 14 cases

Nausheen Yaqoob, Aamir Ahsan, Zubair Ahmed, Akhter Husain, Rashid Ahmed, Naila Kayani, Shahid Pervez, Sheema Hassan

Department of Pathology, Aga Khan University Hospital, Karachi.

Abstract

Angiokeratomas (AC) are vascular lesions which are defined histologically as one or more dilated blood vessels lying directly subepidermal and showing an epidermal proliferative reaction with ectatic capillaries in the papillary dermis. Only three other cases of isolated mucosal angiokeratoma have been reported in the indexed literature. We reviewed all cases of angiokeratoma located on the tongue, diagnosed in our department during a study period of 10 years (1995-2005).

Histologically all 14 cases showed dilated and congested blood vessels in the upper papillary dermis. They lack deep dermal involvement. Hyperkeratosis and acanthosis were also seen in most of the cases. No clinical data was available to assess systemic disease. A higher incidence of of AC in tongue is seen in our study.

Introduction

Angiokeratomas (AC) represent ectasia of superficial blood vessels associated with secondary epidermal changes, especially acanthosis and hyperkeratosis. Five variants have been described.¹ They are: 1) the generalized systemic type-angiokeratoma corporis diffusum of Fabry; 2) multiple papular, and plaque like - angiokeratoma circumscriptum (naeviforme); 3) the bilateral form occurring on the dorsal areas of the fingers and toes- angiokeratoma of mibelli; 4) angiokeratoma of Fordyce- the localized scrotal form; and 5) solitary papular angiokeratoma, although usually single, multiple lesions may occur between the age of 10 and 40 years and the legs are the site of predilection.

Multiple lesions have been reported in zosteriform distribution.² Association of angiokeratoma circumscriptum with angiokeratoma of the scrotum^{3,4} angiodyplasia (Klippel-Trenaunay-Weber syndrome) Cobb syndrome, and other mixed vascular malformations have been reported.^{1,5}

Methods and Results

We reviewed all cases of AC located on the tongue (n=14) diagnosed in our department during a study period of 10 years (1995-2005). Location of the lesions was tip of tongue in 2 cases, anterior two third in 2 cases, posterior one third in 2 cases, dorsum of tongue in 1 case and location was not mentioned in 7 cases. In 2 cases, the clinical query was

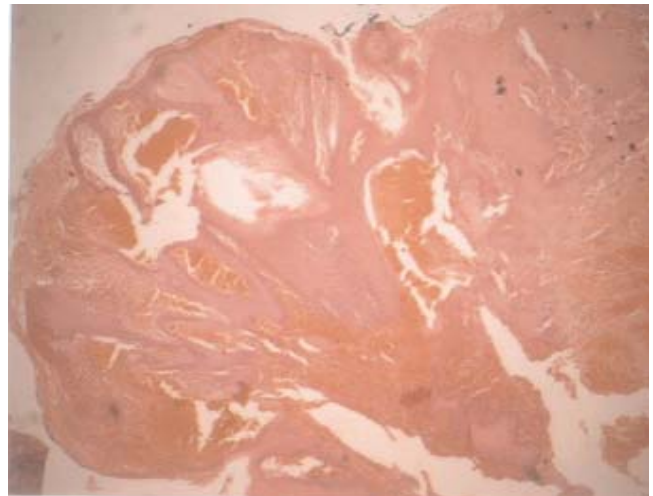


Figure 1. Low power view of angiokeratoma; dilated blood vessels with congested thin walls. Lower parts of dermis are unremarkable (H & E staining, magnification (10x).

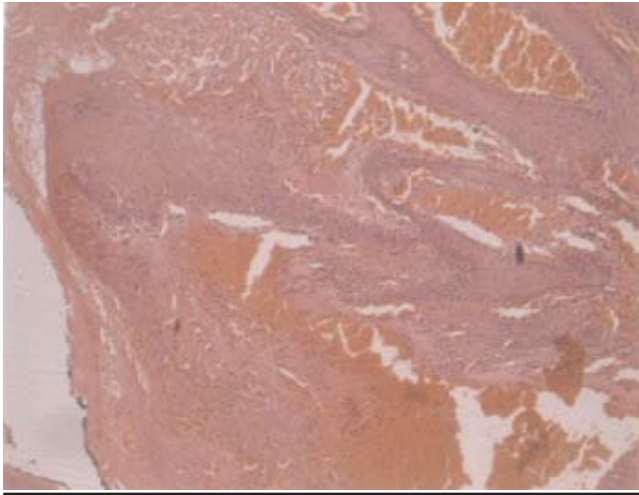


Figure 2. High power view of angiokeratoma (H & E staining, magnification (20x).

that of angiokeratoma, however, in 5 cases there was clinical suspicion of haemangioma. Two cases were clinically malignant; rest of the 3 cases were suspected to be benign growths. Four cases were seen in males and 5 in females, whereas gender data was unavailable in 5 cases.

Histologically all cases showed dilated and congested blood vessels in the upper papillary dermis. They lacked deep dermal involvement. Hyperkeratosis and acanthosis was also present in most of the cases. There was evidence of papillomatosis. No clinical data was available to assess systemic disease.

Discussion

Angiokeratomas (AC) are vascular lesions which are defined histologically as one or more dilated blood vessels lying directly subepidermal and showing an epidermal proliferative reaction with ectatic capillaries in the papillary dermis. The epidermal changes in all forms of AC are secondary. The different entities causing vessel ectasia lead to the many clinical variants of angiokeratoma. The histological features in all variants are similar and consist of numerous dilated and congested capillaries in the papillary dermis. Hyperkeratosis may be seen on the surface. There is associated irregular acanthosis of the epidermis with elongation of the rete ridges which partially or completely enclose the vascular channels. A collarette may be formed at the margins of the lesions and there may be thrombosis of the vessels. Differential diagnosis always includes haemangioma, these histological appearances can be seen in superficial portion of a verrucous haemangioma however haemangiomas always have a deep dermal and subcutaneous counterpart. The main distinction between these conditions is the presence of angiomatous capillary endothelial proliferation in the haemangiomas.

Immunohistochemical studies have shown matrix metalloproteinase (MMP)-9 localized in the epidermis just

under the horny layer, particularly in the hyperkeratotic lesions of angiokeratoma circumscriptum. The expression of MMP-9 may be related to the hyperkeratotic changes in the lesion.

Oral mucosal involvement most commonly is a component of angiokeratoma corporis diffusum (fabry disease) and fucosidosis, however it is very uncommon in other types of angiokeratomas.⁶ Although solitary cutaneous forms have been reported, to date localized lesions within the oral cavity have not been described commonly. Only three other cases of isolated mucosal angiokeratoma have been reported in the indexed literature, two of them by Vijaykumar et al.^{7,8} Leung et al reported the third case in an 82-year-old man with a history of squamous cell carcinoma of the ear and scalp who also had a solitary pigmented lesion of the oral cavity which was consistent with AC on histological examination.⁹

Very few cases of AC of the scrotum associated with AC of the oral cavity have been described in literature.^{3, 4} Recently Karthikeyan et al³ reported a similar case. Rappaport¹⁰ and Shiffman had reported simultaneous involvement of jejunum, oral mucosa, tongue and scrotum. Although all these types differ clinically, they share a similar histological picture.

The pathogenesis of AC is still unknown. It is thought to be a telangiectatic lesion arising from local injury to capillaries in the papillary dermis, either from trauma or venous hypertension, with secondary epithelial proliferation causing acanthosis and hyperkeratosis. It has been reported to develop overlying an arteriovenous fistula and in an area of lymphangioma circumscriptum after repeated local injuries.⁷

Systemic angiokeratoma corporis diffusum (Anderson-Fabry disease) is an unusual X-linked lysosomal disorder characterized by deficiency of α -galactosidase. The clinical manifestations of the disease predominantly result from the progressive deposition of Gal-Gal-Glc-Cer in the vascular endothelium. Onset of the disease usually occurs during childhood or adolescence with periodic crises of severe pain in the extremities (acroparesthesias) and the appearance of vascular cutaneous lesions (angiokeratomas), hypohidrosis or anhidrosis, and characteristic corneal and lenticular opacities. In Anderson-Fabry's disease, intracytoplasmic lipid vacuoles have been described in endothelial cells, pericytes and fibroblasts.^{1,3} The vascular cutaneous lesions (angiokeratoma) of ACD manifest as numerous clusters of tiny red papules in a symmetrical distribution, usually in the "bathing trunk" area. Fabry's disease and fucosidosis have mucosal involvement as part of their generalized involvement.

Angiokeratoma circumscriptum is rare and most characteristically takes the form of an extensive vascular plaque, usually present from birth and are not related with systemic diseases. The lesion is typically hyperkeratotic papules or nodules situated unilaterally on the foot or distal aspect of the leg, but can occur elsewhere on the body. It is of particular clinical importance because of its morphologic similarities to malignant skin tumors such as malignant melanoma or pigmented basal cell carcinoma. Therefore, this rare but significant lesion must be recognized by physicians and surgeons who manage skin tumors.

Treatment is generally not necessary, except for bleeding, discomfort, and cosmetic reasons. Individual lesions can be destroyed with simple excision, cryosurgery, electrodesiccation, or lasers.

Our study shows a higher incidence of AC in tongue; these patients probably had systemic disease too. However, owing to lack of availability of clinical data, a possibility of systemic angiokeratoma corporis diffusum with oral mucosal involvement cannot be excluded completely.

References

1. Calonje E, Wilson-Jones E. Vascular tumors. In: Elder D, Elenitsas R, Jaworsky C, Johnson B Jr, eds. *Lever's Histopathology of skin*. 8th Ed. Philadelphia: Lippincott-Raven, 1997, p. 899.
 2. Eizaguirre X, Landa N, Raton JA, Diaz-Perez JL. Multiple angiokeratomas with zosteriform distribution in two sisters. *Int J Dermatol* 1994;33:641-2.
 3. Karthikeyan K, Sethuraman G, Thappa DM. Angiokeratoma of the oral cavity and scrotum. *J Dermatol* 2000;27:131-2.
 4. Jansen T, Bechara FG, Stucker M, Altmeyer P. Angiokeratoma of the scrotum (Fordyce type) associated with angiokeratoma of the oral cavity. *Acta Derm Venereol* 2002;82:208-10.
 5. Black MM, Grawkrodger DJ, Seymour CA, Weismann K. Metabolic and nutritional disorders. In: Champion RH, Burton JL, Burns DA, Breathnach SM, eds. *Textbook of Dermatology*. Oxford Blackwell Science: 1998, pp. 2577 - 2677.
 6. Atherton DJ. Naevi and other developmental defects. In: Champion RH, Burton JL, Burns DA, Breathnach SM, eds, *Rook/Wilkinson/Ebling textbook of Dermatology*, 6th ed. vol 1. Oxford: Blackwell Science. 1998:592-5.
 7. Vijaikumar M, Thappa DM, Karthikeyan K, Jayanthi S. Angiokeratoma circumscriptum of the tongue. *Pediatr Dermatol* 2003;20:180-2.
 8. Kumar MV, Thappa DM, Shanmugam S, Ratnakar C. Angiokeratoma circumscriptum of the oral cavity. *Acta Derm Venereol* 1998;78:472.
 9. Leung CS, Jordan RC. Solitary angiokeratoma of the oral cavity. *Oral Surg Oral Med Oral Pathol Oral Radiol Endod* 1997;84:51-3.
 10. Rappaport I, Shiffman MA. Multiple phlebectasia involving jejunum, oral cavity and scrotum. *JAMA* 1963;185:437-40.
-