

Case Report

Extra pulmonary uptake of Tc-99m-MAA Perfusion lung scan as a result of right to left Intra Cardiac Shunt

Riffat Hussain¹, Maseeh-uz-Zaman¹, Sohail Abrar Khan², M Nadeem Ahmad¹

Department of Radiology¹, Department of Cardiology², Aga Khan University Hospital, Karachi.

Abstract

Extra pulmonary accumulation of Tc-99m-macroaggregate of albumin (MAA) is rarely seen on perfusion lung scan, and has been reported in less than 4% of a study population of nearly 380 patients¹. It occurs when the agent bypasses the lungs due to a right to left (R-L) cardiac or pulmonary shunt, when it is shunted to the portal vein before reaching the right atrium and ventricle of the heart, and when the agent is degraded to a submicron particle size.² When a pharmaceutical problem is excluded, extra-pulmonary uptake implies unusual hemodynamics with a shunt.

A case is reported in which a clinically unsuspected shunt was diagnosed from the lung perfusion scintigraphy.

Case Report

A 25 year old female was referred for a lung perfusion scintigraphy for progressive dyspnoea for the past 3 years. This dyspnoea had progressed to a stage that it was present even on mild exertion and sometimes even on rest for the past 1 ½ months. Her history and clinical findings failed to elicit a definite cause for her symptoms. She was suspected to be suffering from a possible thrombo-pulmonary embolism. For which she was referred to the Nuclear Medicine Department. Her recent chest x-ray was within normal limits. On the pulmonary scan both the lungs showed a normal homogenous uptake of the

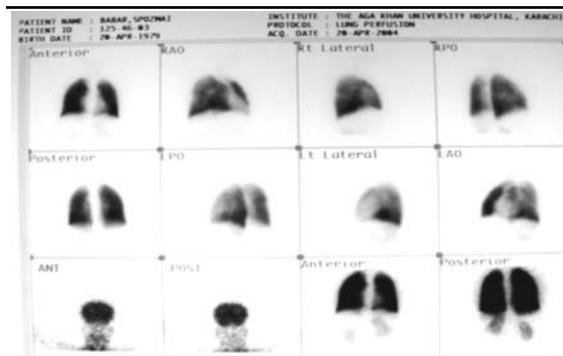


Figure 1. Lung Perfusion Scan with both lung fields showing normal uptake. Uptake of tracer is seen in the brain and in kidneys suggesting a right to left shunt.

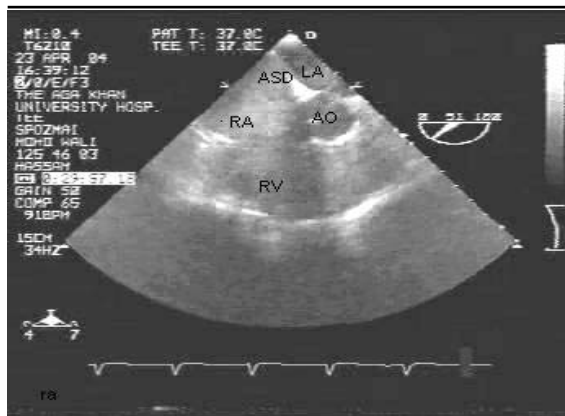


Figure 2. Agitated saline contrast is visible in Left Atrium (LA) due to right to left shunt through ASD.

tracer with no evidence of any segmental or sub-segmental pleural based perfusion defect seen. However the kidneys were seen to be visualized on

the scan, and when the head was imaged, significant amount of tracer was seen in the brain (Figure 1). No activity to suggest the presence of free pertechnetate was seen in the thyroid, salivary glands, or the stomach. The patient was subsequently reported to be having a right to left shunt of a most probable cardiac origin. She then underwent a trans-esophageal and trans-thoracic echo-cardiogram where a bidirectional flowing atrial septal defect with pulmonary hypertension was confirmed (Figure 2). Subsequently right heart catheterization also showed atrial septal defect and an anomalous pulmonary venous drainage into the right atrium. Reversibility of pulmonary hypertension was also assessed after 100% oxygen inhalation which was found to be irreversible.

Discussion

Regional pulmonary perfusion is evaluated by imaging the distribution of Tc-99m-MAA. The radiopharmaceutical consists of particles of denatured albumin, most of which are 20 - 40 micrometer size. Following intravenous injection into a peripheral vein, the radio labeled particles travel through the right atrium and right ventricle, where a thorough mixing occurs. The physiological principle exploited is that the I/V injected micro-emboli will be trapped in the arterioles of the lung in proportion to the regional pulmonary blood flow.^{3,4}

From time to time when activity is seen outside the lungs, the question arises as to whether it is due to right to left shunt shunting or to free Tc-99m-pertechnetate in the radiopharmaceutical preparation. The distinction is made by imaging the brain. Tc-99m-pertechnetate and other nonparticulate potential radio contaminants do not cross the blood brain barrier or localize in the brain. Shunted Tc-99m-MAA will lodge in the cerebral circulation.^{5, 6}

Shunting is a situation where deoxygenated blood is able to bypass the process of gas exchange and return from the right side of the heart to the systemic circulation. It may result from large vessel

abnormalities such as atrial or ventricular septal defect in the heart or occur as result of perfusion of poorly ventilated regions of the lung.^{6, 7} In patients with right to left shunt some of the injected particles will be diverted into the systemic circulation and will embolize pre-capillary arterioles throughout the body.^{3, 8} A right to left shunt of more than 10% is readily apparent on the scan by identifying activity in organs with high systemic blood flow such as the kidneys and the brain.⁹ The hemodynamic significance of the shunt may be anywhere along the spectrum between minor and major and its quantification may be inferred from the perfusion scan.¹⁰⁻¹²

References

1. Kume N, Suga K, Uchisako H, Matsui M, Shimizu K, Matsunaga N. Abnormal extra pulmonary accumulation of Tc-99m-MAA during lung perfusion scanning. *Ann Nucl Med* 1995;9:179-84.
2. Kumar RK, Priyadarshini R, Manivannan K, Shan mugasundaram B, Anuradha S. Quantification of right-to-left shunt by Tc99m macroaggregated albumin. *IJNM* 2003;18:73-5.
3. Royal H D. Pulmonary and Thoracic. In Maisey M N, Britton KE, Collier BD, eds. *Clinical nuclear medicine*, 3rd edition. Chapman and Hall Medical, London. 1998; p.221-2.
4. Parker JA, Coleman ER, Hilson AJW, et al: Society of Nucl Med Procedures Guidelines for lung scintigraphy. Version 3, SNM 2004.
5. Thrall JH, Ziessman HA: Pulmonary System. In Thrall JH, Ziessman HA. *Nuclear Medicine: The Requisites*. Mosby, St. Louis, MO. 1995:132-3.
6. Durand E, Bussy E, Gaillard JF: Lung scintigraphy in post pneumonectomy dyspnea due to right-to-left shunt. *J Nucl Med* 1997;38:1812-5.
7. Wall HV, Magnussen JS. Non-embolic disease of the lung. In Murray IPC and Ell PJ, eds. *Nuclear Medicine in clinical diagnosis and treatment*, 2nd edition. Churchill Livingstone, London: 1998; pp55-64.
8. Nguyen BD, Roarke MC: Superior vena cava obstruction with intrahepatic and systemic pulmonary venous right-to-left shunts. *Clin Nucl Med* 2004;29:491-3.
9. Freeman LM, Krynycky, Zucker LS: Enhanced lung scan diagnosis of pulmonary embolism with the use of ancillary scintigraphic findings and clinical co-relations. *Semin Nucl Med* 2001;31: 143-57.
10. Habibian MR. Pulmonary Scintigraphy. In Habibian MR, Delbeke D, Martin WH, Sandler MP, eds. *Nuclear Medicine Imaging; A teaching file*, Lippincott Williams and Wilkins, Philadelphia. 1999; pp13-136.
11. Goshen E, Oksman Y, Rotenberg G, Zwas ST. Absent pulmonary uptake on Tc-99m-MAA perfusion lung scan due to severe right to left shunt. *Sem in Nucl Med* 2004;34:157-8.
12. Marini C, Miniati M, Pratali L, Tonelli L, Carminati M, Formichi B, et al: Interatrial right-to-left shunt after lung surgery: Diagnostic value of perfusion lung scanning. *AMJ Med Scie* 2004;328:180-4.