

Experience with Lateral Cheek Rotation Flap for the Reconstruction of Medial Cheek Soft Tissue Defects

Mamoon Rashid, Saad ur Rehman Sarwar, Shahid Hameed, Tahir Masood

Department of Plastic Surgery, Combined Military Hospital, Rawalpindi.

Abstract

Objective: To analyze the results of reconstruction in terms of complications, functional restoration and cosmetic restoration of lateral cheek rotation flap.

Methods: A cross sectional study was conducted between April 2004 and January 2005. Patient's particulars and history were documented. The cause, whether trauma or tumor resection, and dimensions of the defects were recorded. All the patients underwent a "cheek rotation flap" procedure to reconstruct the defect. Post-operative complications like haematoma formation, infection and flap necrosis were noted. Results were assessed in terms of functional as well as aesthetic restoration.

Results: A total of 30 patients were included with a male to female ratio of 3:1 and an average age of 46 ± 14.7 . The majority of the defects (76%) were post tumour excision, while the rest (24%) followed trauma. The average defect diameter was 7.5 cms. There was no peri-operative mortality or total flap loss. There were three cases (10%) of transient facial nerve palsy who recovered spontaneously. The final reconstruction was deemed satisfactory in terms of functional and cosmetic restoration in the majority of cases (93%).

Conclusion: Our results with the lateral cheek rotation flap to reconstruct the defects involving medial cheek have prompted us to recommend it as a first line reconstructive option for many varieties of defects in this area (JPMA 56:227;2006).

Introduction

The cheek and mid-face is a highly visible and an aesthetically important part of a person's countenance. The cheek was divided into three overlapping aesthetical units by Gonzalez-Ulloa et

al: zone I includes suborbital, zone II preauricular and zone III buccomandibular regions.¹ Large skin defects in zone I following tumour excision or trauma can present a reconstructive challenge.² Various reconstructive options such as full - thickness skin

grafts, local rotation or advancement flaps, regional flaps, tissue expansion and free tissue transfer are used in this zone.³⁻⁷ Lateral cheek rotation flap is a preferable option to reconstruct these defects as it replaces like-with-like tissue.

Lateral cheek rotation flap is well described in the literature.⁸ This involves elevation of posteroinferiorly based lateral cheek skin flap to rotate and advance medially and upwards. This flap is a particularly quick, versatile and reliable option for use in medial cheek defects.⁹

Zone I in cheek is a common site of post-traumatic and post tumour resection defects.^{10,11} Reconstruction in this zone is particularly a challenge for a plastic surgeon. It ideally demands a reconstructive option capable of restoring function as well as aesthetics.¹² Any suboptimal reconstruction will lead to lower lid ectropion resulting in continuous corneal exposure affecting the vision. It can also amount to an aesthetically poor result leading to low patient satisfaction thus affecting his social life. As lateral cheek rotation flap is a commonly employed procedure to reconstruct the large defects of medial cheek, it is important to analyze the results of reconstruction in terms of complications, functional restoration and cosmetic restoration and to disseminate this information.

Subjects and Methods

A cross sectional study was conducted with purposive sampling. All the patients (without any age and gender discretion) who presented to the department of Plastic Surgery, CMH Rawalpindi, with a soft tissue defect involving the medial cheek either due to trauma or tumor resection were included. The patients who had a life threatening co-morbid injury or a previous history of significant trauma to the same side of face and / or neck were excluded from the study. The duration of study spans over 10 months between April 2004 to January 2005. Each patient was given a serial number and date of presentation was noted. Patients' particulars, history of occupation, any previous surgery, causes of the defects and the extent and dimensions of the defects were noted. All the patients underwent a "cheek rotation flap" procedure to reconstruct the defect (Figure 1, 2 and 3). Post-operative complications like haematoma formation under the flap, infection and flap necrosis were noted. Results were assessed in terms of functional as well as aesthetic restoration. Functional restoration was labelled as inadequate if

there was any exposure of cornea after the attempted closure of eye or if there was any spontaneous involuntary or in-coordinated movements appreciated in the affected facial expression muscle group. Cosmetic restoration was further assessed according to the patient's view and surgeon's view. Patient was labelled as unsatisfied if he asked for any kind of revision procedure and satisfied when he followed-up regularly and did not ask for any revision procedure. In surgeon's view, satisfactory restoration was documented when the scars were hidden and along the natural creases without any distortion of adjacent anatomical structures, and colour and contour matched with the surroundings.

Results

A total of 30 patients were studied of whom 23 were males and seven females with a male to female ratio of 3:1. The ages of our patients ranged from fourteen to sixty-three years with an average of 46 ± 14.7 . The majority of the defects (23/30, 76%) were because of skin tumour excision, while the rest (7/30, 24%) followed trauma. The size of the defect requiring reconstruction ranged between 3 cm and 12 cm in diameter, with an average of 7.5 ± 3 cm. In 21 patients (70%), the defects involved the skin and subcutaneous tissues only, while bony resection was also to be performed in nine patients (30%). The overall complication rate was 23% which included haematoma formation in 13% (4/30) and partial flap necrosis in 10% (3/30). We did not encounter any wound infection and there was no peri-operative mortality or total flap loss. The patients who developed haematoma under the flap required evacuation, and one developed minor necrosis of the tip of the flap. This complication was also encountered in two other patients, both of them were smokers. There were three cases (10%) of transient facial nerve palsy involving the temporal and zygomatic branches, all of them recovered spontaneously. The final reconstruction was deemed satisfactory in terms of functional restoration in the majority of the cases, only two patients (7%) had an inadequate eye closure who underwent an additional surgery for the correction of lower lid ectropion, while all the patients had intact normal facial expressions. In 28 patients (93%) reconstruction was deemed satisfactory in terms of cosmetic restoration by patients and surgeon, only two patients (7%) underwent revision surgery for residual dog-ear correction to improve cosmesis.

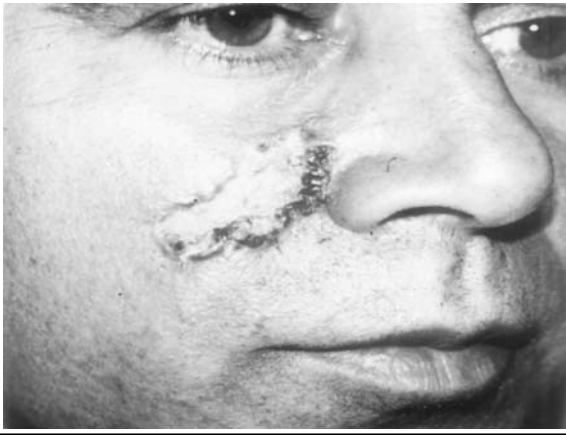

Figure 1: Skin tumor involving medial cheek.

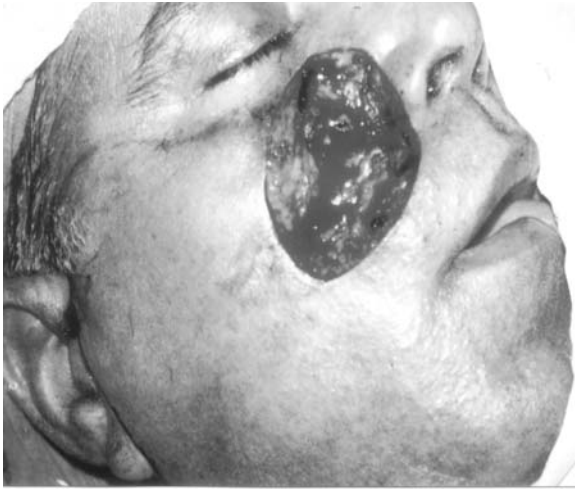

Figure 2: Defect after tumor excision.




Figure 3: Postoperative result with restoration of form and function.

Discussion

Despite a plethora of available reconstructive options, replacing specialised facial

skin with "like" tissue is difficult. Skin grafts are seldom a good colour or texture match and their use should probably be limited to skin replacement in a patient with an aggressive tumour, to allow observation for recurrence.³ Cheek defects lend themselves well to local flaps as cheek skin is of medium thickness and loosely bound to underlying connective tissue. Historically, various anteriorly-based cheek rotation flaps such as those described by Mustardé⁸, Converse¹³, Juri¹⁴ and Jackson¹⁵ have been used. More recently, Kroll¹⁶ and Longaker¹⁷ have incorporated the "deep plane" principle in the elevation of these flaps. The widespread popularity of tissue expansion has led to the incorporation of this technique into conventional flap designs; expanders these may be used in this area as well.⁵ Larger and more complex defects may require chest flaps or even free tissue transfers.⁶

The lateral cheek rotation flap that have been used in this study is closest in design to that described by Jackson¹⁵, and is an extension of that concept for more medial and upper facial defects. It was found to be reliable, quick to execute, and capable of covering large defects. With careful design, it could reach to the eyebrow, can cover the whole lateral part of the nose, or reconstruct the skin of the upper lip, along with resurfacing the medial cheek area. Thus one flap could suffice for defects that may otherwise require two flaps or more. It provided skin of excellent colour and texture, and most of the scars might be hidden in natural skin folds. There was no additional donor site. Even when the flap reconstructed adjoining aesthetic units (medial cheek and nose), it could maintain natural facial contours. Although elevation of the flap might require extensive mobilisation and some attention to operative detail, it is otherwise a "low-tech" reconstruction. In contrast with microsurgical transfers, it did not require special equipment, and might actually provide skin of much better quality than a free flap unless a prefabricated flap is used. Compared with tissue expansion, it has the obvious advantages of being a single-stage procedure. However, it obviated the need for an expander which is an important financial consideration in developing nations.

Our complication rate was generally been low. Because of the large area of undermining, meticulous haemostasis was essential if haematoma was to be avoided. Partial tip necrosis in three of our patients (all smokers) did not require any revision surgery. It might be possible that using the "deep plane" technique for the elevation of this flap may reduce the

incidence of this complication.¹⁷ The problem that has been is related to the transfer of hair-bearing skin to the medial cheek area.

Conclusion

We do not propose this flap as a panacea for all defects of the cheek and midface. Each patient and each defect must be judged on its own merits and treatment individualised. Our results with this flap, however, prompt us to recommend it as a first line reconstructive option for many varieties of defects in this area.

References

1. Gonzalez -Ulloa M, Cartillo A, Stevens E, Alvarez fuertes G, Leonetli F, Ubalbo F. Preliminary study of the total restoration of the facial skin. *Plast Recon Surg* 1954;13:151-61.
 2. Flynn TC, McDonald WS, Chastain MA. The "facelift" flap for reconstruction of cheek, lateral orbit, and temple defects. *Dermatol Surg* 1999;25:836-43.
 3. Maas CS, Eriksson TP. Local flaps in cheek reconstruction. *Facial Plast Surg Clin North Am* 1996;4:527-36.
 4. Shestak KC, Roth AG, Jones NF, Myers EN. The cervicopectoral rotation flap - a valuable technique for facial reconstruction. *Br J Plast Surg* 1993;46:375-7.
 5. Kawashima T, Yamada A, UedaK, Asato H, Harii K. Tissue expansion in facial reconstruction. *Plast Reconstr Surg* 1994;94:944-50.
 6. Freedman AM, Hidalgo DA. Full thickness cheek and lip reconstruction with the radial forearm free flap. *Ann Plast Surg* 1990;25:287-94.
 7. Hidayatullah, Obaidullah, Asif M, Tahir M, Aslam M. Aesthetic outcome of sliding island flap for reconstruction of cheek after tumor ablation. *J Ayub Medial Coll Abbottabad* 2005;17:15-8.
 8. Mustarde JC. Repair and reconstruction in the orbital region. Boston: Williams and Wilkins; 1976.
 9. Hashmi ZA, Bashir G, Alamsher, Shah H. Reconstruction of post leishmaniasis scar with lateral cheek rotation flap. *J Coll Physicians Surg Pak* 2003;13:405-7.
 10. Motamedi MH, Behnia H. Experience with regional flaps in the comprehensive treatment of maxillofacial soft-tissue injuries in war victims. *J Craniomaxillofac Surg* 1999;27:256-65.
 11. Niazi FAK, Niazi MAK. Periocular basal cell carcinoma: characteristics and distribution among patients. *J Rawal Med Coll* 2003;7:63-8.
 12. Murillo WL, Fernandez W, Caycedo DJ, Dupin CL, Black ES. Cheek and inferior eyelid reconstruction after skin cancer ablation. *Clin Plast Surg* 2004;31:49-67.
 13. Converse JM. *Reconstructive Plastic Surgery*. Philadelphia: WB Saunders, 1977, 1586-1589.
 14. Juri J, Juri C. Advancement and Rotation of a Large Cervicofacial Flap for Cheek Repairs. *Plast reconstr Surg* 1979; 64: 692-96
 15. Jackson IT. *Local Flaps in Head and Neck Reconstruction*. St Louis: Mosby, 1985;218-225.
 16. Kroll SS, Reece GP, Robb G, Black J. Deep plane cervicofacial rotation-advancement flap for reconstruction of large cheek defects. *Plast Reconstr Surg* 1994; 94: 88-93.
 17. Longaker MT, Glat PM, Zide BM. Deep-plane Cervicofacial "Hike": Anatomic Basis with Dog-ear Blepharoplasty. *Plast Reconstr Surg*. 1997;99:16-21.
-