

Role of focused appendiceal Computed Tomography in clinically Equivocal Acute Appendicitis

Kashif Ashraf¹, Omer Ashraf², Vaqar Bari¹, Muhammad Zafar Rafique¹, Muhammad Uzair Usman¹,
Ishtiaq Chisti¹

Department of Radiology¹, Medical Students², Aga Khan University Hospital, Karachi.

Abstract

Objective: To determine the accuracy of FACT (focused appendiceal computed tomography) in evaluation of acute appendicitis.

Methods: The study was conducted in Aga Khan University Hospital, Karachi, over a period of one year. Sixty-three patients with clinically equivocal acute appendicitis underwent thin-section non-enhanced helical CT. Axial scans were obtained in a single breath hold from L2 vertebral level to the pubic symphysis with 5-mm collimation and a pitch of 1.5. All scans were obtained without oral, intravenous, or rectal contrast material. Criteria for diagnosis of acute appendicitis included an enlarged appendix (>6 mm diameter) and periappendiceal inflammation. Final diagnoses were established with the results of surgical or clinical follow-up.

Results: There were 21 true-positive diagnoses, 38 true-negative diagnoses, no false-positive diagnoses, and 2 false-negative diagnoses, which yielded a sensitivity of 91% and a specificity of 100%.

Conclusion: Non-enhanced FACT is a highly accurate problem solving technique in clinically equivocal cases of acute appendicitis (JPMA 56:200;2006).

Introduction

Acute appendicitis remains the most common cause of acute abdominal pain that requires urgent abdominal surgery.¹ Although acute appendicitis can be preoperatively diagnosed on the basis of well-established clinical criteria; its clinical presentation may be atypical or mimic other conditions, yielding a clinical diagnostic accuracy of 60-80%. The erroneous diagnosis of this acute condition has led to a high rate of inappropriate removal of the normal appendix of 8%-30%.² Surgical authorities have maintained that a negative appendectomy rate of 20% is necessary to minimize the incidence of perforated appendicitis and its associated increased morbidity and mortality.³ However, unnecessary appendectomy carries potentially major risks and substantial costs, prompting many to advocate increased efforts to avoid unnecessary appendectomy.⁴ Thin-section helical computed tomography in patients suspected to have acute appendicitis has proved to be an accurate, quick, and cost-effective tool.⁵⁻⁷ Accuracy rates from 92% to 98% have been reported with CT techniques using different combinations of oral, rectal, and intravenous contrast agents.⁵⁻¹²

The objective of this study was to determine

the role of thin section non-enhanced helical computed tomography in clinically equivocal cases of acute appendicitis.

Patients and Methods

Over a one year period, sixty-three patients with clinically equivocal acute appendicitis were examined prospectively by using non-enhanced thin section FACT. Ages ranged from 9 to 67 years, with mean age of 24.5 years. All patients were included regardless of age. Inclusion criteria for clinically equivocal acute appendicitis were based on the clinical judgement of the referring surgeons and emergency care physicians. All CT scans were obtained with a helical CT scanner (HiSpeed Advantage; GE Medical Systems, Milwaukee, Wisconsin, U.S.A.). A single breath-hold helical scan from L2 vertebral body to the pubic symphysis was obtained by using 5-mm beam collimation and pitch of 1.5 (120-140 kVp; 220-250 mAs). No oral, rectal, or intravenous contrast material was administered. Images were reconstructed at 5-mm intervals by using standard soft-tissue windows (window width 400 Hounsfield Units; window level 40 Hounsfield Units). Total patient time in the CT room was approximately 10 minutes.

The primary criterion used to establish the

diagnosis of acute appendicitis on non-enhanced helical CT scans was an enlarged appendix. An appendix larger than 6mm in transverse diameter was considered abnormal. Additional secondary criteria were periappendiceal inflammatory changes.

The presence of an appendicolith was also noted (Figure 1). Presence of an appendicolith in the absence of other primary and secondary criteria was not interpreted as acute appendicitis.

Following completion of the examination, the CT images were immediately reviewed (by the same attending faculty radiologist) at the CT console, where facility for coronal and sagittal reformation was also available. Subsequently, hard copy interpretation was also done before communicating the diagnosis to the surgeon.

The CT findings were compared with the official surgical reports, histopathological reports and medical records of all the 63 patients. All patients who did not undergo surgery were followed up for two months.

Results

Out of the 63 non-enhanced helical CT scans performed, 21 were interpreted as positive and 38 negative for acute appendicitis. There was no false-positive interpretation. There were, however two false-negative interpretations. This resulted in a

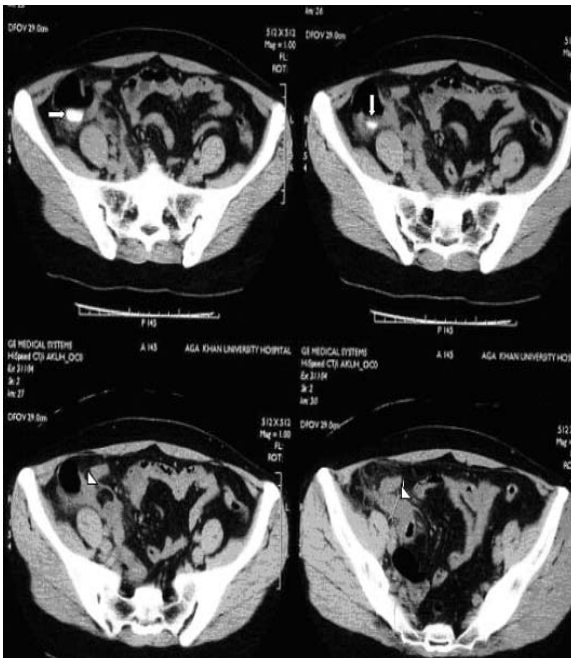

Figure 1. Computed tomographic sections showing appendicolith (arrows) in the top two sections, and demonstrating enlarged appendix in the bottom two images (arrowheads).

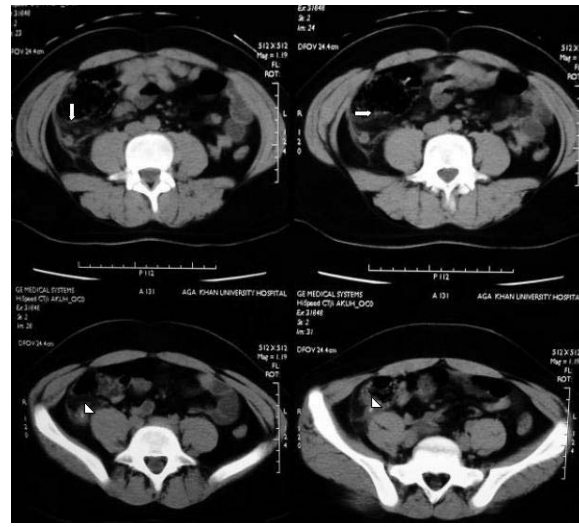


Figure 2. Computed tomographic images showing enlarged appendix in all four axial sections. Evidence of periappendiceal stranding (arrows) in the top two images, and luminal appendicolith in the bottom two sections (arrowheads). sensitivity of 91% and specificity of 100%.

Retrospective review of the two false-negative CT scan interpretations showed an 8mm pelvic appendix in one patient and the appendix was not visualized in another thin, young woman. Both these patients were of slender built. The inflamed appendix was not diagnosed due to location in the first patient and in the second due to presence of multiple dilated small bowel loops in the right iliac fossa.

An appendicolith was identified in 6 (29%) of the 21 true-positive diagnoses (Figure 2). In two other patients, an appendicolith was noted in an otherwise normal appearing appendix with no periappendiceal inflammation. These scans were correctly interpreted as negative.

Discussion

CT is a highly accurate and effective cross-sectional imaging technique for diagnosing acute appendicitis.⁵⁻¹² CT is readily available, operator-independent, easy to perform and images are easy to interpret. Diagnostic sensitivity and specificity are excellent for the entire spectrum of disease manifestations and do not decrease after appendiceal perforation. Unlike ultrasound, obesity rarely limits study acquisition or interpretation, when optimized scanning methods are used.

A cost effective, quick protocol is desirable to expedite patient management. The two issues regarding selection of CT protocol for acute appendicitis relate to section thickness and administration of contrast. All current helical CT protocols for imaging patients suspected to have

appendicitis incorporate the prospective acquisition of thin-section (≤ 5 mm section collimation) images in the right lower quadrant. This scanning philosophy is based on the fact that CT sensitivity and specificity is maximized only when a conscious effort is made to visualize the appendix. The value of improved resolution in this clinical setting has been demonstrated with both conventional and helical CT.^{13,14} Weltman et al¹⁴ showed that 5mm thick helical CT sections enabled improved visualization of abnormal appendices (94% vs. 69%), calcified appendicoliths (38% vs. 19%), and periappendiceal inflammation (98% vs. 75%) compared with 10mm thick sections in the same patient.

Appendiceal CT protocols differ considerably with regard to the anatomic area to be included in the scan and the use of intravenously, orally and rectally administered contrast material. The conservative approach is to perform scanning of the entire abdomen and pelvis with intravenous and oral contrast material. Advocates of this technique believe that contrast enhanced CT is essential in the diagnosis and staging of numerous inflammatory, ischemic, and neoplastic processes that may cause acute abdominal pain and mimic appendicitis.¹⁵

Opacification of the terminal ileum and caecum with oral/rectal contrast material has been proposed by some authors.^{13,16} (in the absence of intravenous contrast material) to avoid false-positive results, in which fluid-filled terminal ileal loops are misinterpreted as inflamed appendices. At our institution, previously our protocol was to perform unenhanced scanning through the right iliac fossa followed by oral and intravenous contrast enhanced scanning of entire abdomen and pelvis. The results were excellent, however retrospective review of the cases confirmed that the findings on the plain scans were not different than those after contrast administration.

An important concern was the time for adequate bowel opacification, which on an average was 45-60 minutes. Few patients were unable to drink the 1-2 liters of oral contrast and in those rectal contrast (150-250ml) had to be administered, which was invasive and unacceptable for some patients. Increased radiation dosage was another issue, as the patient population was mostly young.

Focused on all these issues, we in consultation with referring surgeons initiated a thin section non-enhanced helical focused appendiceal CT protocol, which would be noninvasive, quick and

limited to the right iliac fossa (see methods above).

We also made use of coronal and sagittal reformatting ability in oblique planes. This technique has proved to be as accurate as those techniques in which intravenous and enteric contrast material are administered, while allowing scanning completion within 10 minutes in the majority of patients examined. A similar protocol has been promoted by Lane et al⁵, who advocated use of non-enhanced helical CT of the entire abdomen and pelvis, whereas the protocol we used was limited to the right iliac fossa.

The potential to scan the right lower fossa rapidly without any bowel preparation or contrast medium has made non-enhanced helical CT the study of choice at our institution for the evaluation of patients with clinically nonspecific findings.

Expertise in cross-sectional anatomy of the ascending colon, caecum, and appendix is, however essential for visualization of both the normal and abnormal appendix on a non-enhanced CT scan. Appendiceal identification is at times rendered difficult due to high caecal mobility and variation in its size. Two anatomic landmarks are of great help in localizing the appendix. Foremost is identification of the ileocaecal valve, which then acts as a guide in confirming the attachment of base of the appendix to posteromedial aspect of the caecum. Secondly, if the anatomic course of common and external iliac vessels is traced inferiorly the pelvic appendix can often be seen lying anterior and close to these vessels.

After unequivocal identification, several CT criteria are applied to decide about the status of the appendix. Periappendiceal inflammation has been established to be the most sensitive and an enlarged appendix (>6 mm) the most specific sign for acute appendicitis.¹² Additional findings on CT scans in acute appendicitis include caecal or appendiceal wall thickening, appendicolith, and periappendiceal fluid collections.⁵⁻¹²

Peritoneal fat acts as inherent contrast on a non-enhanced CT and less amount of body fat makes scan interpretation difficult. In one of our cases, the diagnosis was missed due to this reason. Malone et al⁶ also addressed this point. In eight of their ten false negative CT interpretations, patients had little periappendiceal or pericaecal fat. Through our initial work with this technique, we have identified several factors helpful in FACT interpretation, which include better understanding of right iliac fossa anatomy, increased experience with

the technique and increased awareness of the importance of signs suggestive of acute appendicitis on non-enhanced CT scans.

We, therefore, conclude that FACT is the imaging study of choice for evaluation of clinically equivocal acute appendicitis as it is a noninvasive, rapidly performed technique that employs minimal radiation exposure. A certain level of experience is required for skillful interpretation of the scans. In experienced hands, it has got a definite clinical role as proven by excellent results of this study.

References

1. Birnbaum BA, Wilson SR. Appendicitis at the Millennium. *Radiology* 2000;215:337-48.
 2. Zielke A, Hasse C, Sitter H, Rothmund M. Influence of ultrasound on clinical decision making in acute appendicitis: a prospective study. *Eur J Surg* 1998;164:201-9.
 3. Bendeck SE, Nino-Murcia M, Berry GJ, Jeffrey RB Jr. Imaging for suspected appendicitis: negative appendectomy and perforation rates. *Radiology* 2002;225:131-6.
 4. Rao PM, Rhea JT, Novelline RA, Mostafavi AA, McCabe CJ. Effect of computed tomography of the appendix on treatment of patients and use of hospital resources. *N Engl J Med* 1998;338:141-6.
 5. Lane MJ, Katz DS, Ross BA, Clavtice-Engle TL, Mindelzan RE, Jeffrey RB Jr. Unenhanced helical CT for suspected acute appendicitis. *Am J Radiol* 1997;168:405-9.
 6. Malone AJ, Wolf CR, Malmed AS, Melliere BF. Diagnosis of acute appendicitis: value of unenhanced CT. *Am J Radiol* 1993;160:763-6.
 7. Rao PM, Rhea JT, Novelline RA, McCabe CJ, Lawsason JN, Berger DL, et al. Helical CT technique for the diagnosis of appendicitis: prospective evaluation of a focused appendix CT examination. *Radiology* 1997;202:139-44.
 8. Poortman P, Lohle PNM, Schoemaker CM, Oostvogel HJ, Teepen HJ, Zwinderman KA, et al. Comparison of CT and Sonography in the Diagnosis of Acute Appendicitis: A Blinded Prospective Study. *Am J Radiol* 2003;181:1355-9.
 9. Ege G, Akman H, Sahin A, Bugra D, Kuzucuk K. Diagnostic value of unenhanced helical CT in adult patients with suspected acute appendicitis. *Br J Radiol* 2002;75:721-5.
 10. Raman SS, Lu DSK, Kadell BM, Vodopich DJ, Sayse J, Cryer H. Accuracy of Nonfocused Helical CT for the Diagnosis of Acute Appendicitis: A 5-Year Review. *Am J Radiol* 2002;178:1319-25.
 11. Wijetunga R, Tan BS, Rouse JC, Bigg-Wither GW, Doust BD. Diagnostic accuracy of focused appendiceal CT in clinically equivocal cases of acute appendicitis. *Radiology* 2001;221:747-53.
 12. Rao PM, Rhea JT, Novelline RA. Sensitivity and specificity of the individual CT signs of appendicitis: experience with 200 helical appendiceal CT examinations. *J Comput Assist Tomogr* 1997;21:686-92.
 13. Balthazar EJ, Megibow AJ, Siegel SE, Brinbaum BA. Appendicitis: prospective evaluation with high-resolution CT. *Radiology* 1991;180:21-4.
 14. Weltman DI, Yu J, Krumenaker J, Huang S, Mohr P. Diagnosis of acute appendicitis. Comparison of 5mm and 10mm CT sections in the same patient. *Radiology* 2000;216:172-7.
 15. Federle MP. Focused appendix CT technique: a commentary. *Radiology* 1997;202:20-1.
 16. Rao PM, Rhea JT, Novelline RA, Mostafavi AA, Lawsason JN, McCabe CJ. Helical CT combined with contrast material administered only through the colon for imaging of suspected appendicitis. *Am J Radiol* 1997;169:1275-80.
-