

Surgery for Prolactinomas

Ashfaq A. Razzaq, Rashid Jooma

Department of Neurosurgery, Jinnah Postgraduate Medical Center, Karachi.

Abstract

A large proportion of prolactin secreting tumours of the pituitary gland are treatable by dopamine agonist drugs. However certain subgroups of these patients are better managed by surgical excision. The indications for surgery in prolactinomas remain controversial and this paper attempts to clarify these with illustrative cases. The factors favouring a surgical approach include poor tolerance of long term medical therapy, progression of visual deficits or recurrence while on medical treatment, cystic change in the tumour with pressure effects, CSF fistula secondary to tumour shrinkage and prophylactic surgery in tumours anticipated to cause CSF leak following medical therapy. The size and invasiveness of the tumour and the prolactin level are also important determinants of treatment planning. The indications for surgery in prolactinomas are discussed and illustrative cases are presented.

Introduction

The management of prolactinomas has undergone significant revisions over the course of the last decade.¹⁻⁴ These changes represent the clinical application of enhanced understanding of their pathophysiology and increasingly sophisticated imaging due to technological developments.^{2,3} Given the short period over which these

data have been introduced, it is not surprising that the management of prolactinomas remains controversial.

Prolactinomas can be managed conservatively, medically, surgically or by irradiation.⁵ The most commonly modality currently used is medical treatment in the form of dopamine agonists such as Bromocriptine or newer drugs such as Cabergoline.^{1,3} However, several authors assert that surgery is an effective treatment for prolactinomas.² Authors in the West have reported cure rates of 70 percent following transphenoidal surgery for prolactinomas.² However, to date no work has been done in Pakistan to elucidate the indications for surgery in prolactinomas. We attempt to clarify the management of this disease by presenting a case series illustrating the indications of surgery for prolactinomas.

Methods

The medical records of all patients admitted to our neurosurgical unit with a diagnosis of prolactinoma between January 1, 1999 to December 31, 2001 were reviewed retrospectively. Five cases representing the salient indications of surgery were selected and constituted our study group. The patient data was transcribed to specially designed proformas. Patients with prolactin secreting tumours which were well controlled on medical therapy or

did not present with surgical indications were excluded from the study. Data was analyzed by using SPSS version 10 software.

Cases

Patient 1

This 16 year old female patient presented with menorrhagia and secondary amenorrhoea since the past one year. She had no neurological deficits. MR scan showed a large sellar mass with extension into suprasellar cistern (Figure 1). The prolactin level was 545 ng/dl at initial evaluation. The patient was started on bromocriptine with a diagnosis of prolactinoma. However 9 months after the start of treatment the prolactin level increased to 4443 ng/dl. The tumor was judged to be unresponsive to bromocriptine and it was decided to undertake transphenoidal excision of the tumor. Post-operatively the prolactin level decreased to 30 ng/dl and the patient remained without neurological deficits. The estradiol and thyroid hormones were also within normal limits. The menstrual disturbance resolved after the operation.

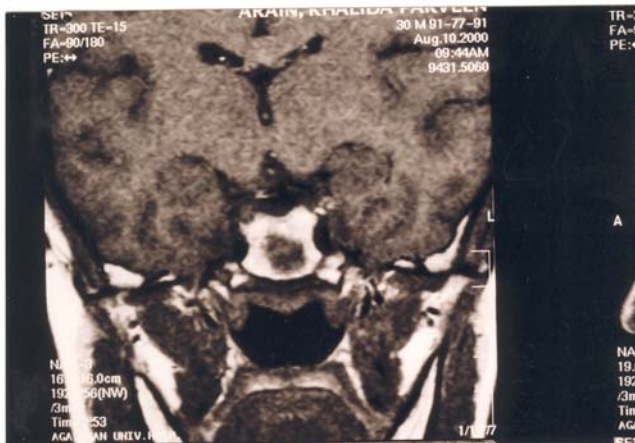

Figure 1. T1W MR scan showing a large sellar tumor with central area of low signal signifying possible cystic change.

Patient 2

This 29 year old female developed amenorrhoea 10 years prior to presentation. She had no neurological deficits at initial examination and prolactinoma had been diagnosed elsewhere. She had conceived on Bromocriptine treatment 2 years ago. However the patient had recently experienced increasing nausea which was not being improved by dose reduction. Recent MR scans showed a large sellar tumor (Figure 2) and the prolactin level was 831 ng/dl. Since the patient's nausea was persistent, transphenoidal surgery was decided. Post-operatively, the prolactin level dropped to 10 ng/dl and the patient was neurologically normal. The nausea and menstrual disturbances resolved after the operation.

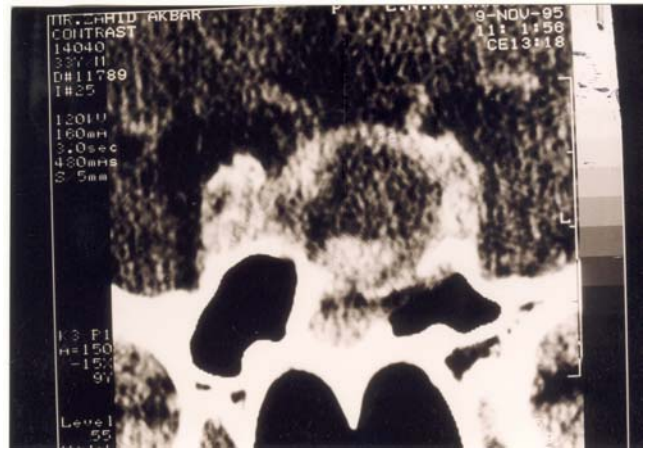


Figure 2. CT scan with contrast showing a large sellar tumor with central non-enhancing area and erosion of floor of sella.

Patient 3

This 23 years old female presented with headache and amenorrhoea of 2 years duration. On examination she was found to have bi-temporal field defects but no other neurological deficit. MR scan showed a large sellar mass enhancing with contrast but with a central low intensity signal signifying possible cystic changes (Figure 1). The prolactin level was found to be 3800 ng/dl. The patient was commenced on Bromocriptine with a diagnosis of prolactinoma. The prolactin level decreased to 1512 ng/dl. However the visual field deficits progressed considerably during the following 3 months as documented by perimetry. It was decided to undertake transphenoidal excision due to the possibility of persistent compression by the cystic component which was not responding to bromocriptine. At operation, a significant cystic component was found and drained along with excision of the solid part of the tumor. Post-operatively the visual field deficits improved significantly and the prolactin levels decreased to 28 ng/dl.

Patient 4

This 33 years old male presented with loss of libido since the past few months. Neurological examination revealed a bi-temporal hemianopia with no other deficits. Skull radiograph had shown an enlarged pituitary fossa and the serum prolactin level was 250 ng/dl. The patient was started on bromocriptine which improved the visual field deficits. However 4 months later, clear fluid started seeping from the right nostril. CT scan showed a sellar tumour with erosion of the sellar floor and herniation of the tumour into the sphenoid sinus (Figure 2). Transphenoidal excision of the tumor was performed with repair of the sellar floor using fascia lata, fat and cartilage. The CSF leak stopped post-operatively and the patient remained neurologically intact.

Patient 5

A 69 year old male presented with decreasing vision in both eyes since 4 months. Examination revealed bitemporal hemianopia with no other deficits. MR scan showed a large sellar tumour with erosion into the sphenoid sinus. The prolactin level was 4105 ng/dl. It was felt that (there would be a chance of CSF leakage if the patient was started on Bromocriptine) due to shrinkage of the invasive tumour. To obviate this possibility, the sphenoid sinus was surgically explored, cleared of tumour and the eroded sellar floor was repaired with a fascial graft secured with fibrin glue. Post-operatively, the patient was commenced on bromocriptine with prompt improvement of the visual field deficits.

Discussion

The indications for surgery in prolactinomas have been subject of previous investigations by several authors.^{1,2} There have been differing guidelines and recommendations by these studies. It is generally accepted that dopamine agonists are the first line treatment for most patients with prolactinomas. However, patient preference is an important factor in cases where lifelong dopamine treatment is not acceptable and surgical excision is selected.

It is clear that surgery is most useful for small tumours with prolactin level < 200 ng/dl. However even larger tumors have certain subgroups which may benefit from surgery.² The phenomenon of non-responsiveness to bromocriptine is well described, although the biochemical basis remains unexplained.³ The first patient in our group exhibited this indication and operation yielded good results.

Another indication for surgery in both small and large tumours is complete intolerance to dopamine agonists due to gastrointestinal side effects.³ Even though dose reduction can be tried, but it may not always reduce the intractable nausea caused by bromocriptine. Our second case illustrated this problem and transphenoidal surgery resulted in cure.

Yet another indication for surgery was illustrated by our third case. This patient had a large tumour with prolactin levels correspondingly raised to 3800 ng/dl. Although the prolactin level came down with bromocriptine, the visual

field deficits progressed. This phenomenon of cystic change within a prolactinoma has not been well described in the literature. In our view, this constitutes an indication for transphenoidal surgery.

CSF leakage following commencement of bromocriptine therapy is a known complication.⁶ Our fourth patient developed a CSF fistula during the course of bromocriptine treatment. This leak was only amenable to surgical intervention and constitutes another indication for transphenoidal surgery in prolactinomas. Yet another indication was illustrated by our last case in which the patient presented with a macroadenoma and the imaging showed a large sellar mass with erosion of the sellar floor and tumour extension into the sphenoid sinus. This was treated by transphenoidal excision and sellar floor repair as it was felt that bromocriptine treatment would result in CSF leak. This role of prophylactic surgery to prevent CSF leak has not been described previously in the literature.

In conclusion, although size of the tumour and prolactin levels appear to be important determinants of decision making, certain over-riding indications for surgery exist. The authors provide a rationale for trans-sphenoidal microsurgery in these patients as opposed to other forms of management, such as bromocriptine therapy and irradiation. Treatment decisions for prolactinomas need to be individualized for each patient, keeping in view these important variables.

References

1. Colao A, Vitale G, Cappabianca P, Brogianti F, Ciccarelli A, De Rosa M, et al. Outcome of cabergoline treatment in men with prolactinoma: effects of a 24-month treatment on prolactin levels, tumor mass, recovery of pituitary function, and semen analysis. *J Clin Endocrinol Metab* 2004; 89:1704-11.
2. Liu JK, Couldwell WT. Contemporary management of prolactinomas. *Neurosurg Focus* 2004. 15;16:E2
3. Biller BM. Medical therapy for prolactinomas and somatotroph adenomas. *Endocr Pract* 1996;2:333-7
4. Marcou Y, Plowman PN. Stereotactic radiosurgery for pituitary adenomas. *Trends in Endocrinology and Metabolism* 2000. 11:132-7.
5. Kan SF, Kau MM, Low-Tone Ho L, Wang PS. Inhibitory effects of bromocriptine on corticosterone secretion in male rats. *Eur J Pharmacol* 2003; 468:141-9.
6. Ciric I. Long-term management and outcome for pituitary tumors. *Neurosurg Clin N Am* 2003;14:167-71.