

# Effects of Russell's Viper Venom on Blood Coagulation, Platelets and Fibrinolysis

Pages with reference to book, From 81 To 86

Abdur Rehman, A.H. Nagi ( Department of Pathology, Allama Iqbal Medical College, Lahore. )

A. Hayee ( Department of Pathology, K.E. Medical College, Lahore. )

## Abstract

The effects of Russell's viper venom on blood coagulation, platelets and fibrinolysis were studied after injecting MLD, ½ MLD and 1:10 MLD intramuscularly in rabbits. RVV was shown to be a strong coagulant *in vivo* resulting in thrombocytopenia, prolongation of PT, APTT, Thrombin Time and fall of fibrinogen levels. Process of intravascular clotting was very acute in animals receiving MLD and ½MLD doses of venom and there was no change in red blood cell morphology. Raised levels of serum FDPs indicated activation of fibrinolysis. Animals receiving 1:10 MLD showed in addition to disturbance of Coagulation; changes in red blood cells morphology and more prominent activation of fibrinolysis. These findings showed that RVV *in vivo* causes consumption coagulopathy and activated fibrinolytic enzyme system. The results of low doses group resemble more to what have been observed in patients of RV bite (JPMA 33:81, 1983).

## Introduction

There are several poisonous snake bites in Pakistan, but the most prevalent snake bites in rural areas are those by the Russell's viper (*Vipera russelli*), saw scaled viper (*Echis carinatus*) and Cobra (*Naja naja*) (Zafar and Hafiz, 1975). The deaths due to bites by these snakes amount to 10,000 to 12,000 annually in the sub-continent of India and Pakistan (Minton, 1971). Venoms of these snakes contain many active components which act upon the blood constituents and other system of the body. Russell's viper and *Echis carinatus* venoms are characterised predominantly by a coagulant action on blood; whereas Cobra venom has got a neurotoxic effect (Mitrakul, 1979). The effects of Russell's viper venom (RVV) on blood coagulation, platelets and fibrinolytic enzyme system have been studied both in humans and animals (Chugh et al., 1975; Shastry, 1977; Aung-Khin and Zin 1977; Mitrakul, 1979; Gaffney et al., 1979; Chan, 1979; Mahasandana et al., 1979; Trishnananda, 1979; Memon et al., 1980). It has also been observed that Russell's viper bite results in Disseminated Intravascular Coagulation (DIC) with consumption of factor X, V, fibrinogen and platelets (Chugh et al., 1975; Shastry et al., 1977; Mahasandana et al., 1979). This ultimately activates the fibrinolytic system which results into raise levels of fibrinogen degradation products. The changes in haematological parameters vary, depending upon the site of bite, duration of bite and age of the snake (Shastry et al., 1977; Reid and Theekston, 1978). A strong coagulant action of Russell's viper venom (RVV) after injecting high doses (2 MLD to ½ MLD) of the venom into various animals has also been reported (Aung-Khin and Zin 1977; Memon et al., 1980). Mitrakul (1979) demonstrated by performing an *in vitro* study that RVV has got a direct coagulant action and directly activates factor X. He also proved that it has no direct fibrinolytic activity.

The purpose of the present study is to observe the effects of RVV on coagulation and fibrinolytic system using variable doses of the venom (MLD, ½ MLD and 1:10 MLD).

## Material and Methods

**Snake Venom:** Dried lyophilized Russell's viper venom was obtained from National Institute of

Health, Islamabad. The venom was reconstituted in phosphate buffered saline (Ph 7) in such a way that each ml of diluted fluid contained 2.6 mg of crude RVV minimal lethal dose (MLD) for a rabbit weighing 1.5 Kg was found to be 2.6 mg. Further dilution of venom were made with normal saline just before venom injection.

**Animals:** A total of 32 local domestic rabbits were used as experimental animals. The average weight of the animals at the commencement of the experiment was 1.5 Kg.

#### Injection Schedule

**Group-I:** Eight male animals were included in this group. Each of these animals received 1.0 ml of the RVV using the intramuscular route. All these animals died 24 hours after envenomation. Blood samples were taken after one hour, five hours and 24 hours after the envenomation.

**Group-II:** Eight male animals were included in this group. Each of these animals received ½ ml of RVV diluted with 1/2 ml of normal saline using the intramuscular route. All these animals died thirty hours after envenomation. First sample was taken after 4 hours of envenomation and the second after 24 hours.

**Group-III:** Eight male animals were included in this group. Each of these animals received three doses of 1:10 dilution of RVV at the interval of four days. All these animals died within 14 days after the start of the experiment. Four blood samples were taken for haematological tests. First sample at 24 hours, second after 3 days, third after 10 days of first envenomation and fourth sample was taken on 14th day i.e. just before death of animals.

**Group-IV:** Eight male animals were included in this group. Each animal received 1.0 ml of physiological saline using intramuscular route at the time of envenomation of each experimental animal. Blood samples were drawn with each experimental sample to serve as control for coagulation and other tests.

#### Investigations

Platelets were counted by visual method, according to Dacie and Lewis (1968).

Prothrombin time (PT), Activated partial thromboplastin time (APTT) and Thrombin time(TT) were determined using Ortho Brain thromboplastin, Ortho Activated thrombofex reagent and Ortho fibrindex respectively. Fibrinogen titers were also determined using Ortho Fibrindex methods were according to Dacie and Lewis (1968). Fibrinogen Degradation products were estimated using latex agglutination technique (Thrombo-well-cotest of B. Welicome). Peripheral smears for red blood cell morphology were studied after staining with Giemsa stain. Reticulocytes were stained with Brilliant cresyl blue and counted under oil immersion lens; Methods were according to Dacie and Lewis (1968).

## Results

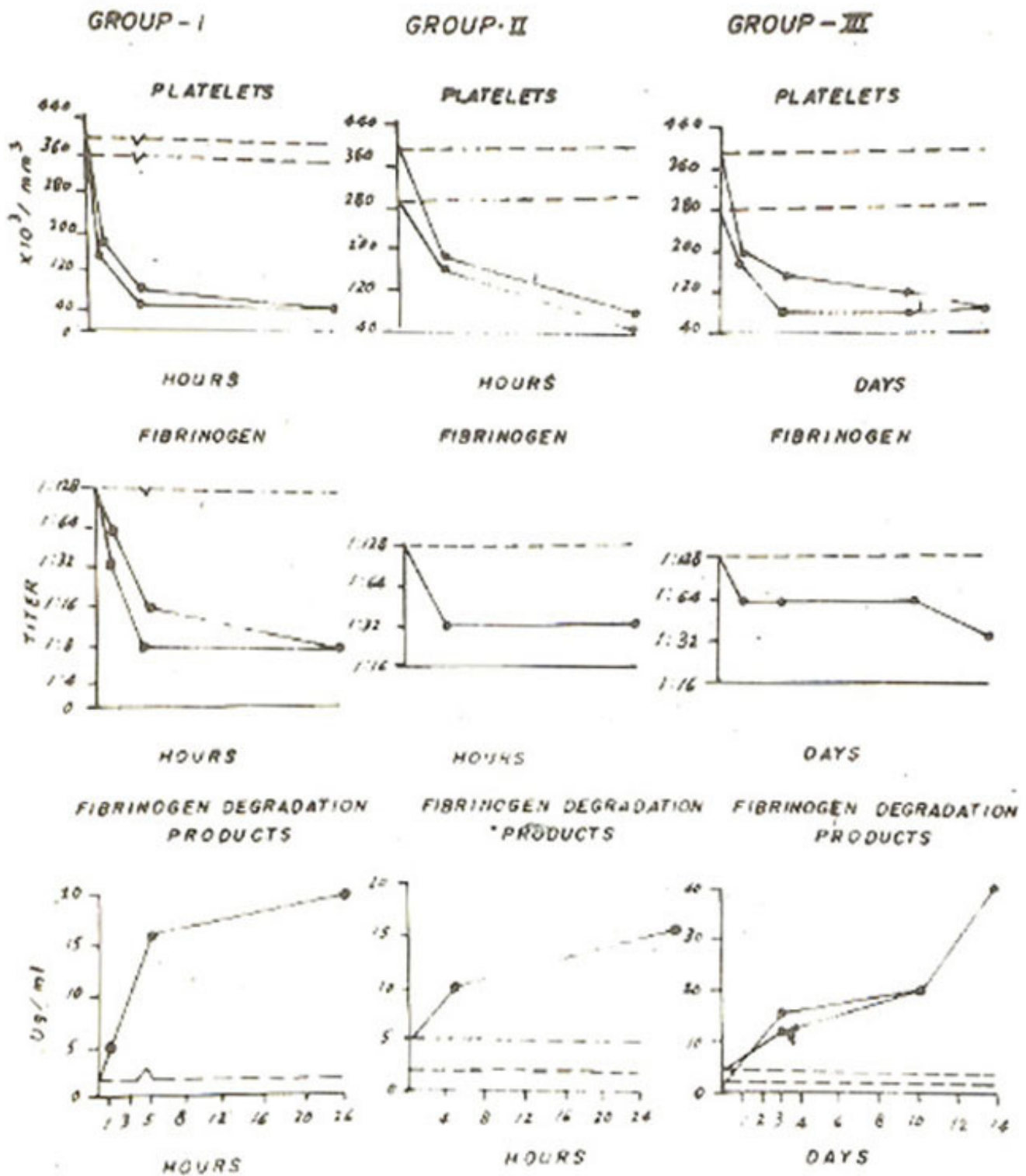
Group I animals receiving single dose of one MLD of RVV showed gross reduction in platelet counts. Maximum fall was observed after 24 hours when the count was  $60 \times 10^3/\text{mm}^3$  whereas in control animals it remained between 360 to  $400 \times 10^3/\text{mm}^3$  (Table I).

**Table I** Haematological Changes in Rabbits given 1 MLd of RVV

	1 Hour	5 Hour	24 Hour	Control
Platelet Count $\times 10^3/\text{mm}^3$	160-190	60-90	60	360-400
RBC Morphology	NN	NN	NN	NN
Reticulocyte Count %	0.2-0.4	0.5	0.5	0.2-2.0
PT Seconds	11-12	12-13	15	9-10
APTT Seconds	24-29	24-30	40	25-28
TT Seconds	12-17	17-18	17-18	6-7
Fibrogen Titre	1:32-1:64	1:8-1:16	1:8	1:128
FDPs ug/ml	5	16	20	2

NN = Normochromic and Normocytic.

There was no change in red blood cell morphology of these animals and reticulocyte count also remained within normal limits. PT, APTT and TT were significantly prolonged. PT was 15 second after 24 hours whereas in control animals it was found to be 9-10 seconds. Similarly APTT was prolonged to 40 seconds. It was 25-28 seconds in control animals. Thrombin time was 6-7 second in control animals and in experimental animals it was prolonged to 17-18 seconds (Fig.2). Fibrinogen levels were markedly reduced and fibrinogen titer in experimental animals of this group fell to 1:8 whereas in control animals it remained at 1:128. Fibrinogen degradation products were increased upto 20 ug/ml whereas in control animals it was 2 ug/ml (Fig.1).



Group-II animals receiving single dose of 1/2MLD of RW showed a marked degree of thrombocytopenia and counts fell to 40-60X10/mm (Table II).

**Table II****Haematological Changes in Rabbits received  
1/2 MLd of Russell's Viper Venom**

	4 Hours	24Hours	Control
Platelet Count x 10 <sup>3</sup> /mm <sup>3</sup>	170-180	40-60	290-390
RBC Morphology	NN	NN	NN
Reticulocyte Count %	0.8-1.0	1-2	0.2-2.0
PT Seconds	13-14	13-15	9-10
APTT Seconds	35-36	35-38	26-27
TT Seconds	10-11	10-12	6-7
Fibrogen Titre	1:32	1:32	1:128
FDPs ug/ml	10	15	2-5

**NN = Normocytic and Normochromic.**

Red blood cell morphology remained normal and the reticulocyte counts were also within normal limits. PT, APTT and TT were prolonged. Prothrombin time in experimental animals was between 13-15 seconds whereas in control animals it was 9-10 seconds. APTT was similarly moderately prolonged and it ranged between 35 and 38 second whereas in control animals it was upto 27 seconds. Thrombin time also significantly prolonged. It was between 10 to 12 seconds in experimental animals and 6 to 7 second in control animals (Fig.2). There was a moderate fall in fibrinogen level and fibrinogen titer was 1:32; whereas in control animals it was 1:128. Fibrinogen degradation products were raised upto 15 ug/mi whereas in control animals the level was below 5 ug/mI (Fig.1).

In animal of Group-III, a progressive fall in platelet count was observed and lowest count was at the end of experiment when it was 80x10<sup>3</sup>/ mm<sup>3</sup> (Table III).



**Table III**

**Haematological Changes in Rabbits given  
1:10 MLd of Russell's Viper Venom**

	24 Hours	3 Days	10 Days	14 Days	Control
Platelet Count x 10 <sup>3</sup> /mm <sup>3</sup>	180-200	80-160	80-110	80	290-390
RBC Morphology	NN	NN	NN	Frag. +	NN
Reticulocyte Count %	1-2	0.5-1.0	0.8-1.0	1-2	0.5-2.0
PT Seconds	10-11	12-14	10-12	14-15	9-10
APTT Seconds	25-29	30-34	28-34	34-39	25-28
TT Seconds	9-10	10-13	10-14	15	6-7
Fibrogen Titre	1:64	1:64	1:64	1:32	1:128
FDPs ug/ml	5	12-16	20	40	2-4

NN = Normochromic and Normocytic.  
Frag. = Fragmentation.

In control animals it remained between 290 to 390 x 10<sup>3</sup>/mm<sup>3</sup>. The reticulocyte counts were within normal limits in both experimental and control animals. Peripheral smears of the experimental animals of this group were normochromic and normocytic in first three samples whereas the last sample showed a moderate degree of schistocytosis, poikilocytosis and anisocytosis (Fig. 3).

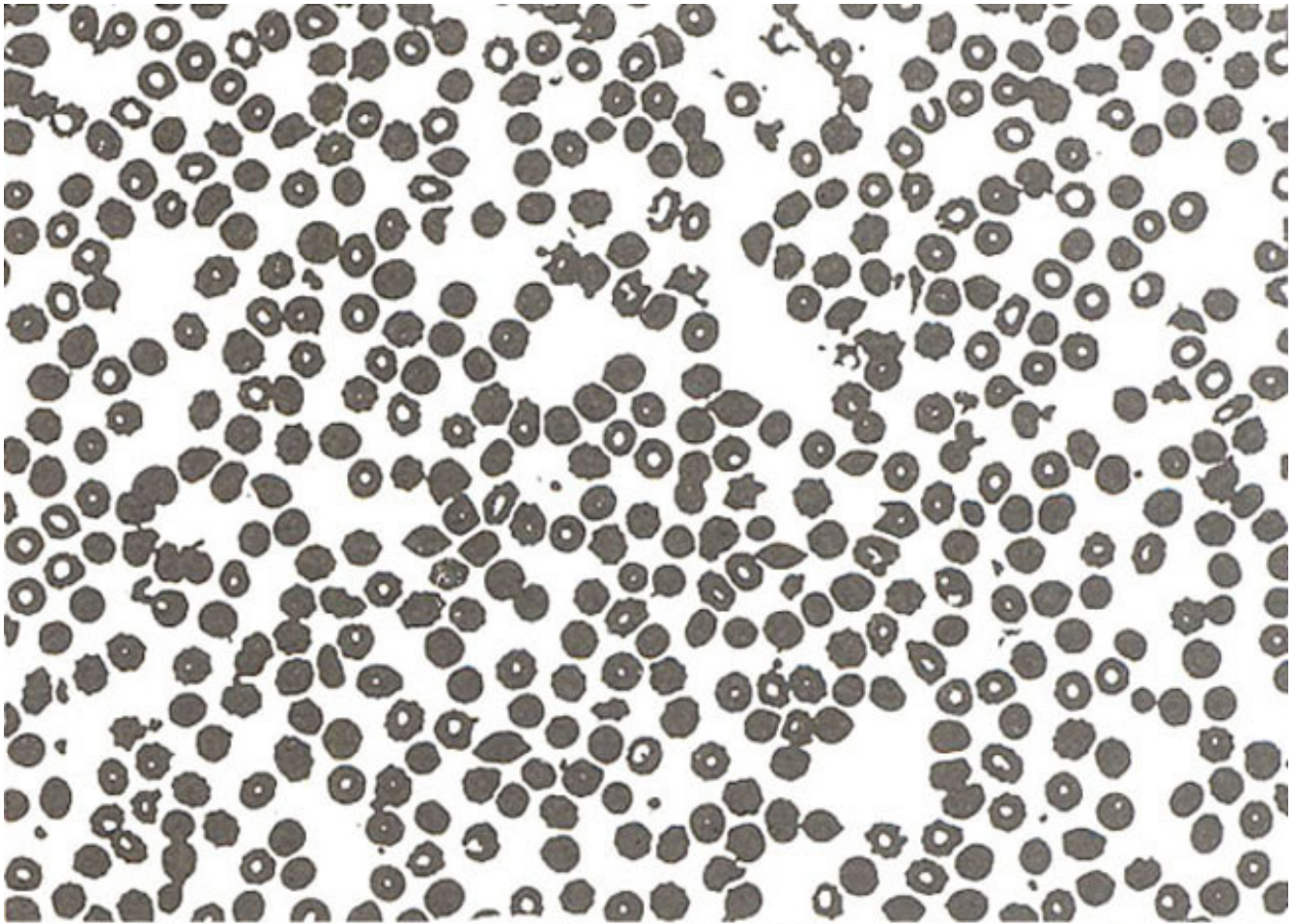


Fig. Photomicrograph of peripheral blood smear of Rabbits showing created and fragmented red blood cells. Giemsa X 480.

Prothrombin time was significantly prolonged only in the samples taken on 14th day when it was between 14-15 seconds. Control animals had PT from 9 to 10 seconds. Similarly APTT was only prolonged in the last sample when it ranged between 34 to 39 seconds whereas it was 25 to 28 seconds in controls. There was a progressive prolongation of Thrombin time and it was maximally prolonged on 14th day when it was 15 seconds. In control animals it was 6-7 seconds (Fig. 2).

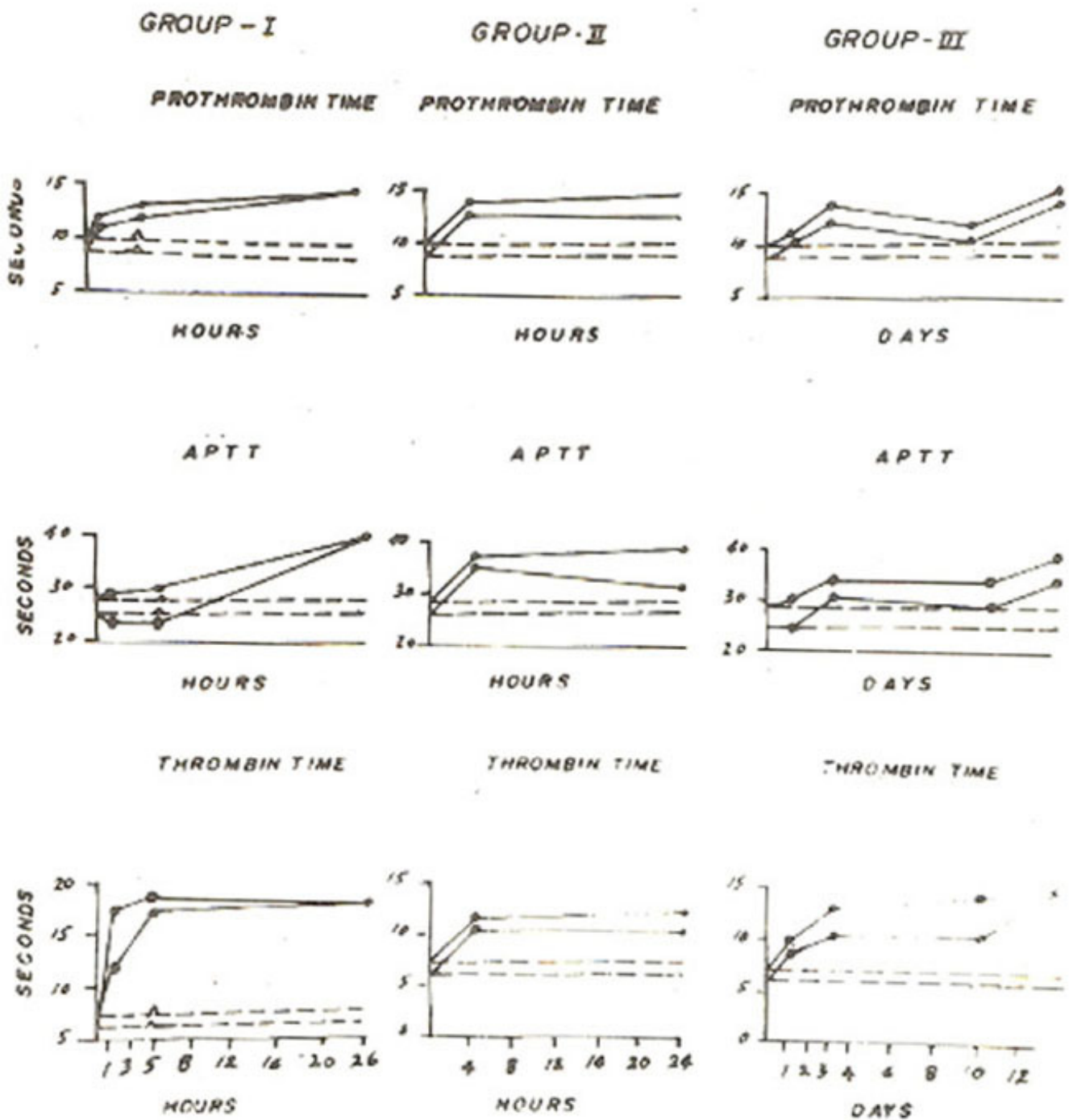


Fig. 2. Photograph showing changes in Prothrombin time, APTT and Thrombin time in Rabbits receiving variable doses of RVV.

Fibrinogen level was significantly low only in the last sample when fibrinogen titer was 1:32 whereas in control animals it was 1:128. There was a progressive rise in serum FDP level and it was 40 ug/ml at the end of experiment. In control animals it remained between 2 to 4 ug/ml (Table III).



## Discussion

Effects of RVV have been studied both in experimental models (Aung-Khin and Zin, 1977; Mitrakul, 1973; Memon et al., 1980) and in human beings following RV bites (Reid et al., 1963; Mitrakul, 1973; Bhargava et al., 1976; Devaraj, 1979; Mahasandana et al., 1979).

In the present study, animals of group I and II (receiving 1 MLD and ½MLD RVV) showed marked degree of thrombocytopenia. Similar results have been reported by Aung-Khin and Zin, (1977) and Memon et al. (1980) in their experimental models on dogs and guinea pigs. Thrombocytopenia has also been observed in patients bitten by the Russell's viper (Reid et al., 1963; Mitrakul, 1979; Mierop, 1980). However intensity of this change varied depending upon the severity and duration of envenomation (Shastri et al., 1977; Mahasandana, et al., 1979; Date and Shastri, 1982).

Red blood cell morphology was normochromic and normocytic in the animals of these two groups. Aung-Khin and Zin (1977) and Memon et al. (1980) did not study red blood cell morphology in their experimental models. In the human victims of RV bite, changes in red blood cell morphology have been reported (Chugh et al., 1975) and these changes depend upon severity of envenomation (Bhargava et al., 1976; Gomperts and Demetriou, 1977; Mahasandana et al., 1979).

Reticulocyte counts were normal in animals of group I and H of our experiment. Reticulocyte count in human patients of RV bite are found to be variable. Chugh et al. (1975) have reported 5-7% of reticulocyte count in only two human subjects of RV bite. In the animals of group I and II, it was also observed that PT, APTT and TT were significantly prolonged and fibrinogen levels were grossly low suggesting the consumption of various clotting factor as a result of intravascular clotting. Similar observations were made by Aung-Khin and Zin (1977) and Memon et al. (1980) in their experimental models. However the changes were more marked in their experiments. Reid et al. (1963) and Mierop and Kitchens (1980) have also reported prolonged PT, APTT and TT after pit viper envenomation. Most of the patients of RV bite studied by Chugh et al. (1975) also had prolongation of PT, APTT and TT and a fall in fibrinogen levels. Extent of changes varied depending upon age of snake, site of bite, health of victim, his weight, age, length between the bite and initiation of treatment (Oehme et al., 1975).

In the envenomated rabbits of group I and II there was a significant rise in serum FDPs as compared to the control animals. Various workers have studied effects of RVV on fibrinolytic system in patients of RV bite (Chugh et al., 1975; Mahasandana et al., 1979). They have reported FDP from 20 to 160 ug/ml in patients of Russell's viper poisoning. Aung-Khin and Zin (1977) also noted activation of fibrinolytic system in their experimental model by observing the shortening of euglobulin clot lysis time.

In the animals of group III there was a significant fall in platelet counts. The reticulocyte counts remained within normal limits. These findings were analogous to the changes in group I and II animals. The examination of peripheral smears at the end of experiment showed changed in red blood cell morphology. The morphological abnormalities were crenated and fragmented red cells, poikilocytosis and anisocytosis. Similar observations have been made in patients of RV bite (Chugh et al., 1975; Bhargava et al., 1976; Warrell et al., 1977; Gomperts and Demetriou, 1977; Mahasandana et al., 1979). PT, APTT and TT were significantly prolonged and fibrinogen levels were lower than control values. Maximum prolongation was seen at the end of experiment. These findings were in accordance with those seen in group I and II animals.

FDPs were raised upto 40 ug/mi in these animals suggesting activation of the fibrinolytic enzyme system. This value was double the level seen in group I and II animals.

The results of present work show that overall picture of consumption coagulopathy is produced after envenomation resulting in low platelet counts, prolongation of PT, APTT and TT and falling of fibrinogen levels. Direct coagulant action of RVV has also been confirmed by Mitrakul (1979) by performing an in vitro study. Change in red blood cell morphology were seen only in group III animals who lived for two weeks and not in Group I and II where the process of intravascular clotting in

patients studied by Chugh et al. (1975).

Raised levels of FDPs indicate that RVV causes activation of fibrinolytic system in vivo whereas Mitrakul (1979) demonstrated by performing in vitro experiment that RVV has got no direct fibrinolytic activity. In the present experiment, it was also observed that the FDP levels were double in animals of group 111 who lived for two weeks after envenomation as compared to group I and II who lived for only 24 hours. The activation of fibrinolytic system in vivo seems to be indirect and is secondary to intravascular clotting.

### Acknowledgement

Our thanks are due to Dr. M. I. Hassan, Dean Post-graduate Medical Institute, Lahore and Maj. Gen. M. I. Burney, Executive Director National Institute of Health, Islamabad for providing us the facilities.

### References

1. Aung-Khin, M.A. and Zin, T.(1977) Effects of Russell's viper venom on Blood Coagulation, Platelets and fibrinolytic enzyme system. *J.Med. Sci. Biol.*, 30:101.
2. Bhargava, R.K., Hakum, A., Shah, P.K., Mathur, S.B. and Ujjwal, J.S. (1976) Disseminated intravascular Coagulation in cases of snake bite (*Echis carinatus*). *J. Assoc. Physicians India.*, 24:67 1-675.
3. Chugh, K.S., Aikat, B.K., Sharma, B.K., Dash, S.C., Methew, M.T. and Das, K.G.(1975) Acute renal failure following snake bite. *Am. J. Trop. Med. Hyg.*, 24:692.
4. Chain, K.E. (1979) Bleeding after Malayan pit viper bites. *Southeast Asian J. Trop. Med. Pub. Health*, 10:276.
5. Date, A. and Shastry, J.C.M. (1982) Renal ultrastructure in acute tubular necrosis following Russell's viper envenomation. *J. Pathol.*, 137:225.
6. Devaraj, T. (1979) Bleeding manifestations in snake bite. *Southeast Asian J. Trop. Med. Public Hlth.*, 10:255.
7. Gaffney, P.J., Marsh, N.A. and Talalak, P. (1979) Snake venoms and haemostasis; some suggested mechanisms of action. *Southeast Asian J. Trop. Med. Public Health*, 10 :25 8.
8. Gomperts, E.D. and Demetriou, D. (1977) Laboratory studies and clinical features in a case of boomslang envenomation. *S. Afr. Med. J.*, 5 1:173.
9. Minton, S.A.Jr. Venom diseases; snake bite, in *Cecil-Loeb textbook of medicine*. Edited by Paul B. Beeson and Walsh McDermott. 13th ed. Philadelphia, Saunders, 1979 pp. 76-80.
10. Mitrakul, C.(1979) Effects of five Thai snake venoms on coagulation, fibrinolysis and platelet aggregation. *Southeast Asian J. Trop. Med. Public Health*, 10:266.
11. Mahasandana, S., Rungruxsirivorn, Y. and Chantarangkul, V.(1979) Clinical patterns of bleeding following Russell's viper and Green pit viper bites in adults: *Southeast Asian J. Trop. Med. Public Health*, 10:25 1.
12. Memon, S.G., Khan, F. and Naeem A. Jafarey. Morphology coagulation studies in guinea pigs following injection of viper russell venom. *JP MA.*, 30:63.
13. Mitrakul, C. (1973) Effects of green Pit Viper (*Trimeresurus erythrurus* and *Trimeresurus popeorum*) venoms on blood coagulation, platelets and fibrinolytic enzyme systems; studies in Vivo and in Vitro. *Am. J. Clin. Pathol.*, 60:654.
14. Mierop, L.H.S. Van and Kitchens, Craig. (1980) Défibrination syndrome following Bites by the Eastern Diamond back Rattlesnake. *J. Fla. Med. Assa.*, 64:21.
15. Oehme, F.W. Toxins of animal origin, in toxicology. By Louis J. Casarett and John Doull. New York, Macmillan, 1975 p.717.

16. Reid, H.A., Thean, P.C. (1963) Prolonged coagulation defects (defibrination syndrome) in Malayan Viper bite. *Lancet*, 621.
17. Reid, H.A. and Theekston, R.D.G. (1978) Changes in coagulation effects by Venoms of *crotalus atrox* as snake age. *Am. J. Trop. Med. Hyg.*, 27:1053.
18. Shastry, J.C.M., Date, A., Carman, R.H. and Johny, K.V. (1977) Renal study of nineteen patients. *Am.J. Trop. Med. Hyg.*, 26:1032.
19. Trishnananda, M. (1979) Incidence, clinical manifestation and general management of snakebites. *Southeast Asian J. Trop. Med. Public Health*, 1:249.
20. Warrell, D.A., Greenwood, B.M., Davidson, N., Ormerod, L.D., Prentice, R.M., Pope, H.M. and Watkins, B.J. (1979) Poisoning by bites of the saw-scaled or carpet viper in Nigeria. *Q.J. Med.*, 181:33-62.