

First Report of Ophthalmomyiasis Externa in Pakistan

Azam Ali¹, Agha Hassan Feroze², Paul Ferrar³, Asad Abbas⁴, Mohammad Asim Beg⁵

Departments of Ophthalmology, Aga Khan University Hospital, Karachi, Pakistan¹, Military Hospital, Rawalpindi, Pakistan², Australian Centre for International Agriculture Research (ACIAR), Canberra, Australia³, Department of Ophthalmology Southeast Texas Medical Associates, Beaumont, Texas, USA⁴, Department of Microbiology, Aga Khan University Hospital, Karachi, Pakistan⁵.

Abstract

Two individuals presented to the Aga Khan University Ophthalmology service with foreign-body sensation, pain and redness in one of their eyes. Slit-lamp biomicroscopy revealed tiny larvae crawling around the conjunctival sac. They were mechanically removed under topical anaesthesia and preserved for light microscopy and photography. Comprehensive liaison was established with the Australian Centre for International Agriculture Research for identification of these larvae. Their morphology characterized them as members of fruit-fly, Oestridae family. At least one of them was positively identified as first instar larva of *Oestrus ovis*. This report describes the first instance of such infections in Southern Pakistan, as concluded after a Medline search.

Case Report

Case 1

A 49 year old woman from rural Sindh, Pakistan, presented to us at the Aga Khan University Ophthalmology service with unilateral redevye, itching and mild photophobia for the preceding two weeks in late summer of 2001. There was no ocular discharge or acute visual impairment. Examination revealed left inferior follicular conjunctivitis with hyperemia and mild visual loss consistent with bilateral moderate nuclear sclerosis. The cornea was clear; with multiple linear corneal epithelial defects appreciated with fluorescein staining. The anterior chamber was deep and quiet. Twelve white, mobile larvae, less than a millimeter in length, were counted on the surfaces of both the fornices. Under topical anaesthesia, all the larvae were removed with fine forceps and preserved in formaldehyde. The symptoms resolved within two weeks after instilling drops of mild steroid and topical antibiotic ointment. The larva, after careful light microscopic examination, remained unidentified, but the overt characteristics of the head of the larva classified it as belonging to the Oestridae family (Figure 1).

Case 2

A 19 year old boy presented with unilateral redevye and foreign body sensation for the previous couple of days. He had spent the preceding week at his family's farms in rural Sindh and distinctly remembered a fly hitting his eye in the fields a day prior to his return. There were no com-

plaints of pain or discharge from the eye or any acute visual impairment. Slit-lamp biomicroscopy revealed a clear cornea without any infiltrates or edema. The anterior chamber was deep and quiet. Four white larvae, about a millimeter in length, were counted moving around the surfaces of both the conjunctival cul-de-sacs and cornea. Under topical anaesthesia, all the larvae were removed with fine forceps and placed in Balanced Salt Solution (BSS). During removal, the larvae seemed to be attached to the conjunctiva at one of their ends. The conjunctiva was then rinsed with saline. No local therapy was applied and symptoms subsided after the procedure. The larvae were observed under light microscope. According to the characteristics of their head and tail, they were identified as first instar (youngest stage) larvae of the sheep and goat nose botfly (*Oestrus ovis*) (Figure 2).

Discussion

Larval identification is aided by the dark mouth claws and the active vermiform movements of its body against the congested and edematous conjunctiva. The only way to be certain of the species of a larva is to have it pupate and grow into an adult fly.

The sheep nasal botfly (*Oestrus ovis*) is the most common cause of ophthalmomyiasis externa.¹ Other members of the Diptera family may also cause ophthalmomyiasis.² Internal ophthalmomyiasis may present as endophthalmitis, complicating a penetrating injury with an intraocular foreign body.³ The adult flies hover in front of the nostrils of animals and squirt a stream of very tiny larvae into them. These larvae develop in the nasopharyngeal cavities and frontal sinuses of livestock. In the occasional case of a human infection, the larvae never fully develop but may cause ophthalmomyiasis externa and/or interna. Vector of the *Oestrus ovis* larvae is most prevalent in warm climates and there is data to suggest increased prevalence of infestation with *O. ovis* in early summer and autumn.⁴

Narayan et al. and Mathai et al. have described similar *O. ovis* cases in India.^{5,6} Other reports from India have also highlighted the potentially vision threatening sequelae of ophthalmomyiasis.⁷ There are several case reports from both the western and eastern hemispheres.⁸⁻¹⁰ English language Medline search for reports of ophthalmomyiasis in Pakistan has been unfruitful.

References

1. Risco JM, Al-Dosari F, Millar I. Sheep nasal botfly (*Oestrus ovis*) larvae infestation of the conjunctiva. *Arch Ophthalmol* 1995;113:529-30.
2. Denion E, Dalens PH, Couppie P, Aznar C, Sainte-Marie D, Carme B, et al. External ophthalmomyiasis caused by *Dermatobia hominis*. A retrospective study of nine cases and a review of the literature. *Acta Ophthalmol Scand* 2004;82:576-84.
3. Gozum N, Kir N, Ovali T. Internal ophthalmomyiasis presenting as endophthalmitis associated with an intraocular foreign body. *Ophthalmic Surg Lasers Imaging* 2003;34:472-4.
4. Amr ZS, Amr BA, Abo-Shehada MN. Ophthalmomyiasis externa caused by *Oestrus ovis* L. in the Ajloun area of Northern Jordan. *Ann Trop Med Parasitol* 1993;87:259-62.
5. Narayan S, Jayaprakash K. Incidence of ocular myiasis due to infection with the larva of *Oestrus ovis* (Oestridae Diptera). *Indian J Ophthalmol* 1991;39:176-8.
6. Mathai E, George JA, Lalitha MK, Raju R. Ophthalmomyiasis externa caused by *Oestrus ovis* - a case report from South India. *Indian J Pathol Microbiol* 1994;37:205-7.
7. Balasubramanya R, Pushker N, Bajaj MS, Rani A. Massive orbital and ocular invasion in ophthalmomyiasis. *Can J Ophthalmol* 2003;38:297-8.
8. Verstryngne K, Foets B. External ophthalmomyiasis - a case report. *Bull Soc Belge Ophthalmol* 2004;294:67-71.
9. Gregory AR, Schatz S, Laubach H. Ophthalmomyiasis caused by the sheep bot-fly *Oestrus ovis* in Northern Iraq. *Optom Vis Sci* 2004;81:586-90.
10. Victor R, Bhargava K. Ophthalmomyiasis in Oman - a case report and comments. *Wilderness Environ Med* 1998;9:32-5.

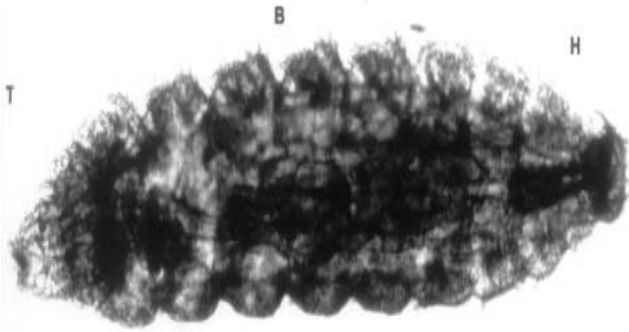


Figure 1.

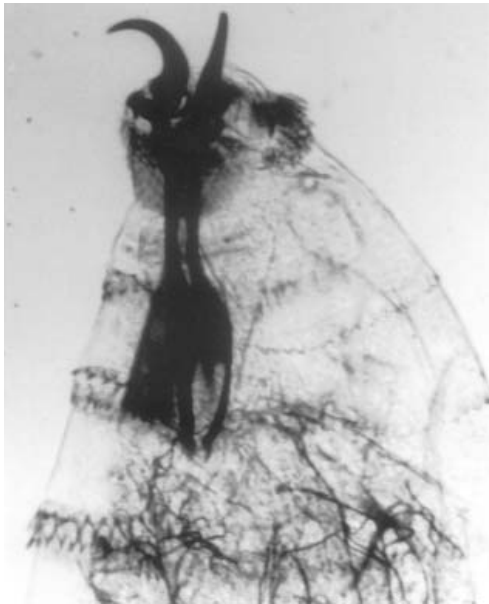


Figure 2.