

GASTRIC LEIOMYOMA AND ITS MANIFESTATIONS IN NIGERIANS A SERIES OF 10 PATIE

Pages with reference to book, From 188 To 191

U. Osime, F. I. Iweze, R. O. Ofoegbu (Dept. of Surgery, University of Benin Teaching Hospital, Benin City, Nigeria.)

Abstract

Important clinical manifestations of gastric leiomyoma are highlighted by its presentation in 10 Nigerian patients treated at the Benin Specialist and University of Benin Teaching Hospitals in Nigeria. Barium meal studies and endoscopy in all the patients showed features suggestive of leiomyoma of the stomach subsequently confirmed at laparotomy and on histological examination. Laparotomy with limited resection of the tumour produced satisfactory results in 8 patients while the 2 postoperative deaths resulted from lack of adequate blood transfusion.

Leiomyoma should be considered as a possible cause of upper gastrointestinal haemorrhage, gastric outlet obstruction and obscure upper abdominal masses in Nigerians. The literature is reviewed (JPMA 36:188, 1986).

INTRODUCTION

Benign tumours of the stomach are rare and arise from either epithelial or mesoblastic tissue. Of the benign gastric tumours derived from mesoblastic tissue, leiomyoma is the commonest. The stomach also is the favourite site of leiomyoma in the gastrointestinal tract. Leiomyoma may remain asymptomatic throughout the life span of a patient and be discovered incidentally at post-mortem examination. It can however produce severe life threatening symptoms. The purpose of this report is to reemphasise the various clinical manifestations which a relatively rare tumour like gastric leiomyoma can produce in Nigerian patients since neither Solanke¹ nor Lewis and Bohrer² mentioned it as a cause of upper gastrointestinal bleeding and gastric outlet obstruction in the West African region.

PATIENTS AND METHODS

From 1973-84 at the Benin Specialist and University of Benin Teaching Hospitals, 10 patients presented with upper gastrointestinal bleeding and gastric outlet, obstruction due to leiomyoma. All the patients had barium meal studies and upper G.I. endoscopy.

RESULTS

There were 6 males and 4 females with ages ranging from 10 to 75 years and a mean of 47.8 years.

TABLE - I
Summary of 10 cases.

No.	Name	Age	Sex	CLINICAL FEATURES						
				Epigastric Pain	Haematemesis and Melaena	Weight Loss	Vomiting	Epigastric Mass	Resection	Result
1.	P.O.	55	M	-	++	-	-	-	+	alive
2.	J.E.	75	M	-	++	-	-	-	+	alive
3.	R.O.	42	M	-	-	+	++	-	+	alive
4.	I.A.	10	M	-	-	++	++	-	+	alive
5.	O.O.	60	M	-	++	-	-	-	+	alive
6.	A.O.	65	F	+	-	+	++	-	+	alive
7.	J.B.	22	F	-	-	+	+	-	+	alive
8.	S.K.	50	F	+	++	-	-	-	+	died
9.	L.A.	55	M	+	++	+	-	-	+	died
10.	M.M.	44	F	+	+	+	-	-	+	alive

Table 1 summarises the clinical presentation of the 10 patients. Haematemesis and melaena were the commonest symptoms present in 6 patients. Gastrointestinal bleeding was often so severe that every patient needed at least two units of blood and one patient received seven units of blood.

Four patients with gastric outlet obstruction presented with recurrent episodes of vomiting associated with weight loss. Epigastric pain was a prominent symptom in four patients. Although barium meal studies and endoscopy suggested leiomyoma as the possible cause of the upper gastrointestinal bleeding or gastric outlet obstruction, other differentials such as lymphoma and carcinoma were entertained.

After adequate resuscitation, all patients underwent laparotomy. In 5 the tumour was located in the fundus; in another 4 in the pyloric antrum and in 1 patient in the body of the stomach. Evidence of active bleeding was seen in 4 patients and old haemorrhage in two patients. All the leiomyomas arising from the pyloric antrum were large to produce gastric outlet obstruction. It was possible in every case to resect adequately the gastric tumour. The histology report on all the specimens confirmed leiomyoma. Two patients died after surgery for want of blood transfusion. Eight patients were followed up for a period of three years in satisfactory condition before they were discharged from the clinic.

DISCUSSION

Benign tumours of the stomach are generally known to be uncommon. Reported incidences in the literature varies from 0.33 per cent³ to 1 per cent⁴ from post-mortem findings. Leiomyoma arising from the mesoblastic tissue is the most common and the favourite site in the gastrointestinal tract is the stomach⁵. Depending on the main direction of growth, gastric leiomyoma may be described as endogastric, intramural or exogastric. Sixty per cent are primarily submucosal and endogastric; 30 per cent subserosal and exogastric and 10 per cent of the "dumb-bell" type growing both endo- and exogastrically. Of 10 patients, 8 were submucosal and endogastric while 2 were subserosal and exogastric.

Although these tumours may occur anywhere in the stomach, the majority occur in the fundus⁶. In our series, 5 patients had leiomyoma in the fundus, 4 in the pyloric antrum and 1 in the body of the stomach.

It is widely accepted that large endogastric leiomyomata tend to produce symptoms but there is no agreement as to what size a benign tumour would attain before it can produce symptoms. Kavlie and White⁷ believed that tumours larger than 3 cm in diameter were always symptomatic and our experience where the average diameter was greater than 5 cm, would tend to support this statement. Crocker⁸ stated that the size of a tumour might indicate its benign or malignant nature. He reported that benign tumours were mostly less than 2 cm in diameter while leiomyosarcomata were often between 4 cm and 10 cm in diameter. Our findings in all ten patients as well as those of Cameron⁹, Din¹⁰ and Rau and Rao¹¹ are not in support of this view.

The incidence of spontaneous gastrointestinal bleeding in gastric leiomyoma is relatively high^{3,12}. It is said that frank severe haematemesis is more likely to be due to leiomyoma than due to carcinoma of the stomach¹³. An important finding in patients with haematemesis due to leiomyoma is their good nutritional status as compared with the cachexia associated with ulcerating carcinoma of the stomach. Four patients in this study were well nourished. It is remarkable that in between their episodes of recurrent haemorrhage, two of our patients were otherwise healthy and that the symptom free period in one patient was seven years. The usual cause of bleeding from gastric leiomyoma has been attributed to central necrosis of the tumour with ulceration of attenuated and stretched mucosa overlying a large tumour which has outgrown its blood supply⁵. Six patients in this study had these pathological findings at laparotomy.

Gastric outlet obstruction due to leiomyoma may be caused by a large wide based antral tumour encroaching on the pylorus or to a small pedunculated tumour prolapsing intermittently through the pylorus. As a result of persistent vomiting, the patient may become undernourished and dehydrated giving rise to a suspicion of carcinoma or tuberculosis. Both mechanisms of gastric outlet obstruction occurred in four of our patients. Elgood in 1925¹⁴ described gastroduodenal intussusception or gastric volvulus as another mechanism of gastric outlet obstruction due to leiomyoma. In these cases, there is a real danger of early infarction of the stomach wall with risk of perforation and peritonitis.

In an environment where gastric and duodenal ulcers are common, it is usual to attribute the symptoms of dyspepsia, vomiting, haematemesis and melaena to peptic ulcer or to carcinoma of the stomach^{1,2}. Nevertheless, it is obviously important to recognise that gastric leiomyoma can produce similar symptoms and being amenable to surgery carries a good prognosis following resection.

In our experience, barium meal examination and endoscopy are most valuable in reaching an early diagnosis of gastric leiomyoma (Figure 1 and 2).



Figure 1 Barium Meal film of case 2 showing a roundish filling defect in the mid-lesser curve of the stomach which at laparotomy was a leiomyoma.

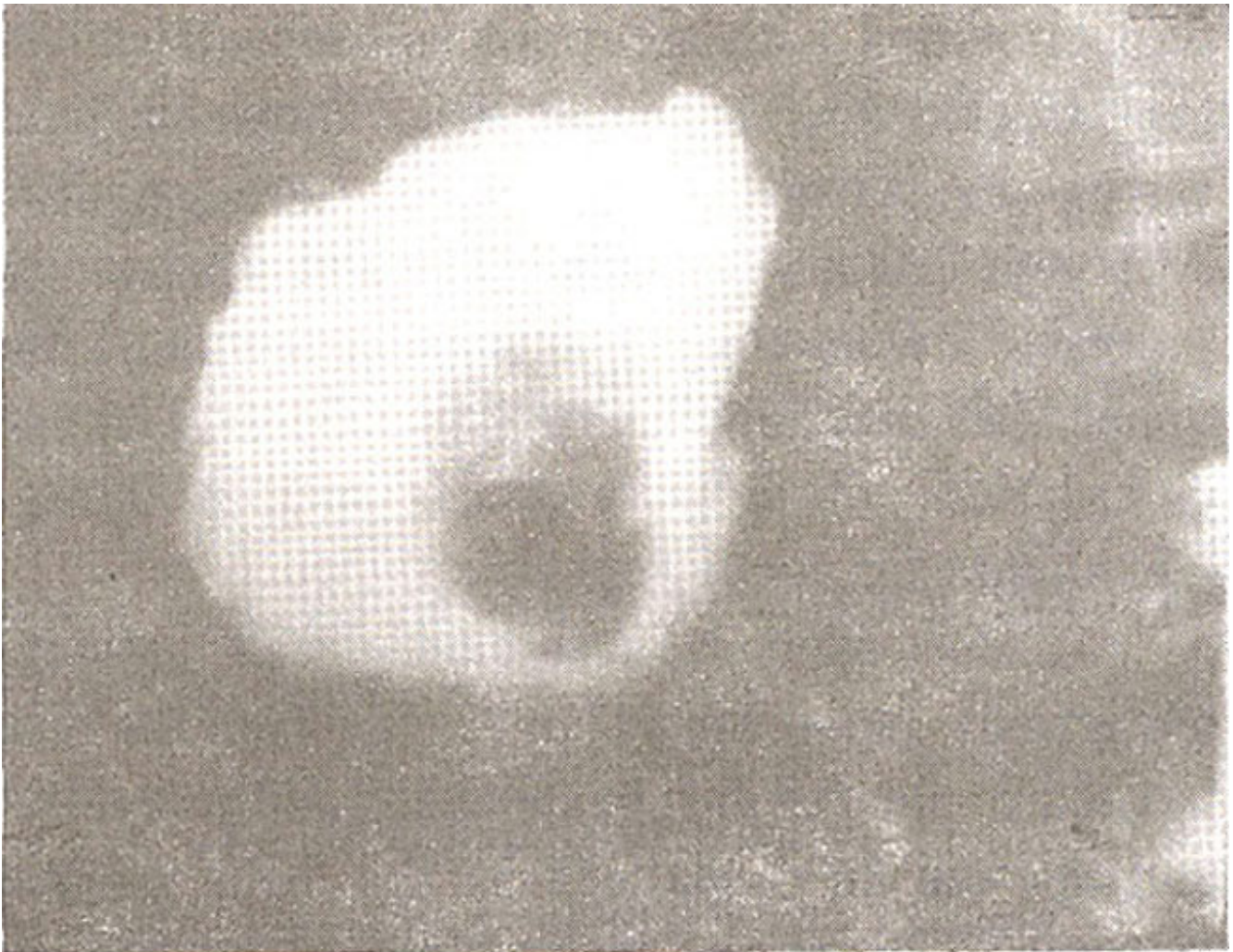


Figure 2. Barium meal film showing a filling defect in the fundus of the stomach, a common position for leiomyoma.

The treatment of gastric leiomyoma is by complete surgical excision. Even small tumours should be excised for histological examination to exclude malignancy. The tumour with the overlying mucosa should be removed and a wedge excision of the neoplastic area performed. When the tumour is in the pyloric region or causing gastric outlet obstruction, a distal partial gastrectomy may be carried out. The short and long term results of surgical excision in all reported series have been eminently satisfactory. Eight of our patients are alive and the two post-operative deaths resulted from lack of adequate blood transfusion. Where complete surgical excision has been achieved, there has been no reported case of tumour recurrence. Incomplete excision, however, carries the risk of local recurrence of the tumour.

REFERENCES

1. Solanke, T.F. Gastrointestinal bleeding. *W. Afr. Med. J.*, 1973;22:78.
2. Lewis, E.A. and Bohrer, S.P. Gastric outlet obstruction in adults in Ibadan, Nigeria, *W. Afr. Med. J.*, 1970; 19:325.

3. Thompson, H.L. and Oyster, J.M. Neoplasm of the stomach; other than carcinoma. *Gastroenterology*, 1950; 15:185.
4. Plachta, A. and Speer, F.D. Polyps and their relationship to carcinoma of the stomach, review of literature and report of 65 cases. *Gastric Am. J. Gastroenterol.*, 1957; 28 :160
5. Oberhelman, H.A., Condon, J.B. and Guzauskas, A.C. Leiomyoma of the gastrointestinal tracts. *Surg. Clin. N.A.*, 1952; 32:111.
6. Welch, J.P. Smooth muscle tumours of the stomach. *Am. J. Surg.*, 1975; 130:279.
7. Kavlie, H. and White, T.T. Leiomyomas of the upper gastrointestinal tract. *Surgery*, 1972; 71:842.
8. Crocker, D.W. Smooth muscle tumours of the stomach. *Ann. Surg.*, 1969; 170:239.
9. Cameron, C.T. Gastric intussusception from Leiomyoma. *J. R. Coil. Surg. Edjn.*, 1973;18:249.
10. Din, N.A. Aspirin induced haemorrhage in gastric leiomyoma. *J. R. Coil. Surg. Edin.*, 1973; 18: 246.
11. Venkat Rau, J.B. and Prasad Rao, K.R. Gastrointestinal leiomyomas. *Am. J. Gastroenterol.*, 1975; 63:249.
12. Skandalakis, J.E., Gray, S.W. Shepherd, D, Bourne, G.H. Smooth muscle tumours of the alimentary tract: Leiomyomas and leiomyosarcomas; a review of 2525 cases. Springfield Illinois, Thomas, 1962.
13. Ives, L.A. Neurinoma of the stomach. *Br. J. Surg.*, 1950; 37:477.
14. Elgood, J. Gastroduodenal intussusception caused by large leiomyoma of the stomach. *Br. J. Surg.*, 1951; 38: 388.