

AMOEBIC ABSCESS OF SPLEEN

Pages with reference to book, From 93 To 95

Abdul Waheed, M.S. Saleemi, Raja Mohammad Ashraf (South Surgical Unit, Mayo Hospital, King Edward Medical College, Lahore.)

INTRODUCTION

Amoebic abscess of liver is commonly seen in the tropics or in countries where hygienic standards are low, but an amoebic abscess of the spleen is a rare entity. The present case-report describes the difficulties encountered in the diagnosis of a case of amoebic abscess of the spleen.

Case

A 16 year old male was admitted in the North Medical Ward through Emergency with complaints of pain in the left hypochondrium (LHC) and intermittent fever of 4 months duration.

Pain was mild to moderate in intensity, localized to the LHC and not related to meals or posture. Fever was intermittent in nature and was present for 4 months. The patient also described a mass in LHC which had progressively increased over 4 months. He also complained of a nonproductive cough, weight loss and generalized weakness.

On examination the pulse rate was 96/mm, blood pressure was 130/80 mm Hg, and temperature was 100.0 F. Pallor was present, but there was no jaundice, lymphadenopathy or clubbing. Abdominal examination revealed a fullness in the LHC, left lumbar region and the right hypochondrium. Liver was 4 fingers and spleen 6 fingers enlarged and tender. The splenic notch was not palpable.

Examination of the chest revealed diminished breath sounds over the left middle and lower zones. Percussion note was dull over the same zones. Subsequent radiological examination of the chest confirmed the presence of left sided pleural effusion (Figure 1).

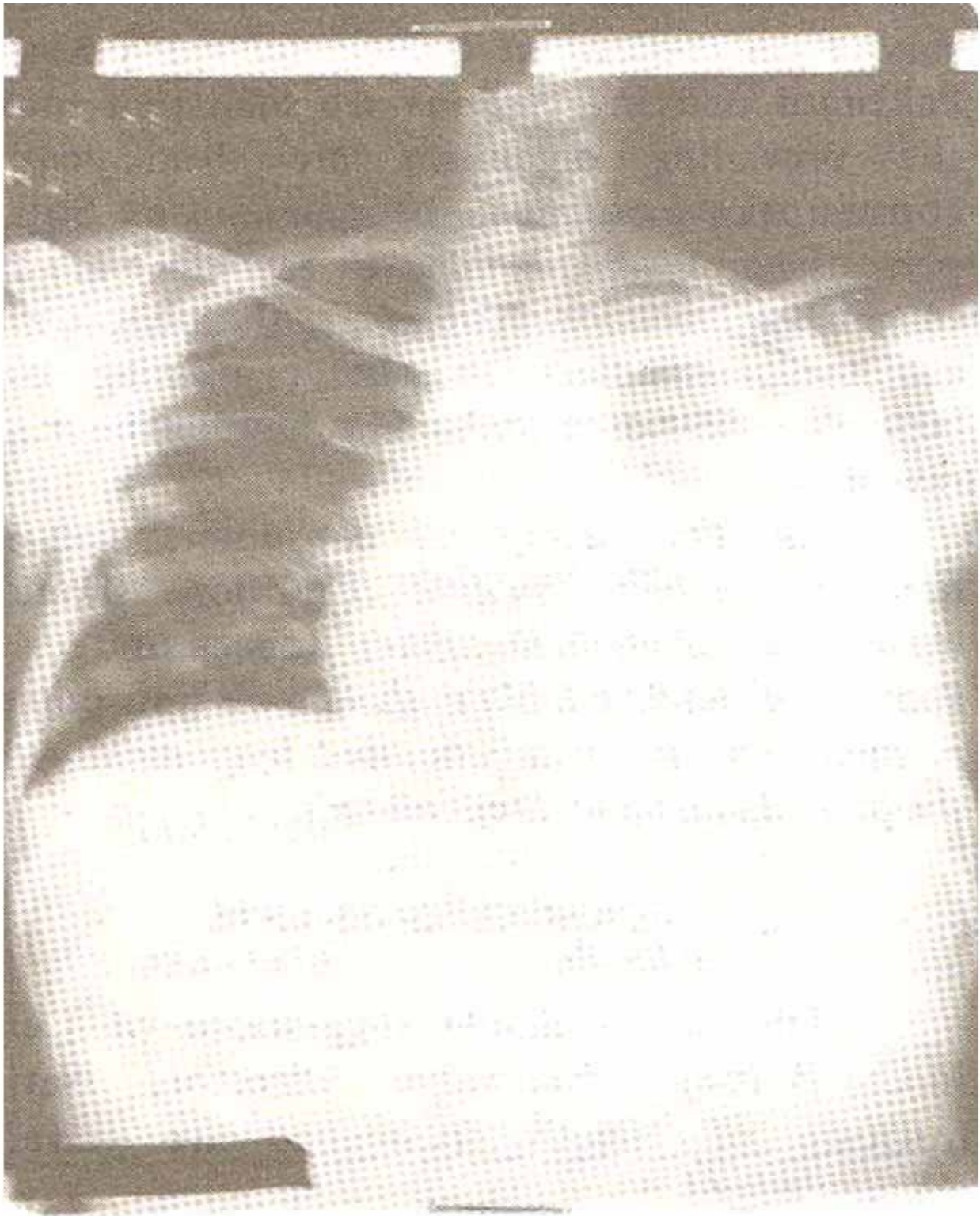


Figure 1. X-ray chest showing left side pleural effusion.

Investigations showed a persistently raised ESR, a negative Mantoux Test, a negative smear of sputum for AFB. Stool examination showed no amoeba, cyst or ova. Casoni's Test was negative. Bone marrow aspirate showed moderately active normoblastic erythropoiesis. Liver scan showed an enlarged liver

while splenic scan showed an enlarged spleen with a cystic area full of thick fluid with debris. Ultrasound examination showed an echogenic area in the spleen. A probable diagnosis of an abscess or a hematoma of the spleen was made.

While the investigations were being carried out, a provisional diagnosis of T.B. pleural effusion with hepatosplenomegaly was made and the patient was treated with anti-tuberculous drugs for 5 days. A pleural tap done thereafter, aspirated 250cc of thick, brownish, foul smelling fluid which showed a large number of mononuclear cells on microscopy. On culture, it showed a profuse growth of E. Coli sensitive to most of the antibiotics. Patient was treated with Cap. Ampicillin 500mg'6 hourly and Tab. Flagyl 800mg TDS. Pleural aspirate was negative for AFB. General condition of the patient improved and spleen reduced in size, though fever with spikes and dyspnoea persisted. Pleural aspiration was repeated on 11.4. 1985 and 340cc of thick brownish fluid was aspirated which gave a moderate growth of F. Coli on culture. Patient was shifted to the Male South Surgical Ward.

As his hemoglobin was 7.7 gm% blood was transfused following which his general condition improved.

Needle aspiration of the spleen was carried out and 500cc of typical thick chocolate coloured fluid was aspirated. On culture it showed profuse growth of E. Coli and proteus but no amoeba were seen. Patient was treated with Tab. Flagyl in a dose of 500 mg TDS. The fever settled in a few days, but dyspnoea increased due to increase in pleural effusion. Pleural aspiration was done again on 17.5.1985 and 150cc of thick brownish fluid similar to that aspirated from the splenic abscess was aspirated. An Exploratory Laparotomy revealed a large abscess in the spleen (Figure 2)

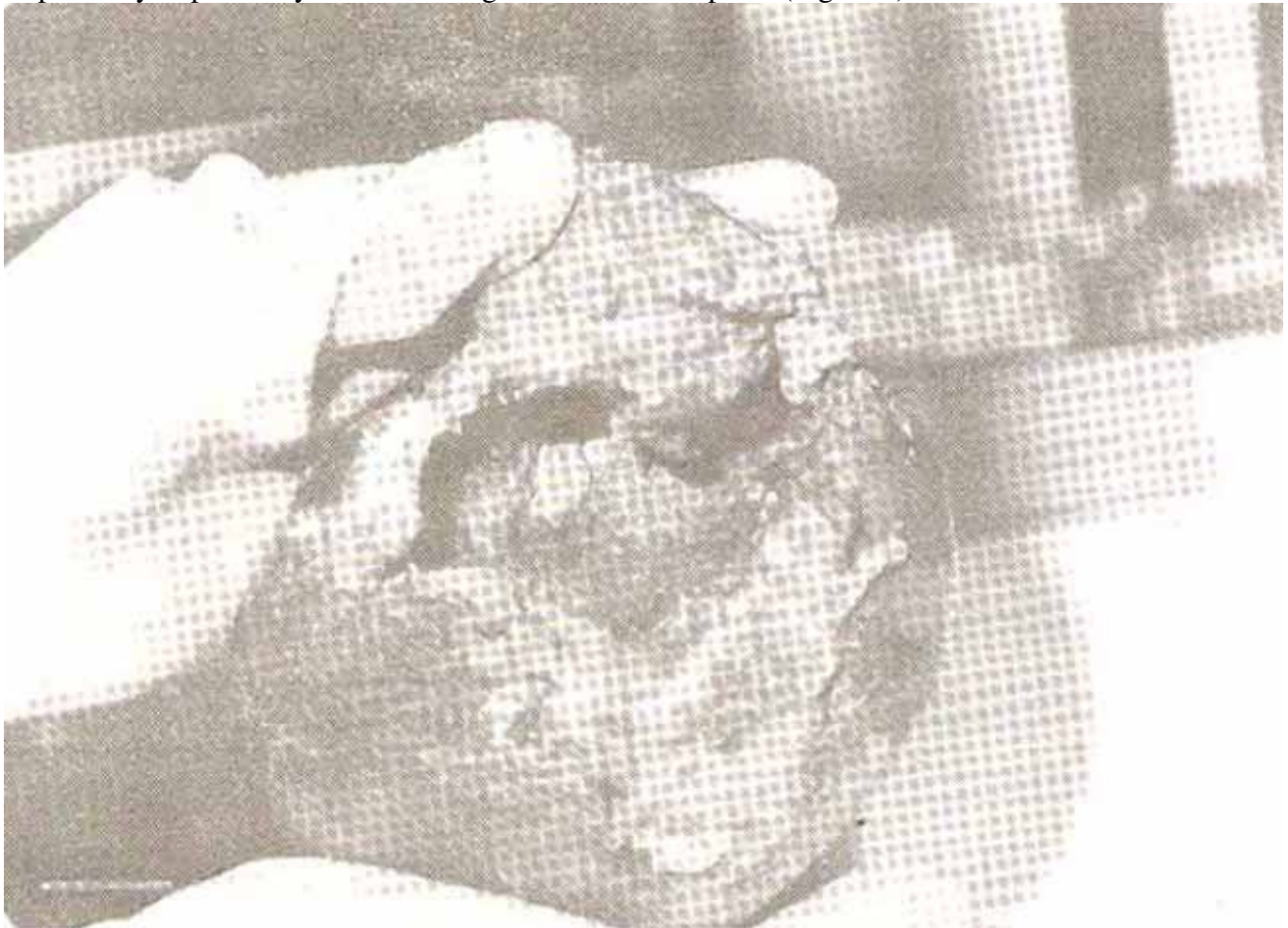


Figure 2. Large abscess in the spleen.

and a perforation in the diaphragm. Splenectomy was done and the tear in diaphragm was repaired. The left pleural cavity was drained by intubation and a corrugated rubber drain was retained in the splenic fossa.

A smear of the wall of the abscess studied by two different laboratories showed *Entamoeba histolytica*. Patient was treated with Inj. Penicillin 2 mega units I/V 6 hourly, Inj. Gentamycin 40 mg IM 8 hourly and Inj. Flagyl 500mg I/V 6 hourly.

Patient developed marked respiratory distress and a tracheostomy was done, but his respiratory distress did not improve and he followed a downhill course, went into respiratory arrest and could not be revived.

DISCUSSION

Splenic abscess is an uncommon cause of abdominal sepsis and is seen in patients with sickle cell disease, immune deficiency, major trauma, acute leukemia, septicemia and splenic vein thrombosis in heroin addicts.^{1,2} In 2/3 patients with acute leukemia, splenic abscess is a terminal event. Candidial splenic abscess is also seen in some patients. Non typhoid salmonellosis can cause splenic abscess as a result of bacteremia and rupture into the pleural cavity causing empyema.³

In our patient *Entamoeba Histolytica* caused the splenic abscess. The entry of amoeba into the spleen can be explained by a reversal of flow into splenic vein possibly due to cirrhosis of liver and portal hypertension. Once in splenic parenchyma, amoeba causes proteolytic destruction and abscess formation.

Difficulty and delay in diagnosis and treatment of the case is obvious and was due to the fact that a splenic abscess is uncommon.^{4,5}

REFERENCES

1. Phllpott, G.W. and Ballinger, W.F. The Spleen in text book of surgery; the biological basis of modern surgical practice. Edited by David C. Sabiston Jr. 12th ed. Philadelphia, Saunders, 1981; p. 1324.
2. Page, C.P., Colttman, C.A., Robertson, H.D. and Nelson, E.A. Candidial abscess of the spleen in patients with acute leukemia. *Surg. Gynaecol. Obstet.*, 1980; 151:604.
3. Buscaglia, A.J. Empyema due to splenic abscess with *Salmonella newport*. *JAMA.*, 1978; 240: 1990.
4. Gadacz, T. and Way, L.W. Changing clinical spectrum of splenic abscess. *Am. J. Surg.*, 1984; 148: 182.
5. Gold stone, J. Spleen, in current surgical diagnosis and treatment. Edited by Lawrence W. Way. 6th ed. Los Atlas, California, Lange, 1983, p. 568.