

# HYDATID CYST IN THE GROIN A CASE REPORT

Pages with reference to book, From 245 To 245

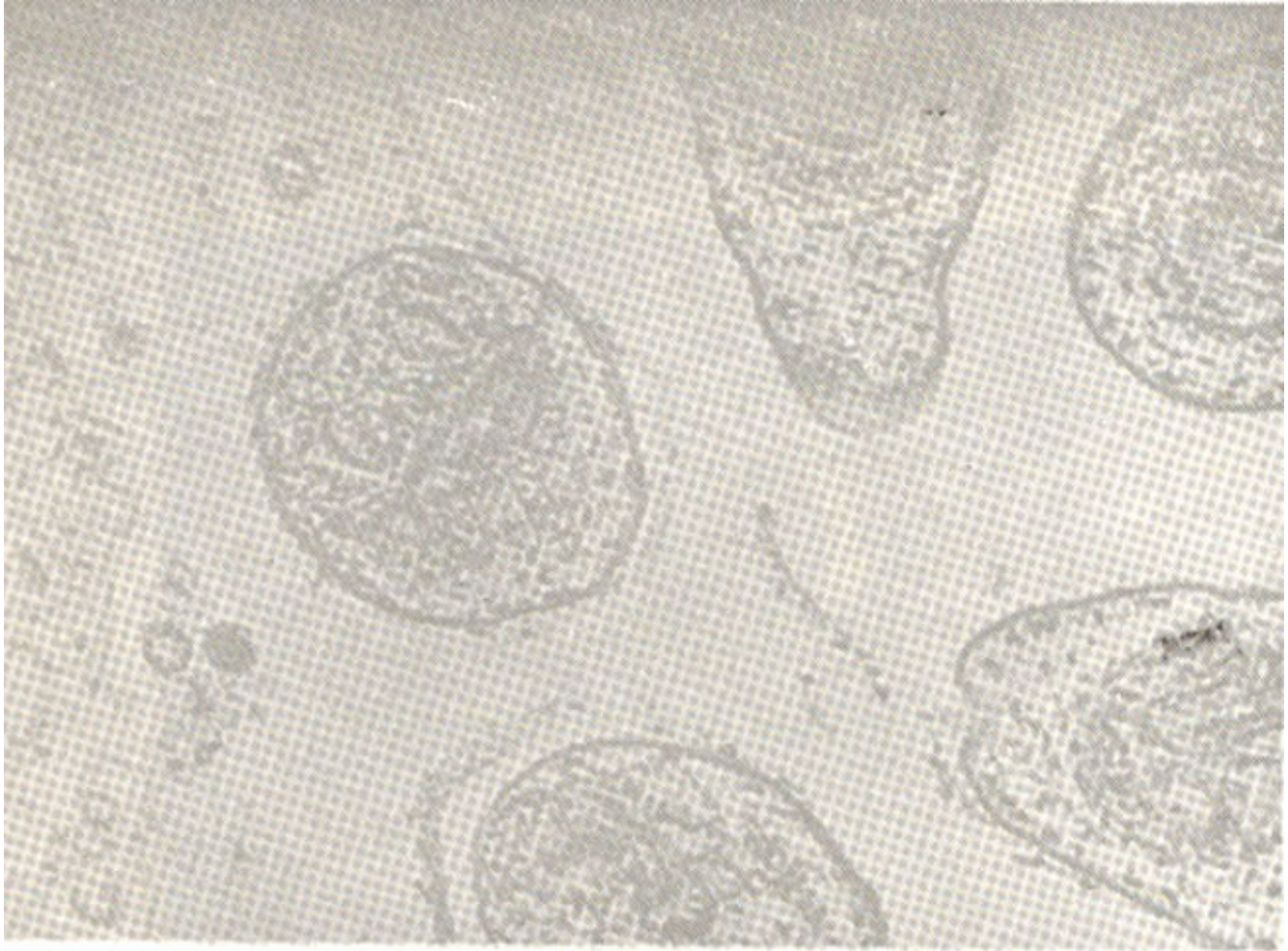
Asif Zafar ( Department of Surgery, Rawalpindi Medical College, Rawalpindi. )

Shehzad Latif ( Department of Surgery, DHQ Hospital, Rawalpindi. )

## CASE REPORT

A 28 years female presented with painless swelling in the left inguinal region. The clinical findings were a nontender, firm but mobile solitary cystic swelling in the left inguinal region of 10 cm x 6 cm in size. It caused no problems in sitting or walking. Regional and other lymph nodes were not palpable. The cyst was aspirated to reduce its size. The aspirate was clear pale yellow fluid. The cyst was then removed en masse under local anaesthesia. The gross appearance was a thick walled glistening unilocular cystic mass which on histology was found to be a hydatid cyst.

The cyst recurred at the same site, one month later. Abdominal ultrasound, liver scan and chest x-ray were normal and Casoni's test was positive. The cyst was removed under general anaesthesia with due care to avoid puncture and perforation. Complete excision was done. Histopathology once again was hydatid cyst with



live scoleces in it (Figure).

## **ACKNOWLEDGEMENTS**

We are grateful to the Armed Forces Institute of Pathology, specially Brigadier Manzoor and Colonel Ayub for extending all help to us.