

MEGA DOSES OF METHOTREXATE IN THE TREATMENT OF OSTEOSARCOMA

Pages with reference to book, From 248 To 251

M. Perwaiz Iqbal (Departments of Biochemistry, The Aga Khan University Medical College, Karachi.)
Imtiaz A. Malik (Departments of Medicine, The Aga Khan University Medical College, Karachi.)

High-dose-methotrexate therapy with eirovorum factor (leucovorin) rescue has been widely used in the treatment of many solid tumors and lymphomas. This therapy plays an important role in the management of osteosarcoma¹⁻⁷. The rationale behind using high doses of this drug is to achieve high plasma levels (10 to 10⁻⁵ M) for prolonged periods⁸. This probably facilitates the passive entry of methotrexate (MTX) into the tumor cells having defective transport systems⁹. It has also been suggested that increased intracellular levels of free MTX can overcome drug resistance caused by increased levels of dihydrofolate reductase (DHFR) or presence of a DHFR having low affinity for MTX¹⁰. Moreover, such high doses facilitate MTX polyglutamate formation within the tumor cells and hence prolong its cytotoxic effects¹¹. On these basis, such therapy has been advocated for base in osteosarcoma^{1,2,6,7}. The treatment has been shown to reduce regression of primary and metastatic tumors¹²⁻¹⁶ and response rates seem to increase with more frequent and intense treatments^{14,17}. More recently, some workers have used 12 g/m² of MTX which results in improved response rate and survival¹⁸. Previously we have reported the treatment of two cases of metastatic osteosarcoma with high doses (5 g/m²) of MTX¹⁹. Mega doses, however, have not been attempted in Pakistan due to its prohibitive cost and toxicity. We recently treated a case of osteosarcoma with 12 g/m² of MTX on four different occasions. We monitored the MTX levels in the plasma as well as RBCs and evaluated the toxicity and clinical outcome of this patient.

CASE REPORT

A twenty six year old male was admitted to the Aga Khan University Hospital in November, 1988 with a history of right knee pain and later swelling of the lower end of femur. Radiologic examination revealed an osteolytic lesion in the lower end of femur. A bone biopsy done in late October showed a tumour composed of neoplastic cells with pleomorphic, hyperchromatic nuclei, osteoid formation, foci of calcification, scattered giant cells and areas of necrosis. He was diagnosed to have osteosarcoma. His physical examination, except for above knee swelling, was normal. Metastatic work-up including ultrasound liver and CT scan of chest was normal. Laboratory studies including CBC, electrolytes, BUN and creatinine were normal. He was started on Rosen's T-10 protocol²⁰. Prior to chemotherapy, patient received hydration and alkalization of urine with NaHCO₃ to keep the urine pH > 7.0. Chemotherapy was carried out as shown in Figure 1.

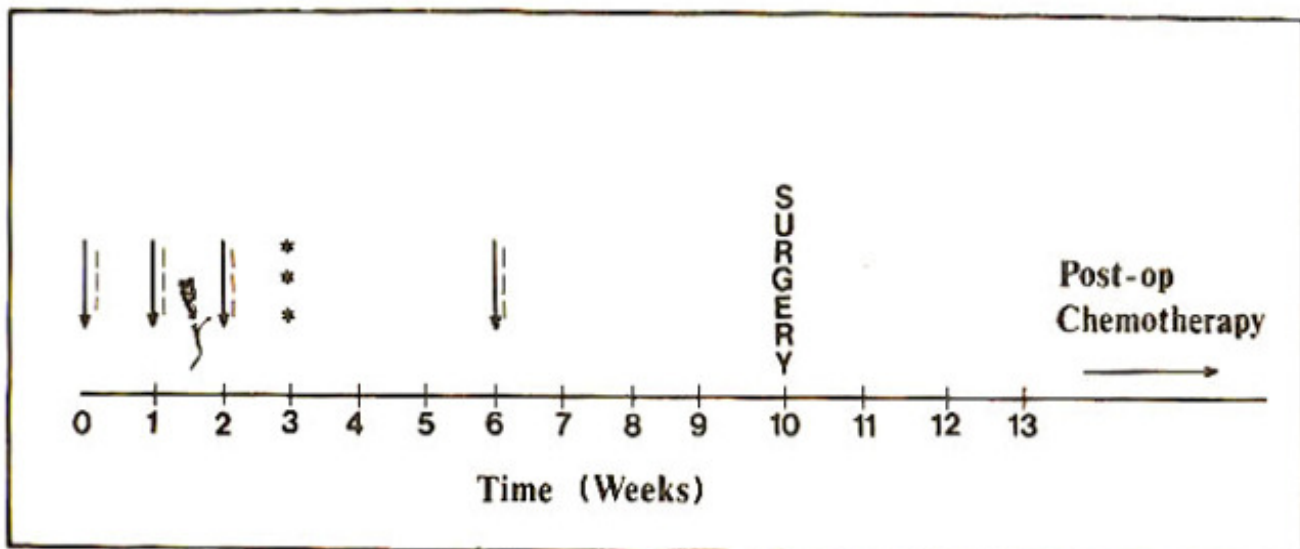


Figure 1. Chemotherapy regimen used. Arrows denote mega dose MTX 12 g/m^2 over six hours; Broken bars, leucovorin rescue 15 mg/m^2 every six hours until MTX levels $< 1.0 \times 10^{-7} \text{ M}$; Triple asterisks, administration of cyclophosphamide 600 mg/m^2 , bleomycin 15 mg/m^2 , and dactinomycin 0.6 mg/m^2 per day for two consecutive days. Post-operatively patient received cisplatin 100 mg/m^2 day one and adriamycin 30 mg/m^2 for 2 days every 3 weeks.

MTX was administered as a continuous infusion over six hours. Blood sampling was done at regular intervals to monitor MTX levels. Leucovorin rescue at 15 mg/m^2 was started 24-hours after MTX infusion every six hours until MTX level fell to $< 1.0 \times 10^{-7} \text{ M}$. MTX concentration in plasma and erythrocytes was determined by a very sensitive radioassay²¹. Erythrocytes were first washed with saline and then hemolysed in three volumes of deionized water and the proteins precipitated by placing the hemolysate in a boiling water bath for 5 minutes. This extraction procedure of the drug from erythrocytes has been described elsewhere²². Profiles of MTX levels from plasma and erythrocytes after a six hour infusion of MTX are shown in Figures 2 and 3.

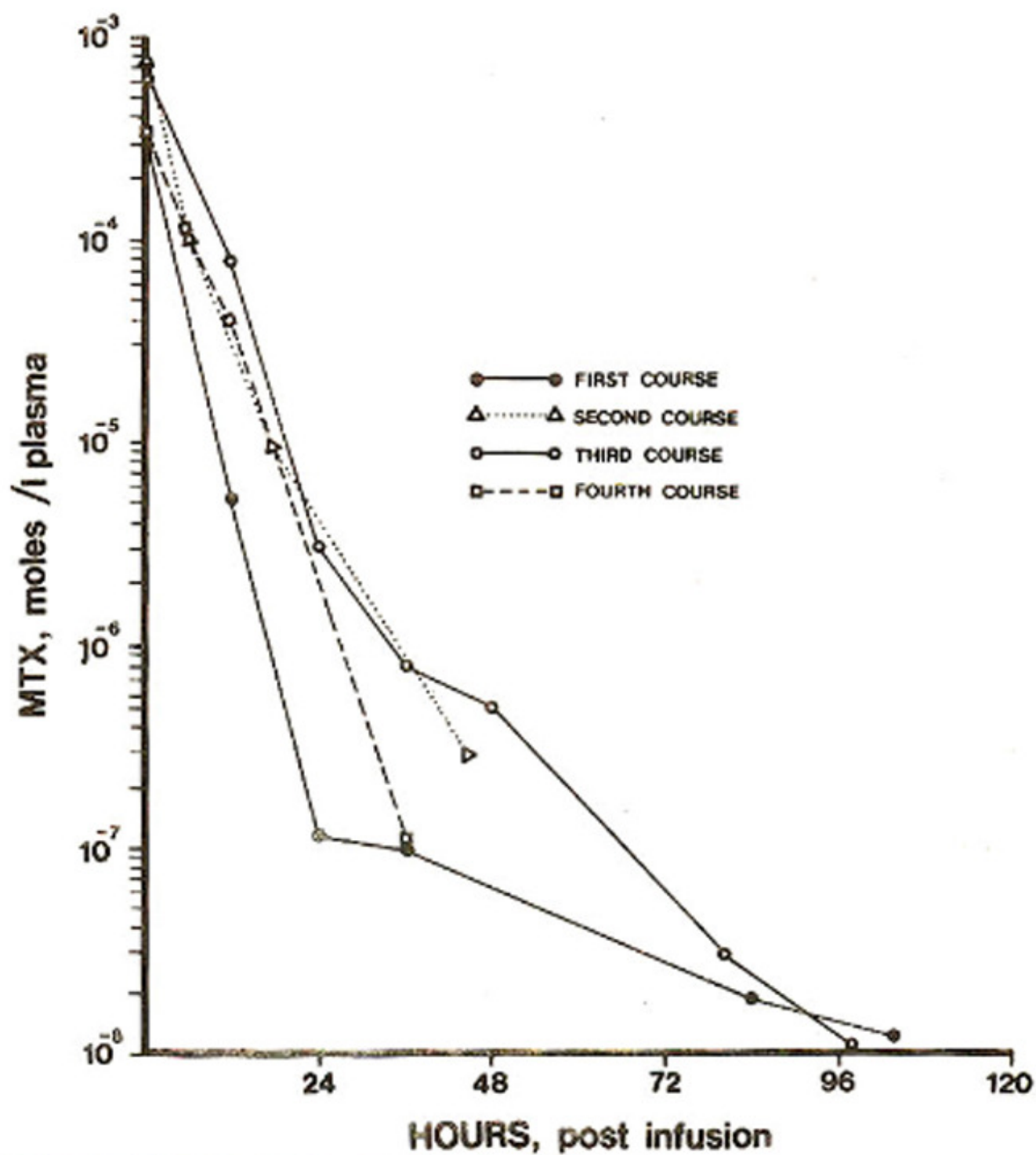


Figure 2. Plasma MTX levels in osteosarcoma following 6-hour infusions (4 courses) with 12 g/m^2 of the drug.

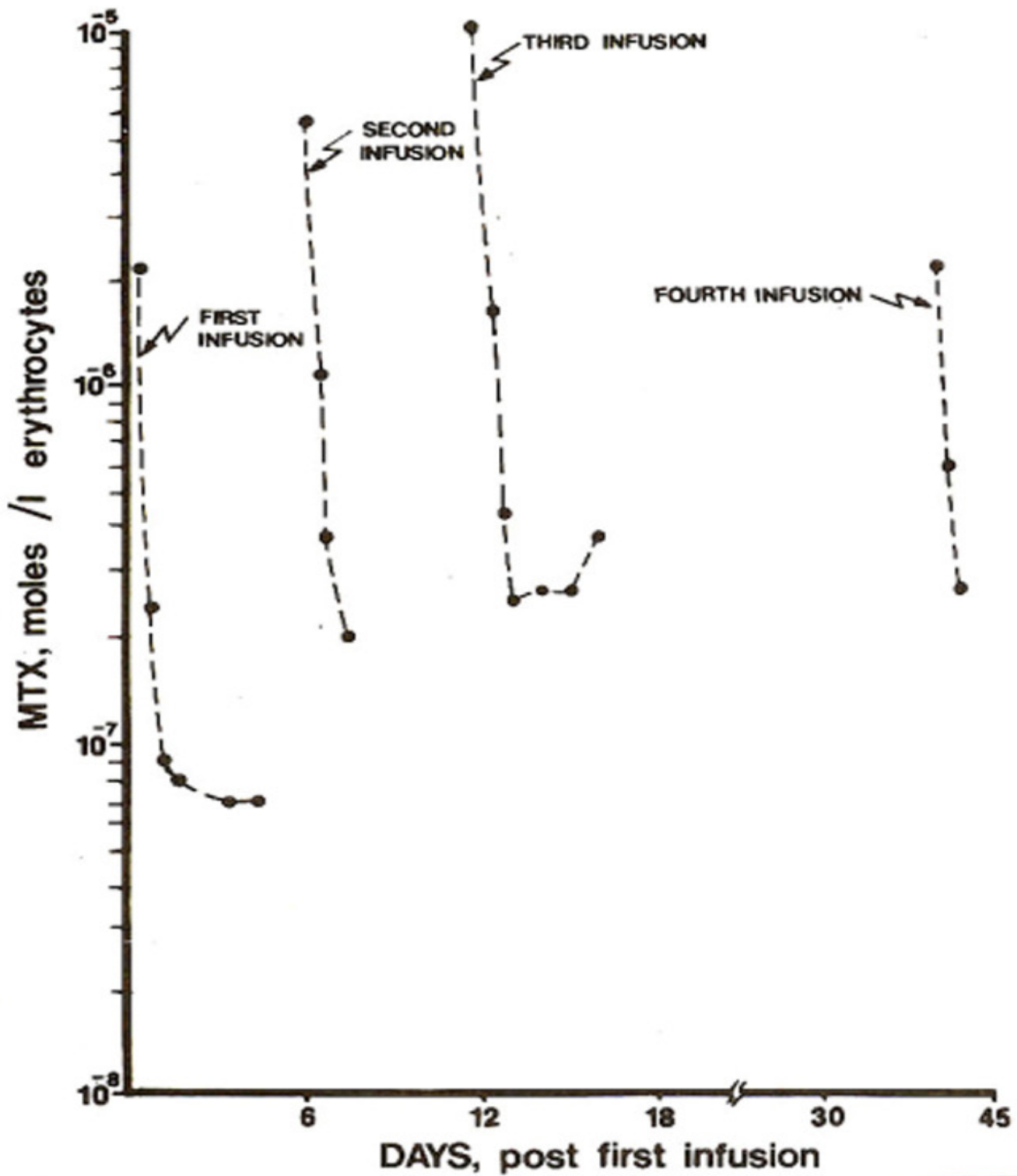


Figure 3. Erythrocyte MTX profile during the four courses with mega dose of the drug (12 mg/m^2).

Figure 2 shows that following all the four courses of MTX, the plasma levels of MTX during the first 12 hours following the completion of infusion remained within the range of 10^{-4} to 10^{-5} M. This is the concentration that has been shown to facilitate passive diffusion of the drug into the tumor cells or

entry of the drug by a low affinity, high capacity carrier system⁹. Erythrocytes MTX profile during these 4 courses is shown in Figure 3. In all the infusions, there was substantial entry of the drug ($> 10^4$ M) into erythrocytes probably by simple diffusion as well as by carrier system²². However, subsequent to the first infusion, MTX levels in erythrocytes were found to be greater than 10^{-7} M at various time intervals. These higher levels are partly contributed by newly formed red cells. At no time during the course of treatment did the patient exhibit any symptoms of moderate or severe clinical toxicity. Mild nausea and vomiting were the only complaints. Renal toxicity was effectively prevented by hydration and urinary alkalinization²³. Leucovorin rescue at $15\text{mg}/\text{m}^2$ every 6 hours was continued until MTX levels fell below 1.0×10^{-7} M. This effectively prevented hematologic and mucosal toxicity. Moreover at 48 hours post- infusion, MTX levels in plasma were well below 10^{-6} M (Figure 2). Levels above 10^{-6} M at 48 hours are directly related to severe toxic effects^{19,23-25}. Patient received three courses of MTX at 12Wm^2 one week apart, followed one week later by chemotherapy with bleomycin, cyclophosphamide and actinomycin-D. Three weeks later, he received fourth course of MTX ($12 \text{g}/\text{m}^2$). At the end of the fourth course of MTX, he had achieved significant tumor regression. He underwent amputation in February 1989. Since then he has been continued on T-IO protocol and till today, remains disease free.

DISCUSSION

During the past several years, there has been a significant improvement in the disease-free survival of patients with osteosarcoma. Although it has been mostly attributed to the use of adjuvant chemotherapy, controversy remained as to the precise role played by chemotherapy. Some studies clearly showed better outcome with the use of chemotherapy^{2,5-7}, others maintained that the natural history of the disease has changed to that of a better prognosis with surgery alone²⁶. Regarding the studies that failed to show the efficacy of the adjuvant chemotherapy, the poor response was attributed to the use of chemotherapy, the poor response was attributed to the use of sub-optimal doses of MTX⁷. More recently, two large multi-institutional studies have clearly established the role of chemotherapy in the management of osteosarcoma^{27,28}. MTX at $12 \text{g}/\text{m}^2$ plays a central role in the drug combinations used in the management of osteosarcoma^{6,18,20,27,28}. These high doses have been suggested to increase passive diffusion into the tumour cells and overcome drug resistance caused by amplification of DHFR gene as well as the induction of a low-affinity DHFR^{9,10}. This therapy, however, can be extremely toxic. Major toxicity is severe mucositis, bone-marrow suppression and azotemia. Utilizing proper precautionary measures, such as hydration and alkalinization of urine to decrease MTX precipitation in the renal tubules and leucovorin rescue to prevent bone marrow suppression, this treatment can safely be given. Indeed, in our patient no clinical toxicity was observed. CBC, electrolytes, BUN and creatinine were repeatedly measured and remained within normal limits. The MTX plasma levels achieved were clearly in a range (10^{-4} to 10^{-5} M) that is associated with enhanced passive diffusion of drug into the tumor cells. Erythrocytes MTX levels also were indicative of substantial entry of drug into the RBC's. After the first infusion, these levels were found to be greater than 10^{-7} M at different time intervals. These higher levels are partly contributed by the MTX that got incorporated into the red cell precursors in the bone marrow during the earlier infusions since RBC's take 5-7 days to mature and enter the circulation²². The efflux of MTX from the red cells as the plasma concentration decreases may serve to deliver supplementary amount of the drug to the tissues. Since tumor tissue in osteosarcoma has been shown to accumulate more drug than the surrounding normal tissue, this may account for enhanced cytotoxic effect on the tumour cells while sparing the normal tissue^{5,29}. The

clinical response in this patient is most encouraging. Twenty years ago, these patients had more than 80% chance of developing metastatic disease³⁰. With the protocols similar to the one used here, prognosis has improved to a disease-free survival of over 70% at 5 years³¹⁻³³. This patient remains disease free at 18 months of follow-up.

ACKNOWLEDGEMENTS

We gratefully acknowledge the technical help of Ms. Naseema Mehboobali in conducting the MTX assays. We also appreciate the useful suggestions and support of Professor M. Anwar Waqar.

REFERENCES

1. Jaffe, N., Frei, E. III., Traggis, D. and Bishop, Y. Adjuvant methotrexate and citrovorum factor treatment of osteogenic sarcoma. *N. Engl. J. Med.*, 1974; 291 : 994.
2. Jaffe, N. Pediatric solid tumors and the introduction of rescue therapy. *Cancer Bull.*, 1981; 33 : 59.
3. Jotivet, J., Cowan, K.H., Curt, G.A., Clendeninn, NJ. and Chabner, B.A. The pharmacology and clinical use of methotrexate. *N. Engl. J. Med.*, 1983; 309: 1094.
4. Isacoff, W.H., Townsend, C.T. Jr., Eilber, F.R., et al. High dose methotrexate therapy of solid tumors: Observations relating to clinical toxicity. *Med. Pediatr. Oncol.*, 1976; 2: 319.
5. Kimura, K. High-dose methotrexate for adult malignancies. *Cancer Bull.*, 1981 ; 33 67.
6. Edmonson, J.H., Green, S.J., Ivins, J.C., Gilchrist, G.S., Creagan, E.T., Pritchard, D.J., Smithson, W.A., Dahin, D.C. and Taylor, W.F., et al. A controlled pilot study of high-dose methotrexate as postsurgical adjuvant treatment for primary osteosarcoma. *J. Clin. Oncol.*, 1984; 2: 152.
7. Rosen, G. and Nirenberg, A. Chemotherapy for osteogenic sarcoma; an investigative method, not a recipe. *Cancer Treat. Rep.*, 1982; 66: 1687.
8. Isacoff, W.H., Morrisson, P.F., Aroesty, J., Willis, K.L., et al. Pharmaco-kinetics of high-dose-methotrexate with citrovorum factor rescue. *Cancer Treat. Rep.*, 1977; 61: 1665.
9. Bender, R.A. Membrane transport of methotrexate (NSC - 740) in human neoplastic cells. *Cancer Chemother. Rep.*, 1975; 6: 73.
10. Goldman, I.D. Analysis of the cytotoxic determinants for methotrexate : A role for free extracellular drug. *Cancer Chemother. Rep.*, 1975 ; 6 : 51.
11. Fry, D.W., Anderson, L.A., Borst, M. and Goldman, I.D. Analysis of the role of membrane transport and polyglutamation of methotrexate in gut and the Ehrlich tumor in vivo as factors in drug sensitivity and selectivity. *Cancer Res.*, 1983; 43: 1087.
12. Mail, J.T., Cohen, M.D., Mirkin, L.D. and Provisor, A. J. Response of osteosarcoma to preoperative intravenous high-dose methotrexate chemotherapy: CF evaluation. *AJR.*, 1985; 144 : 89.
13. Frei, E. III., Blum, R.H., Pitman, S.W., Kirkwood, J.M., Henderson, I.C., Skarin, A.T., Mayer, R.J., Bast, R.C., Garnick, M.B., Parker, L.M. and Canellor, G.P. High dose methotrexate with leucovorin rescue; rationale and spectrum of antitumor activity. *Am. J. Med.*, 1980; 68: 370.
14. Jaffe, N., Frei, E. III., Traggis, D. and Watts, H. Weekly highdose-methotrexate-citrovorum factor in osteogenic sarcoma; presurgical treatment of primary tumor and of overt pulmonary metastases. *Cancer*, 1977; 39 : 45.
15. Pratt, C.B., Howarth, C., Ransom, J.L., Bowler, D., Green, A.A., Kumar, A.P., Rivera, G. and Evans, W.E. High-dose methotrexate used alone and in combination for measurable primary or metastatic osteosarcoma. *Cancer Treat. Rep.*, 1980; 64:11.
16. Rosen, G., Marcove, R.C., Caparros, B., Nirenberg, A., Kosloff, C. and Huvos, A.G. Primary osteogenic sarcoma : The rationale for preoperative chemotherapy and delayed surgery. *Cancer*, 1979; 43:2163.

17. Jaffe, N., Link, M.P., Cohen, D., Traggis, D., Frei, E., Watts, H., Beardslay, G.P. and Abelson, H.T. High-dose methotrexate in osteogenic sarcoma. *Natl. Cancer Inst. Monogr.*, 1981 ; 56 : 201.
18. Rosen, O. High-dose-methotrexate with lcuovorin rescue : Treatment of osteogenic sarcoma and guidelines for clinical use, in *pharmanual ; a comparchensive guide to the therapeutic use of methotrexate in osteogenic sarcoma*. Edited by G. Rosen. 1984, p.47.
19. Iqbal, M.P., Khursheed, M. and Mahboobali, N. Methotrexate clearance and clinical toxicity in osteosarcoma following high- dose methotrexate therapy. *J.P.M.A.*, 1989; 39 : 38.
20. Rosen, G., Caparros, B., Huvos, A.G., Kosloff, C., Nirenberg, A., Cacavio, A., Marcove, R.C., Lane, J.M., Mehta, B. and Urban, C. Preoperative chemotherapy for osteogenic sarcoma; selection of postoperative adjuvant chemotherapy based on the response of the primary tumor to preoperative chemotherapy. *Cancer*, 1982; 49:1221.
21. Rothenberg, S.P., daCosta, M. and Iqbal, M.P. Ligand-binding radioassay for the antifolate compounds; application in patients receiving methotrexate. *Cancer Treat. Rep.*, 1977; 61 : 575.
22. daCosta, M. and Iqbal, M.P. The transport and accumulation of methotrexate in human erythrocytes. *Cancer*, 1981; 48: 2427.
23. Nirenberg, A., Moscde, C., Mehta, 13., Gisolfi, A.L and Rosen, G. High-dose methotrexate with citrovorum factor rescue; predictive value of serum methotrexate concentrations, and corrective measures to avert toxicity. *Cancer Treat. Rep.*, 1977; 61: 779.
24. Stroller, R.G., Hande, K.R., Jacobs, S.A., et al. Use of plasma pharmacokinetics to predict and prevent methotrexate toxicity. *N. Engl. J. Med.*, 1977; 297: 630.
25. Perez, C., Wang, Y. M., Sutow, W.W., et al. Significance of 48 hour plasma level in high dose methotrexate regimens. *Cancer Clin. Trials*, 1978; 1 : 107.
26. Carter, S.K. Adjuvant chemotherapy in osteogenic sarcoma; the triumph that isn't? *J. Clin. Oncol.*, 1984; 2: 147.
27. Winkler, K., Beron, G., Kotz, R., Salzer-Kuntschik, M., et al. Neoadjuvant chemotherapy for osteogenic sarcoma; results of a Cooperative German/Austrian study. *J. Clin. Oncol.*, 1984; 2 (6) : 617.
28. Link, M.P., Goorin, A.M., Miser, A.W., Green, A.A., et al. The effect of adjuvant chemotherapy on relapse-free survival in patients with osteosarcoma of the extremity. *N. Engl. J. Med.*, 1986; 314:1600.
29. Yaniawaki, S., Isu, K., Yagi, T., et al. Methotrexate tissue concentration and histological changes after high-dose methotrexate infusion for osteosarcoma, in *methotrexate in cancer therapy*. Edited by K. Kimura and Y.M. Wang. New York, Raven Press, 1986, p. 69.
30. Friedman, M.A., and Carter, S.K. The therapy of osteogenic sarcoma; Current status and thoughts for the future. *J. Surg. Oncol.*, 1972; 4:482.
31. Rosen, G. Role of chemotherapy in the treatment of primary osteogenic sarcoma : a five-year follow up on T-10 neo-adjuvant chemotherapy, in *methotrexate in cancer therapy*. Edited by K. Kimura and Y.M. Wang, New York, Raven Press, 1986, p. 227.
32. Rosen, G. Preoperative (neoadjuvant) chemotherapy for osteogenic sarcoma: a ten year experience. *Orthopedics*, 1985; 8:659.
33. Rosen, O. and Nirenberg, A. Neoadjuvant chemotherapy for osteogenic sarcoma : a five-year follow-up (T-10) and preliminary report of new studies (T-12). *Prog. Clin. Biol. Res.*, 1985; 201 : 39.