

ENTEROLITHIASIS SECONDARY TO INTESTINAL TUBERCULOSIS

Pages with reference to book, From 286 To 287

Mohammad Younus Sheikh, Shabbir Ahmad Naeem, Iftikhar Ahmad (Department of Radiology, The Aga Khan University Medical Centre, Karachi.)

Imtiaz Hussain Rizvi (Departments of Radiology, The Aga Khan University Medical Centre, Karachi.)

Intestinal tuberculosis is a relatively common ailment in South East Asia. Enterolithiasis is a rare complication due to stasis caused by stricture formation. We present a case of enterolithiasis secondary to intestinal tuberculosis.

CASE REPORT

A 59 year old lady presented in emergency room with signs and symptoms of sub acute intestinal obstruction. She gave history of recurrent abdominal pain. hematological investigations were within normal limits. Serum calcium was 9.6 mg% and phosphate was 4.4 mg%. Chest X-ray revealed old healed tuberculosis. Abdominal films showed multiple, faceted calculi in lower abdomen (Figure 1).

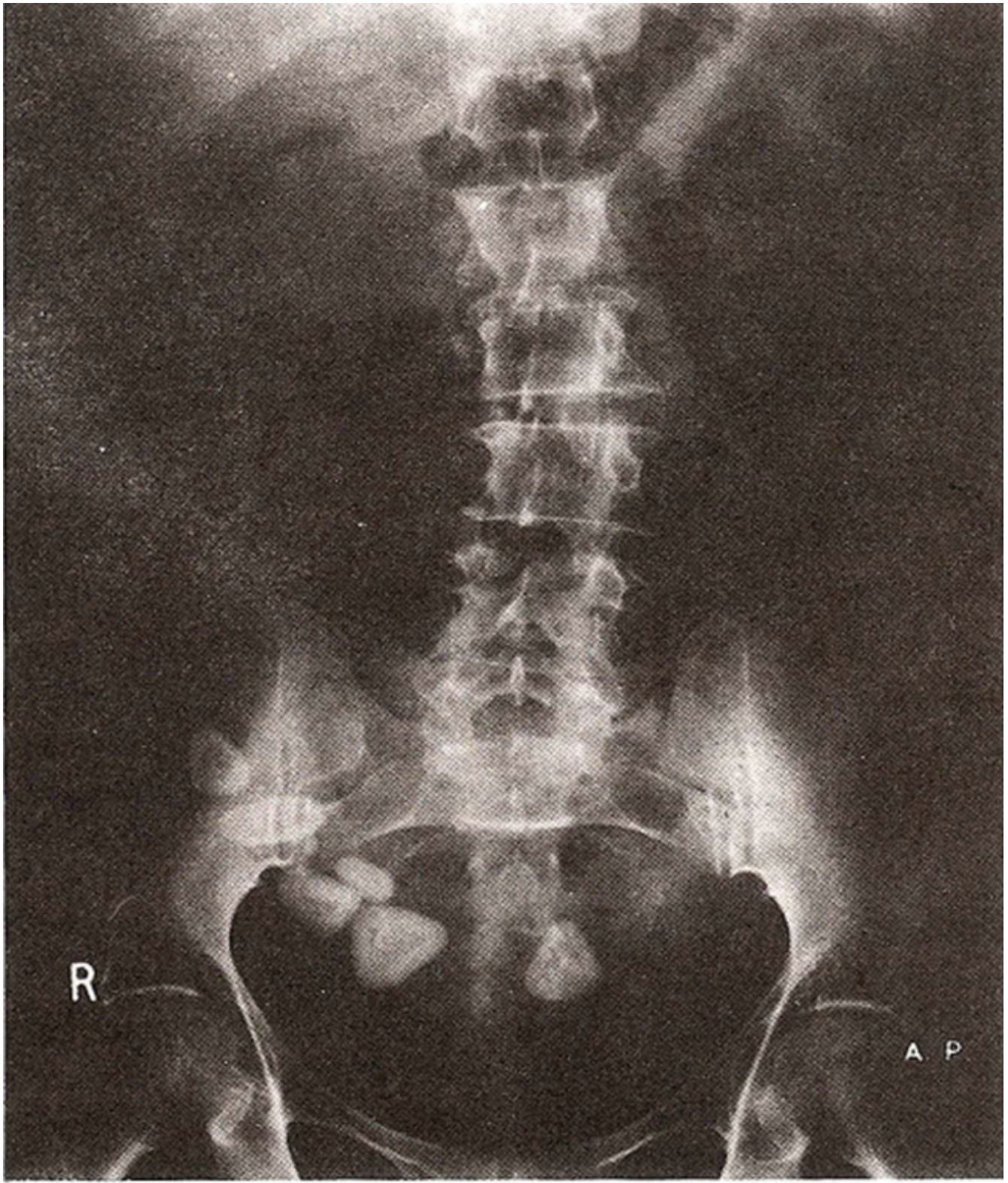


Figure 1. Multiple faceted calculi in lower abdomen.

These calculi were proved to be in dilated terminal ileum on barium enema, seen as filling defects. Calculi were impacted proximal to distal ileal stricture (Figure 2).

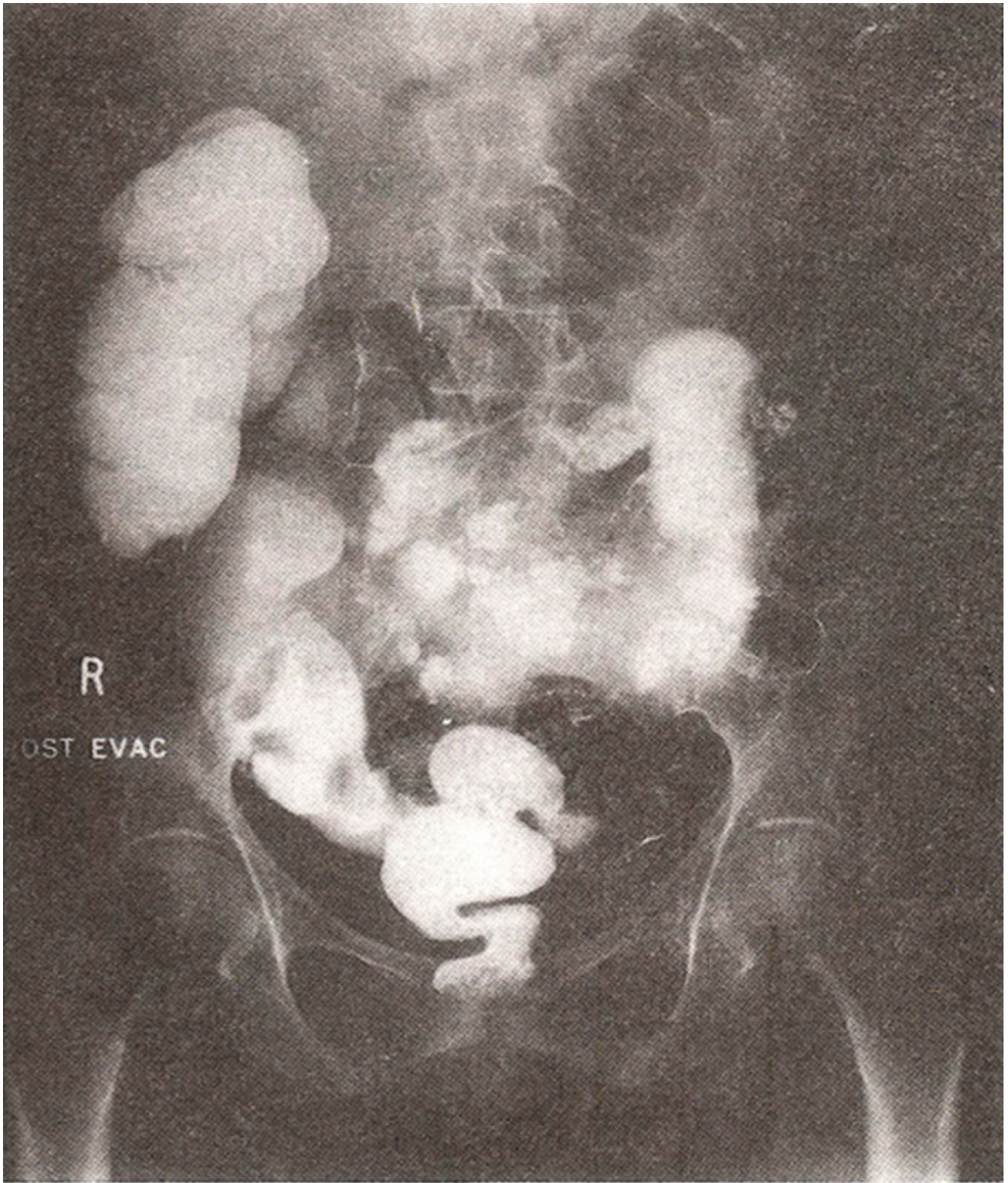


Figure 2. Calculi impacted due to proximal to distal ileal stricture.

Onlaparatomy ileum was found to be scarred. Limited right hemicolectomy with end to end ileocolostomy was performed. Histopathology showed chronic granulomatous changes in ileum. Chemical analysis of the stones was not performed.

DISCUSSION

Enterolithiasis is a rare disease complicating stasis in small or large bowel. It has been described with congenital and acquired diverticula^{1,2}. Stone formation is also associated with Crohn's disease, intestinal tuberculosis and malignancy leading to stricture formation¹⁻⁴. Stones usually form around nidus of vegetable origin or bacterial clumps⁵. Enteroliths are divided into two groups, false enteroliths which are inspissated intestinal contents (fecoliths) and true enteroliths⁶. True enteroliths are again classified into those that are formed in proximal small bowel and distal small bowel. Stones that are formed in proximal small bowel are composed of choleic acid and are radiolucent. These are the commonest type of enteroliths found. These may be formed in duodenal or jejunal diverticula due to altered flora because of stasis. Second type of true enteroliths are formed in distal small bowel and are radio-opaque, composed of calcium carbonate or calcium phosphate in nature. This is because of the fact that distal small bowel is more alkaline which renders calcium less soluble. Stones composed of calcium oxalate¹. Magnesium barium and casein⁴ have also been reported. Patients present with symptoms of intermittent acute or subacute intestinal obstruction. Diagnosis depends on seeing mobile calcific densities on repeated plain abdominal films³. Barium enema and enterocolysis can be used to confirm the stones to be in the intestinal lumen. C.T. appearance of enterolith has been described⁵ which presents as concentric laminated mass resembling intersusception. Enteroliths should be differentiated from vesical calculi, gall stones, and renal calculi. Oral cholecystogram, excretory urography and ultrasound are helpful in differentiating.

ADDENDUM

Four more cases of enterolithiasis were diagnosed. These patients presented with symptoms of subacute intestinal obstruction. Enterocolysis was performed on these patients which confirmed stones in the lumen of small bowel, proximal to ileal stricture. Two of these patients had evidence of pulmonary tuberculosis. They were all treated with antituberculous chemotherapy.

REFERENCES

1. Rathore, A.H. and Khan, Ml. Enterolith. JPMA., 1981; 31:49.
2. Atwell, J.D. and Pollock, A.V. Intestinal calculi. Br. J. Surg., 1960; 47:367.
3. Chawla, S., Beery, K and Indra, K.J. Enterolithiasis complicating intestinal tuberculosis. Clin. Radiol., 1966; 17:274.
4. Singleton, 3M. Calcific enterolith obstruction of the intestine. Br. 3. Surg., 1970;57:234.
5. Berry, D.F., Willing, SJ. and Beers, G.J. Small bowel obstruction due to enterolith: CT appearance. J. Comput. Assist. Tomogr., 1987;11:707.
6. Gardiner, K.R. and Maxwell, R.J. Incidental enterolithiasis. Ulster Med. J., 1989;58:196.