

CYSTICERCOSIS IN A MUSLIM WOMAN

Pages with reference to book, From 23 To 24

Farrukh Aijaz (Departments of Histopathology, The Aga Khan University Hospital Karachi.)

Altaf Ahmed (Departments of Microbiology, The Aga Khan University Hospital Karachi.)

A cystic, subcutaneous nodule is usually thought of as a sebaceous cyst in Pakistani context. We present a case in which a clinical diagnosis of sebaceous cyst was made but turned out to be cysticercosis on pathological examinations.

CASE REPORT

A 30 year old Muslim woman presented with a one year history of a subcutaneous nodule on the right lower chest. The swelling was 2x1x1 cm, non-tender and mildly fluctuant. The overlying skin was unremarkable. She was afebrile without any other clinical symptoms. She had frequent history of travel to India. The entire nodule was removed and sent for histopathology. Histological sections showed a cystic lesion with fibrous outer covering consisting of chronic and foreign body granulomatous inflammation. The cyst consisted of a larva showing a single invaginated scolex (Figure 1).

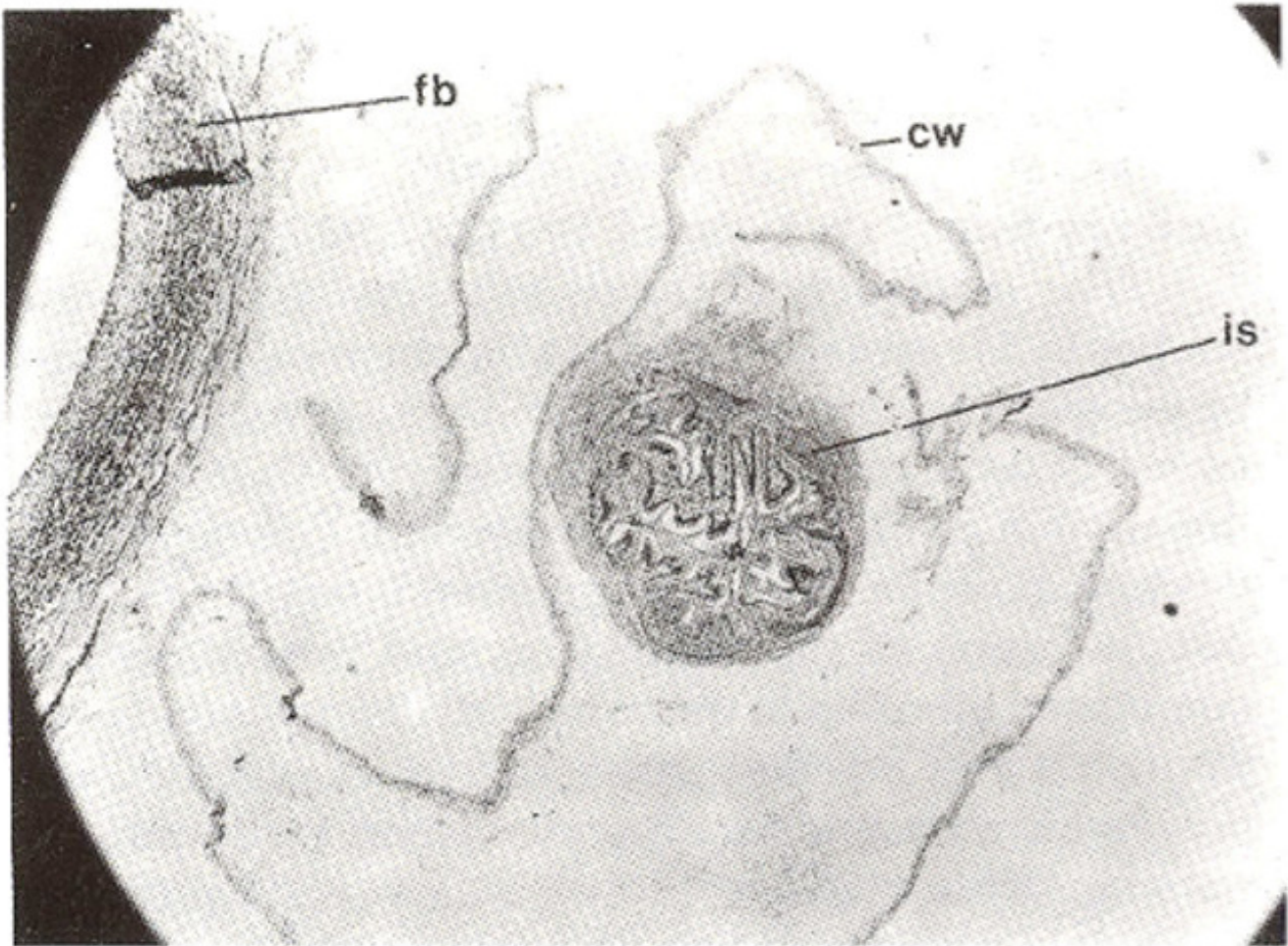


Figure 1. Cysticercus showing invaginated scolex (is) cyst wall (cw) and fibrous response of host (fb) (H&Ex40).

The scolex had two suckers containing a double row of birefringent hooklets. The parenchyma of the

scolex was loose with smooth muscles and mesenchymal fibres with calcareous corpuscles (Figure 2).

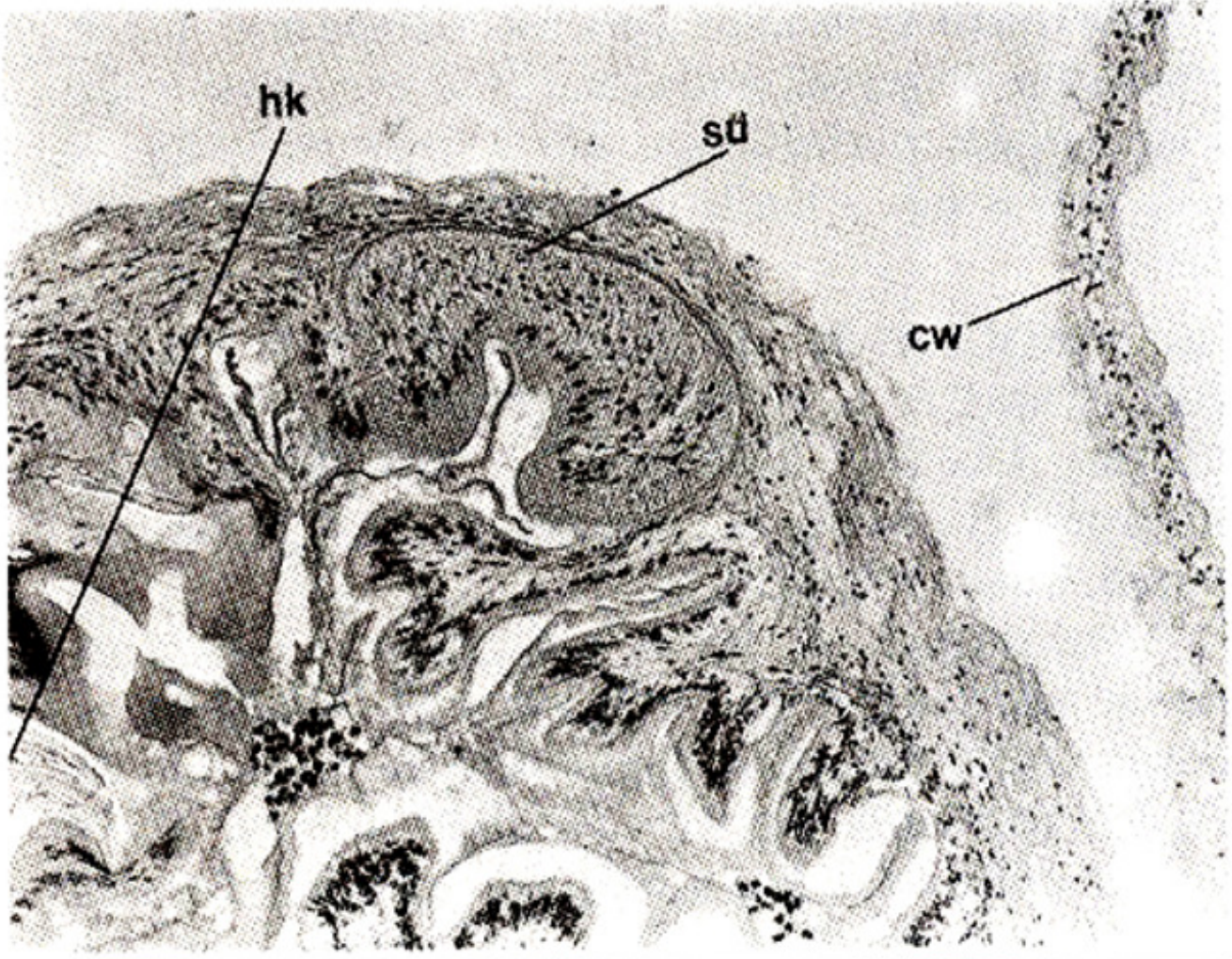


Figure 2. Enlarged view of cysticercus showing sucker (su) and hooklets (hk) (H&Ex400).

The larva also had a peripheral cyst wall away from the scolex showing degenerative changes with multiple raised projections.

DISCUSSION

Cysticercosis is the larval form of taenia solium, the adult worm living in the intestine of man usually causes little harm. Serious problems may arise, however, when man accidentally becomes the intermediate host by harboring the larval stage (cysticercus). When man swallows eggs or proglottid, the oncosphere are released in the intestine, penetrate the mucosa and are carried in lymphatic and blood vessels to various organs and tissues, where they develop into cysticercos¹. Cysticercosis is considered a rare entity in Pakistan, because of its association with eating of pork. Although there is no pertinent data available in Pakistan regarding its incidence, one should keep the possibility of finding them in person presenting with a subcutaneous nodule, specially with a travelling history to neighbouring countries like India², where it is endemic.

REFERENCES

1. Sparks, A.K., Neafie, R.C. and Connor, D.H. Pathology of tropical and extraordinary diseases. Edited by C.H. Binford and D.H. Conner. Armed Forces Institute of Pathology, Washington. 1976, pp.539-43.
2. Checabrough. M. Medical laboratory manual for tropical countries. 2nd ed. London, Butterworth, 1987, vol. 1, pp. 294-96.