

Ureterorenoscopy in Children

Pages with reference to book, From 195 To 196

Khalid Rasheed (Departments of Paediatric Surgery, The Aga Khan University Hospital, Karachi.)

Amanullah Memon (Departments of Surgery, The Aga Khan University Hospital, Karachi.)

Abstract

Renal and ureteric calculi is an uncommon problem in western hemisphere but Pakistan being in the middle of the stone belt has much higher incidence. Open surgery has produced excellent results but the non-invasive lithotripsy and minimally invasive endoscopic management of urinary tract stones has changed the attitudes towards acceptance of open surgery by patients and the relatives. Extracorporeal shock wave lithotripsy (ESWL), percutaneous nephrolithotomy (PCNL) and ureterorenoscopy (URS) is widely reported for adult population. Though ESWL has been widely employed, there are very few reports of PCNL and URS being used in children. We present a case of successful stone retrieval by URS in a child.

Case Report

A twelve years old petite boy presented to the out-patients with a 2 week history of abdominal pain associated with haematuria. Plain X-ray of the abdomen (Figure 1)

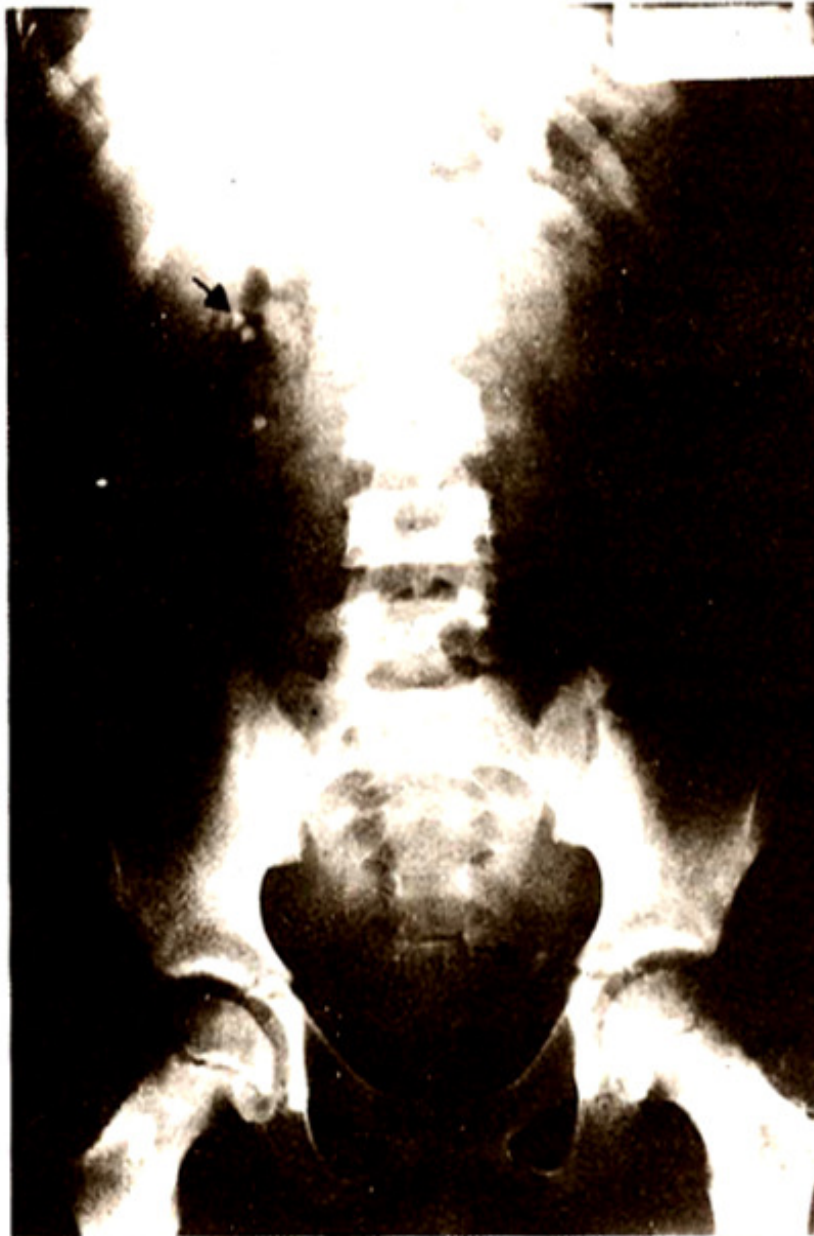

Figure 1. Pre-operative, plain X-ray of abdomen showing left ureteric and multiple right renal calculi.

revealed a 1.5 cm/0.5 cm left lower ureteric stone with three small 0.5 x 0.5 cm stones seen in the right renal pelvis. Intravenous program (IVU) showed moderate hydronephrosis. Metabolic work up carried out on serum and urine did not reveal any cause for stone formation. Under general anaesthesia cystoscopy was performed and a Double J Stent (DJS) was placed in the left ureter (Figure 2).

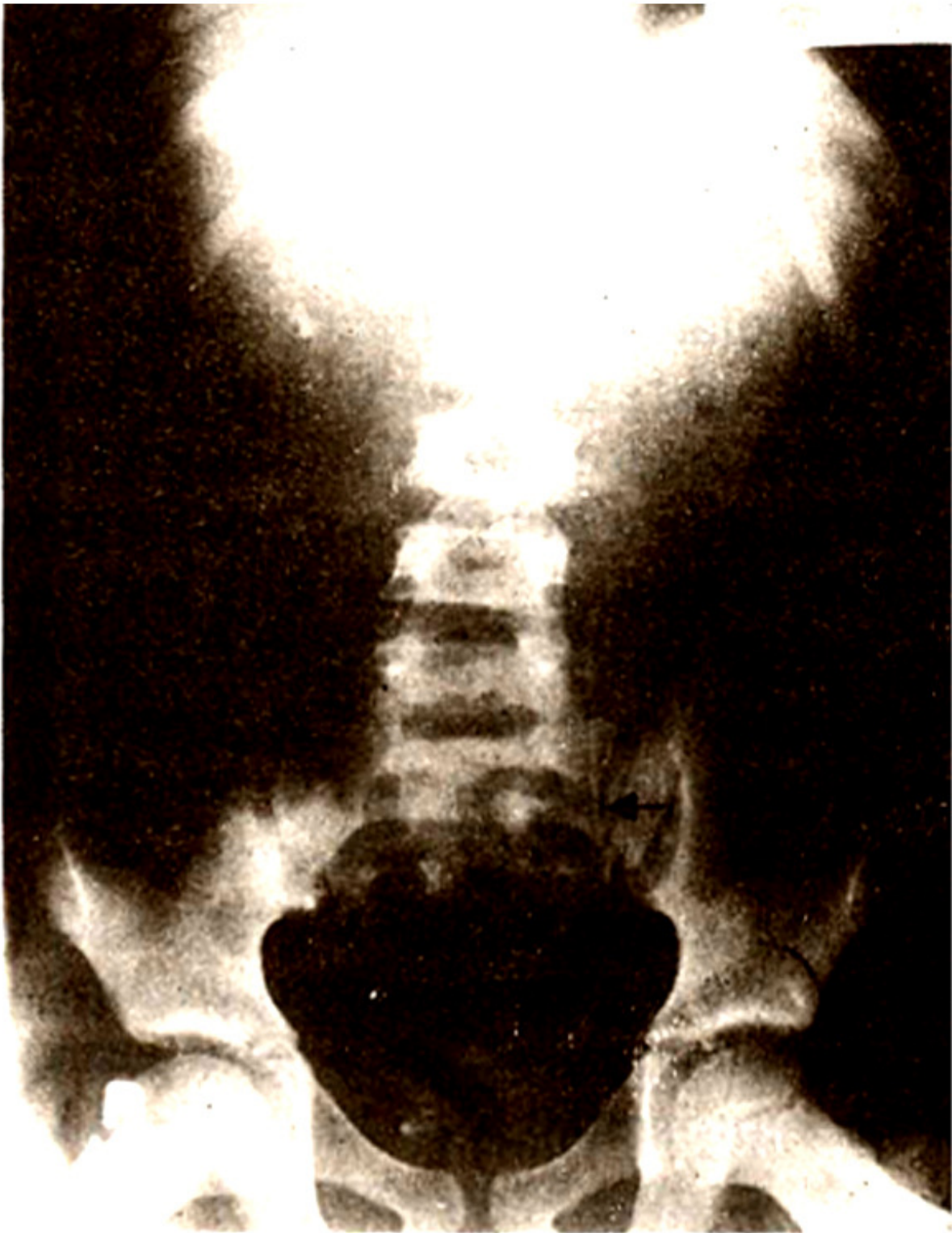


Figure 2. Plain X-ray abdomen showing double J Stent in left ureter.

Patient was prescribed prophylactic antibiotics. Six weeks later, under G.A., DJS was removed and a 13.5F Paiez Castre Ureteroscope (Storz) was introduced into the left ureter with ease and the stone was retrieved. The patient made an uneventful recovery and was discharged home after 24 hours of hospital stay. Right renal stones were removed by pyelolithotomy at a later date. A follow-up plain X-ray of

abdomen showed complete clearance of calculi (Figure 3).

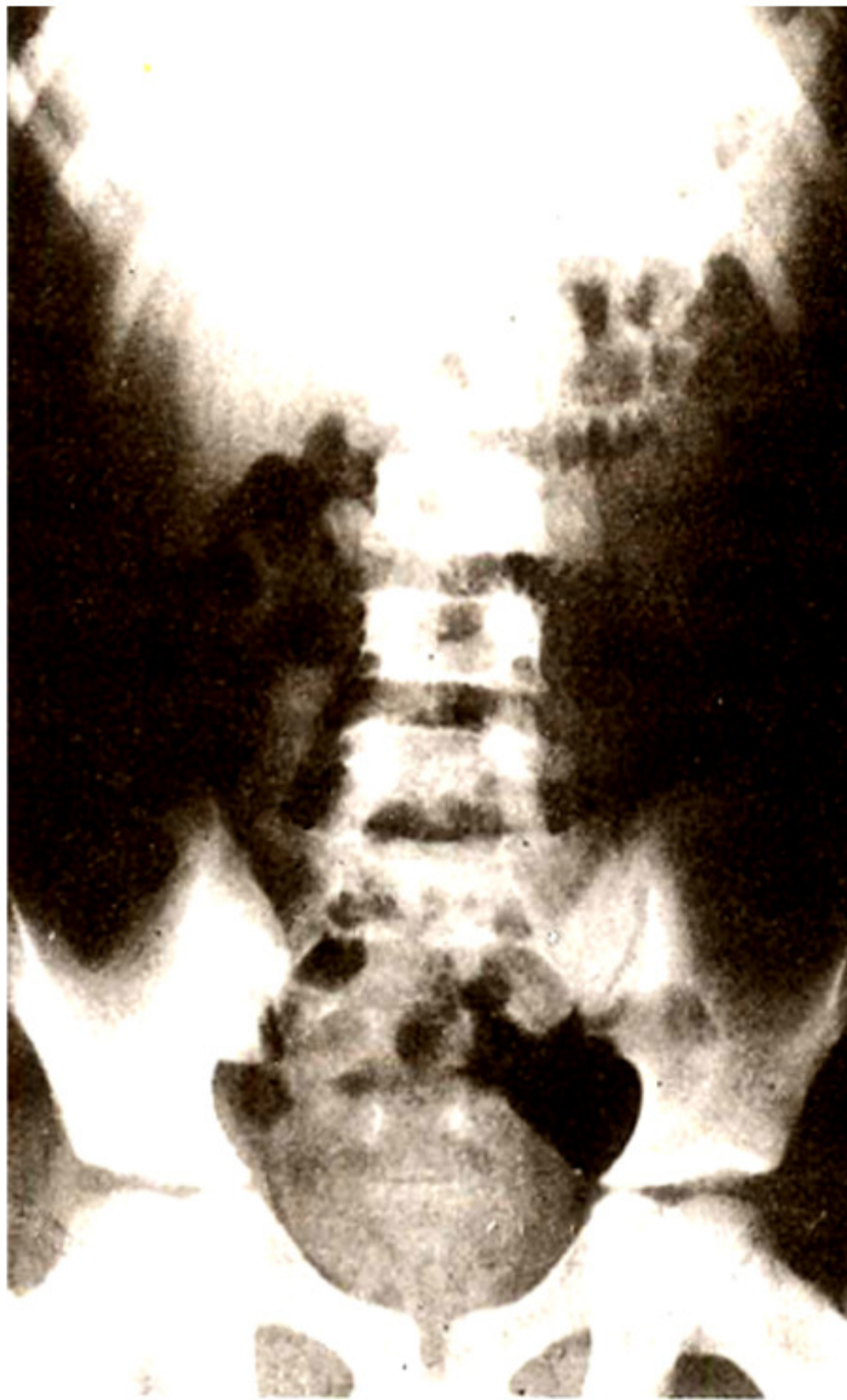


Figure 3. Follow-up X-ray after ureterorenoscopy showing clearance of stone.

At eighteen months follow-up the child has remained well and stone free.

Discussion

Ureteric calculi have been traditionally treated by open surgery in children. Abundance of urolithiasis in children of Pakistan pose a substantial challenge to the treating surgeon when compared to the countries like United States where one incidence of calculus was reported in over 1,400 paediatric admissions¹. In children ESWL has been described for renal and upper ureteric calculi². However, the role of ureteroscopy in children has not been adequately established. Successful retrieval of ureteric calculi has given us an opportunity to consider exploitation of this modality for children. The most limiting factor was the availability of a suitable calibre of the instrument. It is, therefore, important that appropriate armamentariums available for regular ureterorenoscopy service in paediatric urology practice. Management of the lower ureteric calculi is particularly challenging not only with open surgery but also by highly acclaimed extracorporeal shock wave lithotripsy. The ESWL has a question off easibility in the lower ureter because the safety of ESWL in true pelvis has not been established for children. Push-bang techniques are feasible for stones in the upper ureter and perhaps in the mid-ureter, for the lower ureteric stones one has to resort to either open or endoscopic retrieval. Ureterorenoscopy has been described as being the accepted mode of managing lower third ureteral stones in adults³. With the advent of the ultrasonic electrohydraulic and laser lithotriptors the larger ureteric calculi can be successfully fragmented and extracted ureteroscopically with a success rate of 90 to 96%⁴. Encouraging and successful results with the paediatric ureteroscopy have been reported in a smaller patient population^{5,6}. In our case the paediatric ureteroscope was not available; this problem can be overcome by leaving a Double J Stent in the ureter for approximately four weeks prior to ureteroscopy with adult size ureteroscope. The placement of DJS not only served as conduit to bypass the ureteric obstruction, it also caused dilatation of the ureter and its orifice, which in turn took a 13.5F ureteroscope easily. We should exploit this particular modality in the treatment of ureteric calculi in paediatric age group. However, we agree that caution is a key to the successful management of the ureteric calculi with ureteroscope in children particularly if one is to avoid trauma to urethra as well as ureter.

References

1. Malek, R.S. Urolithiasis In: Clinical paediatric urology, 2nd ed. Edited by PP. Kelasis, L.R., King and A.B. Belman Vol.2 Philadelphia, W.B. Saunders Co., 1983.
2. Shephard, P., Thomas, R. and Harmon, EP. Urolithiasis in children: Innovations in management. J.Urol., 1988;140:790-92.
3. Lyon, ES., Huffinan, J.L. and Bagley, D.H. Ureteroacopy and ureteopyelocopy. Urology, 1984;23 (suppl. 5):29-31.
4. Segura, J.W. Endourology. J.Urol., 1984;132: 1079-84.
5. Hill, D.E., Segura, J.W, Patterson, OS. et al. Ueeteroscopy in children. J.Urol., 1990;144:481-83.
6. Calone, P., Be Gennaro, M., Capozza, N. et al. Endoacopic manipulation of ureteral calculi in children by rigid operative ureteroacopy. J.Urol., 1990;144:484-85.