

Coexistent Tuberculosis and Carcinoma of the Colon

Pages with reference to book, From 305 To 306

Muhammad Younus Sheikh, A. H. Yousuf, Tahir Rasheed Khalid, Muhammad Umar Islam, Muhammad Nadeem Ahmed
(Department of Diagnostic Radiology, Aga Khan University Hospital, Stadium Road, Karachi.)

Colorectal cancer is currently ranked third in men after prostate and lung and second in women¹. Its association with inflammatory bowel disease is known. A cluster of case reports has accumulated on the coexistence of colonic carcinoma and tuberculosis (CTCC) in the same location². Association of long standing tuberculosis with cancer has been documented for many organs. We present a case report of coexistent carcinoma and tuberculosis involving the proximal colon and a review of literature.

Case Report

A 70 year old female presented with acute intestinal obstruction and a history of intermittent abdominal pain and occasional vomiting. Examination showed abdominal distension and an ill defined mass in right lumbar and hypochondriac region. Routine investigations were generally unremarkable. Plain abdominal film demonstrated features of intestinal obstruction. On barium enema a long stenotic segment was seen involving the ascending and proximal transverse colon showing ulceration, rigidity and mucosal distortion (Figure 1).

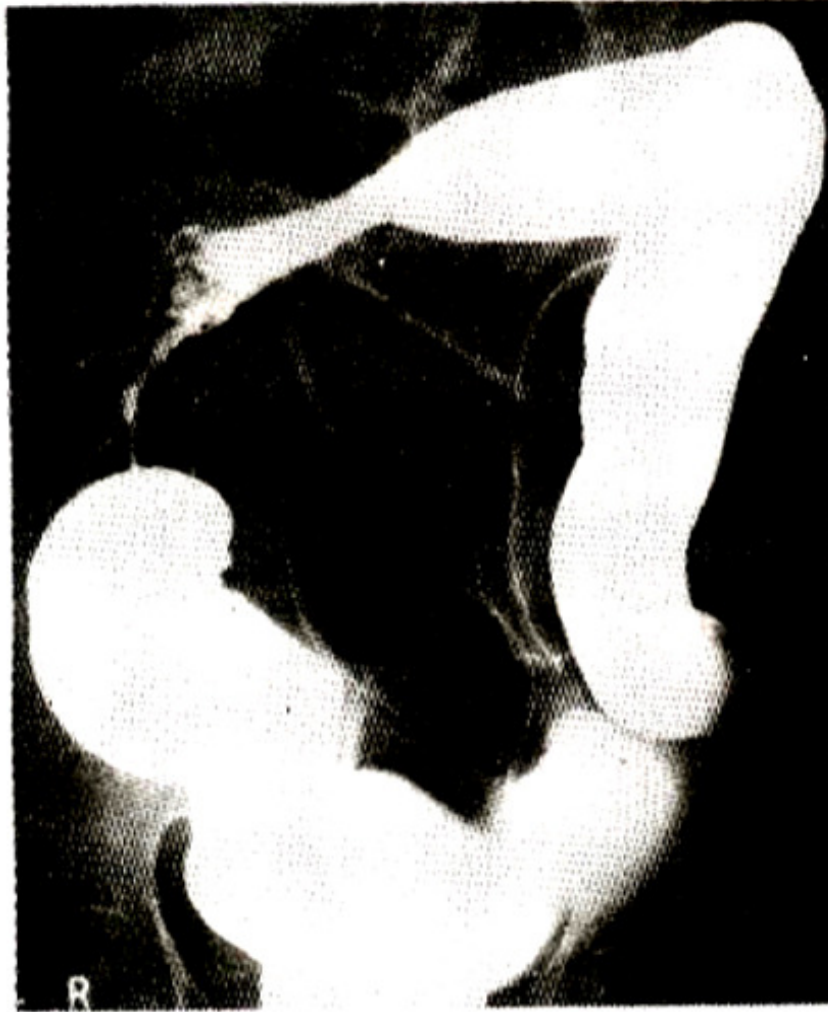

Figure 1. Pre-operative single contrast barium enema showing a long stenotic segment involving the ascending and adjacent transverse colon with ulcerations.

Colonoscopy and subsequent surgery showed a 15cm long stenosed segment engrossing the ascending and proximal transverse colon and containing a large polypoid growth arising from caecum and ascending colon with multiple satellite polyps. Histopathologically, there was a well differentiated mucin secreting adenocarcinoma. Present within the tumour producing colonic tissue were granulomas showing central necrosis and giant cells suggestive of tuberculosis. Regional mesenteric lymph nodes also contained similar granulomas. A diagnosis of adenocarcinoma (Duke's stage B2) with coexistent tuberculous colitis was made. Three years after right hemicolectomy and chemotherapy, the patient was alive with metastases, secondaries in peritoneum, sigmoid and recurrence at anastomotic site (Figure 2 and 3).

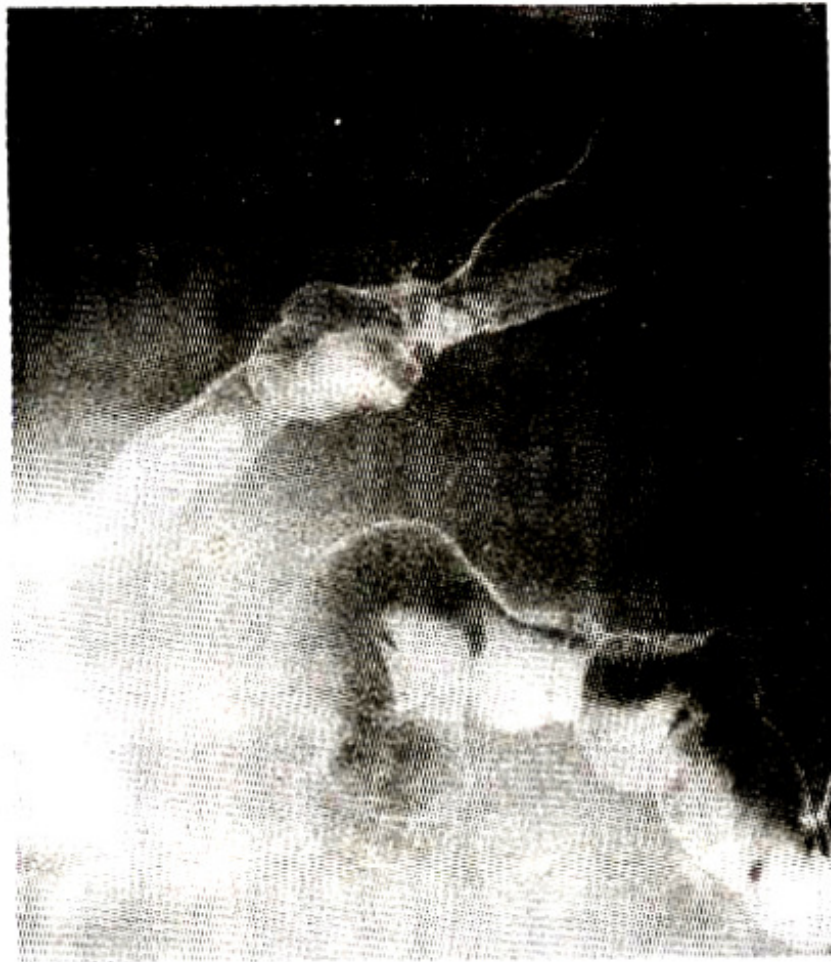

Figure 2. Post-operative double contrast barium enema. Tumour spread to superior part of sigmoid with mucosal lethering. Irregularity at anastomotic site is also seen.

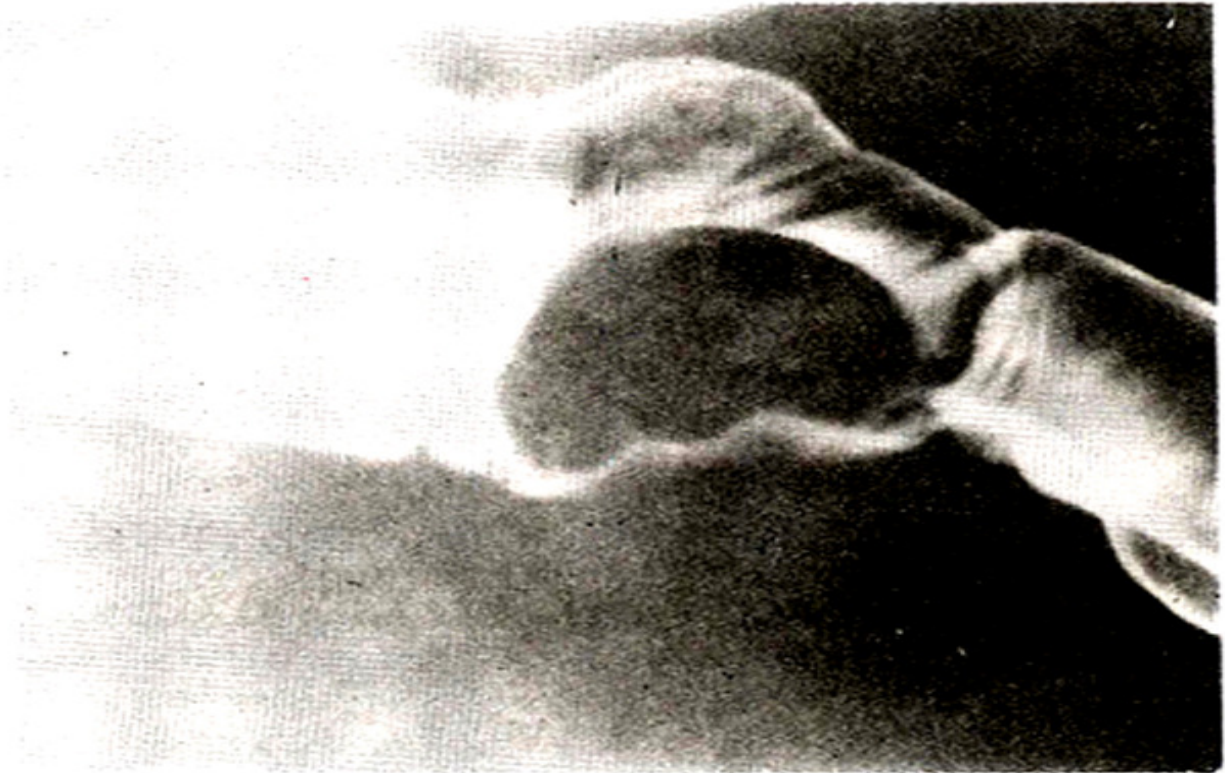
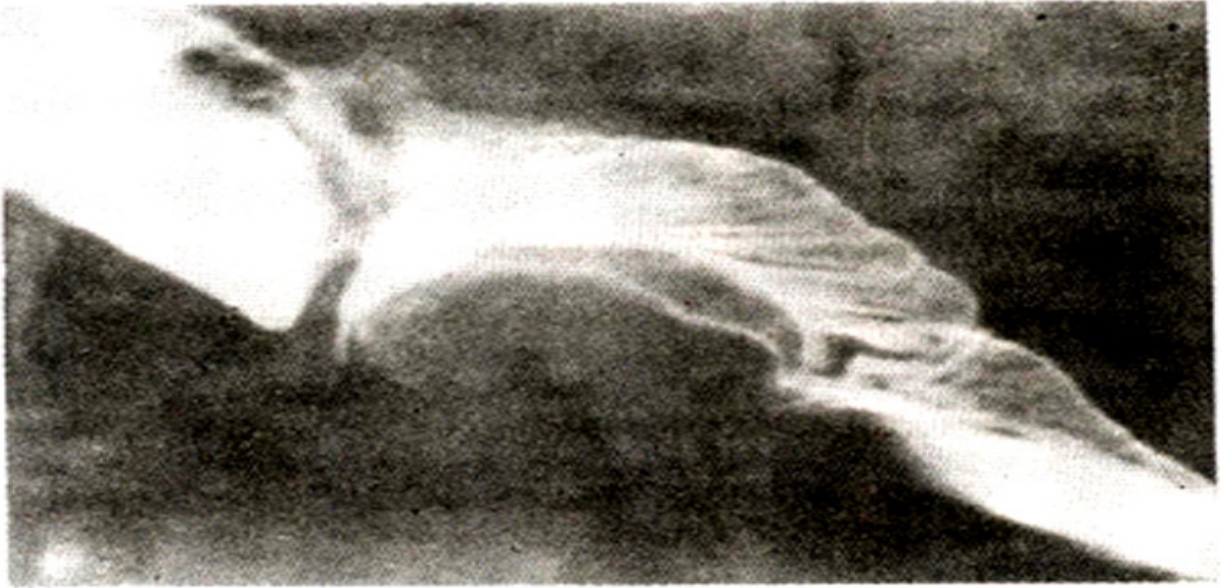

Figure 3 (a and b) Spot views from same examination as in figure 2. An eccentric filling defect at the site of anastomosis suggesting tumour recurrence.

Discussion

Gastrointestinal tuberculosis most commonly involves the ileocecal region followed by jejunum and colon. Multiple sites of involvement are common. Tanaka et al.⁴ have reviewed 27 cases of CTCC and described common features like female preponderance (34:50), involvement of right colon, Well

differentiated adenocarcinoma with a tendency to produce mucin being the commonest histopathological type. All these findings are consistent with those in our case. The chances of CTCC being a coincidence are highly unlikely, since a similar coexistence has been reported in the ileum⁵, where the occurrence of carcinoma without Crohn's disease is extremely rare. Moreover, the number of reported cases with CTCC is quite significant statistically (CTCC constituted 19% of all cases with colonic TB in the study of Jain et al). The site of occurrence of such carcinoma matches well with that favoured by tuberculous colitis. Another possibility, although less likely, is that carcinoma predisposes to tuberculous infection. Disruption of the integrity of mucosal barriers and impairment in cell mediated immunity associated with cancerous growth are known to predispose to bacterial infection². However the evidence of TB in the colon at a site distant from carcinoma in at least two cases of Jain et al. contradicts the hypothesis of a secondary infection in a pre-existing tumor. Moruta et al⁶ have postulated that ulcerative lesions of tuberculosis may be precursors of carcinomas, derived from a chronic inflammatory process with repetition of erosion, ulcer and consequent regeneration. Role of bacteria in the causation of colorectal carcinoma has only been discussed in association with toxic metabolite production through sterols secreted in the bile³. Whether mycobacteria have any significant bearing in this context is a matter of debate. There have been several claims during the last few decades that mycobacteria are responsible for a number of human diseases of unknown etiology, including Crohn's disease⁷, the malignant potential of which has now been accepted. There have also been recent reports of decreased natural killer (NK) cell activity⁸ and increased incidence of chromosomal aberrations⁹ in association with tuberculosis. Specific relationship, of both accelerating and controlling growth, exist between fibroblasts and epithelial cells¹⁰ and excessive fibroblastic activity is a constant finding in long standing tuberculous process. In conclusion, there is not enough evidence yet to affirm a positive etiological correlation between the two pathologies, but the available data certainly calls for further study. Clinical features of both tuberculosis and cancer may overlap e.g., weight loss, constipation, occult blood in stool etc. and the radiologic picture of an extensive ileocecal region and ascending colon tuberculosis, may be so dramatic as to mask a coexisting malignant process if not contemplated. This is especially true in an endemic region where the bias is predominantly in favour of tuberculosis. Careful endoscopy and biopsy of such "typical" looking colonic lesions is essential to rule out a coexisting carcinoma. The diagnostic possibility may also be considered on a barium enema showing overt malignancy of colon entailing an unduly long segment, particularly in the proximal colon.

References

1. Cady, B., Stone, M.D. and Wayne, J. Continuing trends in the prevalence of right sided lesions among colorectal carcinomas. *Arch. Surg.*, 1993;128:505-509.
2. Jain, B. K., Chandra, S. S., Narasimhan, R. et al. Coexisting tuberculosis and carcinoma of the colon. *Aust. N.Z. J. Surg.*, 1991 ;61 :828-31.
3. Bresalier, R. S. and Kim, Y.S. Malignant neoplasms of the large and small intestine. In: *Gastrointestinal disease 4th edo.* (Ed. M.I. Sleisenger and J.S. Fordtran), Chap. 81, Philadelphia. W.B. Saunders Philadelphia, 1989, PP 1519-60.
4. Tanaka, K., Kondo, S., Hattori, F. et al. A case of colonic carcinoma associated with intestinal tuberculosis and an analysis of 26 cases reported in Japan. *Gan. No. Rinsho.*, 1987;33:1117-33.
5. Cooper, M.J., Williamson, R.C.N. and Smith, I.I.E. Ileal carcinoma and tuberculous ileitis. *Postgrad. Med.J.*, 1987;63:145- 146.
6. Moruta, K., Tanaka, S., Nakamura, T et al. Carcinoma of the colon coexisting with tuberculosis . Report of 2 cases. *Gan. No. Rinsho.*, 1983;29:448-453.

7. Grange, J.M. Environmental mycobacteria and human disease *Lepr. Rev.*, 1991;62:353-61.
8. Restrepo, L.M., Barrera, L.F. and Garcia, L.F. Natural killer cell activity in patients with pulmonary tuberculosis and in healthy adults. *Tubercle.*, 1990;71 :95-102.
9. Gopal Rao, V.V. V.N., Gupta, E.E. V. and Thomas, I.M. Chromosome damage in untreated tuberculosis patients. *Tubercle.*, 1990;71 :169-172.
10. Potter, J.D. Reconciling the epidemiology, physiology and molecular biology of colon cancer. *JAMA.*, 1992;268:1573-77.