

# Longitudinal Vaginal Septum: An Unusual Cause of Postpartum Total Uterine Prolapse

Pages with reference to book, From 221 To 222

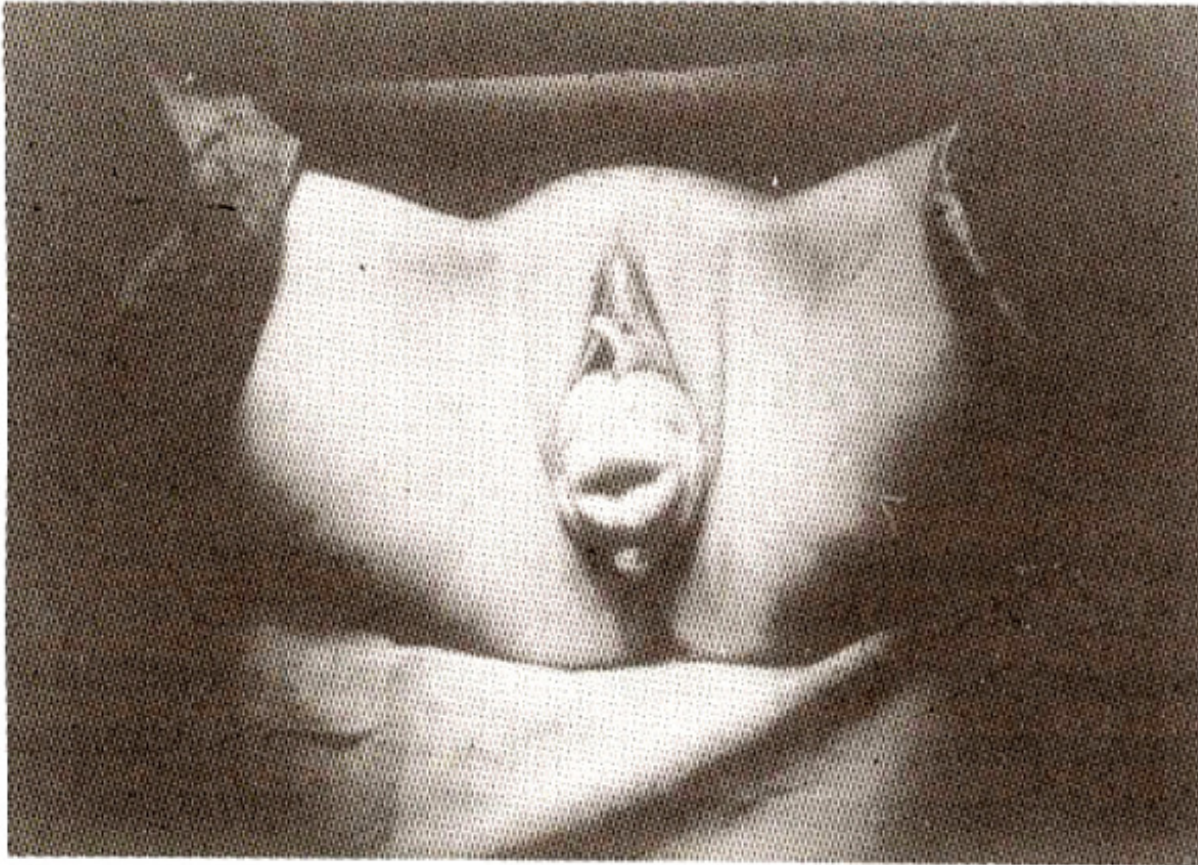
Fuat Demirci, Umur Kuyumcuoglu, Murat, API, Mehmet Ufudogan ( Department of Obstetric and Gynaecology, Zevnep Karnil Women and Children Hospital, Istanbul, Turkey. )

## Abstract

Longitudinal vaginal septum, a rare congenital fusion defect of mullanan ducts rarely causes dystosia of labour and total uterine prolapse. Several surgical techniques were developed for repair of prolapse but no consensus has been reached on one type of operation<sup>1</sup>.

## Case Report

A 25 years old female was admitted with a few months history of uterine prolapse. She was married 4 years ago and had her first coitus 5-6 months later because of pain. She could not get pregnant earlier than 3 years after her marriage although she wanted to . Labour pains began at term but the delivery process did not begin although pain lasted long. In the hospital where she was admitted before the vaginal septum was excised and a 3900 g live baby was delivered. Her postpartum and puerperal period was uneventful and sexual intercourse painless after birth of her baby. One year later she developed uterine prolapse. On gynaecological examination, she had total uterine prolapse with remnants of septum on the anterior and posterior part of vagina 1 cm in width and 4 cm in length (Figure).



**Figure. Total uterine prolapse with remnants of longitudinal vaginal septum on the superior and inferior part of cervix**

The patient had no symptoms of stress urinary incontinence. Being diagnosed as total uterine prolapsus, she was hospitalized. No pathological findings were noticed in routine examination. Superior and inferior abdominal ultrasonography and IVP were done to exclude a general connective tissue weakness and any other abnormality. No abnormalities were noted. Nichol's operation technique<sup>2</sup> was chosen to protect reproductive functions of the young patients. Through an infraumbilical median incision the abdomen was opened. The peritoneum was opened 2 cm at the upper third of sacrum. A longitudinal tunnel containing 1/3 of sacrum was established by using a long and curved kidney stone forceps. An 4x8 cm wide prolene mesh was folded longitudinally four times (like a ligament) and was attached to the cervix bilaterally between uterosacral ligaments by using two 0 prolene sutures. The other edge was passed through the tunnel and after elevating the uterus, it was fixed with two sutures to the periosteum of the sacrum bilaterally. Peritoneum reapproximated covering the prolene strap throughout its length. Afterward the Retzius space was entered. Burch operation was done by bilaterally placing three 0 vicryl sutures at a side that was passed through the perivaginal fascia and Cooper ligament. The abdomen was closed anatomically. Gynaecological examination done on the 2nd, 6th and 12th postoperative months was satisfactory.

### **Discussion**

Longitudinal vaginal septum is the fusion defect of Mullerian ducts. It may be partial or complete and it can be at inferior, middle or superior part of the vagina. Sometimes it covers every part of the vagina and two cervixes and two uteruses may accompany it. It may lead to infertility and recurrent abortions.

Inferiorly placed septum should be operated because it makes coitus difficult<sup>3</sup>. In our case also, the septum was in the inferior part of vagina; difficulty in coitus and infertility were mentioned in her history. Edward and Gale<sup>4</sup> described as an inherited autosomal dominant abnormality associated with urinary incontinence due to bladder neck abnormalities together with hand abnormalities. Johanson-Blizzard Syndrome, is inherited autosomal recessively with a longitudinal vaginal septum<sup>5</sup>. Several factors are responsible for uterine prolapse. The most common cause being destruction of pelvic supportive tissues, ligaments, fascias, muscles and nerves which can occur during vaginal delivery. Multiparity is also an important factor. Damage is seen mostly during operative deliveries with head and shoulder dystosia and prolonged labour<sup>1</sup>. In our case, these reasons did not exist, whereas there was a vaginal septum which rarely causes dystocia. At present, developments in obstetrics, common practice of caesarean section, use of contraception widely led to a decrease in multiparity which also caused a decrease in uterine prolapses. The type of prolapse seen in multiparous women can also be seen in nulliparous together with congenital elongatio collie<sup>2</sup>. In some cases of total uterine prolapse, stress urinary incontinence does not occur owing to folding of urethrovesical function and urethra during stress<sup>3</sup>. This symptom was not seen in our case. We added Burch colpo suspension to the operation aiming for stress urinary incontinence prophylaxis, presuming that attaching the vagina to Cooper ligament will provide an additional support. In young patients with total prolapse whose uterus should remain, the types of operations to be preferred are as follows; Modified Gilliam Doleres Suspension operation<sup>1</sup> with uterosacral ligament plication and culdeplasty may be combined with suprapubic colpourethroscopy and/or appropriate colporaphies. In Richardson and Ulfelder technique<sup>3</sup>, uterosacral ligament is attached to sacrospinal ligament transvaginally. Manchester operation<sup>1</sup> with cervical amputation, anterior plication of cardinal ligament, with appropriate colporaphies can provide proper support in patients with elongatio collie. This operation is usually done in Europe. In Williams'6 transvaginal technique, cardinal and uterosacral ligaments are first shortened and then attached to anterior part of cervix. This operation is not usually preferred. In all these operations which are aimed at preservation of fertility, there is a probability of recurrence. By the time the patient decides to have no more pregnancies, additional operations may become necessary. In our case, instead of fascia lata strap defined by Nichols<sup>3</sup>, prolene strap was used. The disadvantage of these operations is progression of cystocele and rectocele. Colporraphy is required, if there is a recurrence of vaginal prolapse but vaginal approach cannot be used. If hysterectomy is necessary, it may have to be performed transabdominally. Prolapse can be seen after menopause also. Besides the weakness in supportive tissue due to lack of estrogen, causes leading to an increase in intraabdominal pressure such as chronic obstructive respiratory disease, obesity, pelvic tumour, ascites, excessive exercise, heavy lifting, using firm corsets and straining at defecation which is due to anal stenosis or retrovert uterus also may contribute to the formation of prolapse. Parks et al. <sup>7</sup> suggested straining while defecation may be due to neuropathy affecting the pelvic floor muscles. Factor such as chronic constipation, chronic cough, obesity; excessive exercise and any congenital connective tissue weakness were not observed in this case. There was soft tissue dystosia (longitudinal vaginal septum) in her history which is rare instead of more common causes such as shoulder dystosia and cephalopelvic disproportion that cause total uterine prolapse in young patients. In antenatal follow-up of pregnancy, a vaginal examination will decrease morbidity. If vaginal septum is established, it should be operated in the second trimester.

## References

1. Thompson, J. D. Malpositions of the uterus. In: Thompson, J. D. and Rock, J. A. eds. *Telindes Operative Gynaecology*. 7th ed. Philadelphia, J. B. Lippincott, 1992. pp. 819-54.
2. Nichols, D. H. Fertility retention in the patient with genital prolapse. *Am.J. Obstet. Gynaecol.* 1991;

164:1155-58.

3. Nichols, D. H. Massive eversion of the vagina. In: Nichols, D. H. ed. *Gynaecologic and Obstetric Surgery*. Missouri, St. Louis. Mosby, 1993, pp. 431-64

4. Edward, T. A. and Gale, R. P. Comptobrochydactyly: A new autosomal dominant trait with two probable homozygotes. *Am. J. Hum. Genet.*, 1992;24:464-66.

5. Johanson, A. and Blizzard, R. A syndrome of congenital aplasia of the alae nasi, deafness, hypothyroidism, dwarfism, absent permanent teeth and malsorption. *J. Pediatr.*, 1971 ;79:982-85.

6. William, B. F P. Surgical treatment for uterine prolapse in young women. *Am. J. Obstet. Gynaecol.* 1966;95:967-71.

7. Parks, A. O., Swash, M. and Urich, H. Sphincter denervation in anorectal incontinence and rectal prolapse. *Gut*, 1977;18:656-65.