

Accidental Removal of Ureteric Stent

Pages with reference to book, From 45 To 46

A.H. Kardar, B.A.Pettersson (Section of Urology, Department of Surgery (MBC-40), King Faisal Specialist Hospital and Research Centre, Riyadh, Saudi Arabia.)

We report a case where the removal of a nephrostomy tube was inadvertently accompanied by removal of double pigtail ureteric stent.

Case Report

A twenty-four year old woman developed bilateral hydronephrosis and hydroureter. Four weeks earlier she underwent abdominal hysterectomy and bilateral oophorectomy followed by chemotherapy for advanced dysgerminoma of right ovary. Bilateral percutaneous nephrostomy was performed. The right ureter opened up spontaneously while a complete obstruction of the left ureter at the level of iliac vessels was dealt with by ureteroneocystostomy. The anastomosis was protected by a double pigtail stent to be removed three weeks later. On the third postoperative day, while removing the nephrostomy tube, the ureteric stent came out inadvertently, as the pigtail curve of the ureteric stent got entangled with the corresponding curve of the nephrostomy tube (Figure).

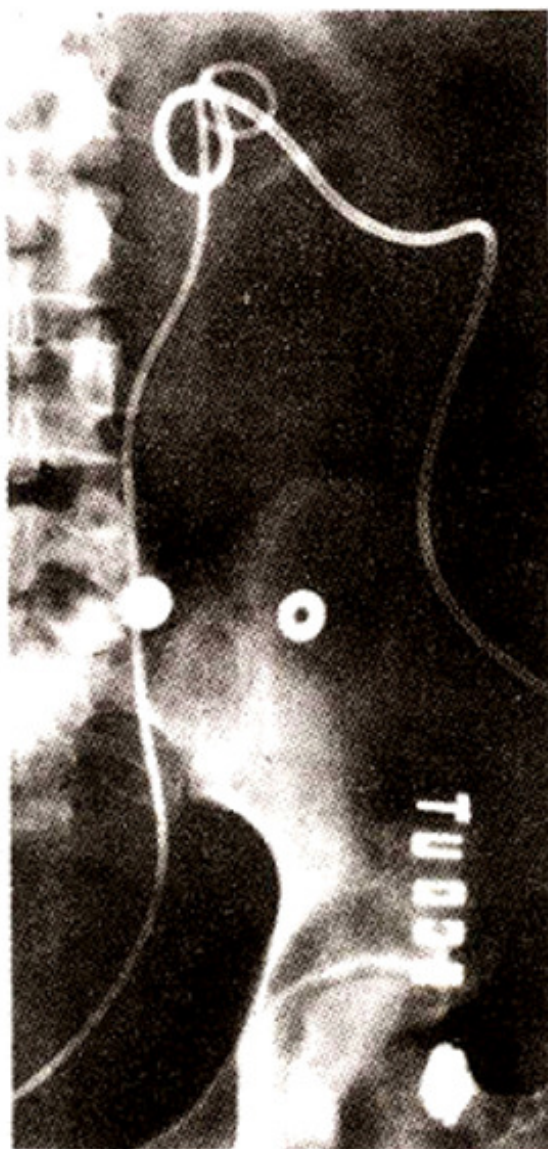


Figure. Radioimage showing nephrostomy tube and J.J. ureteric stent in the left kidney.

She remained completely asymptomatic and five months later renal scan showed good function bilaterally without evidence of obstruction.

Comments

Percutaneous nephrostomy is the most common method of the temporary supravascular urinary diversion². The ureteral stents are commonly used as part of management of renal and ureteric stones, ureteric strictures, pelviureteric junction obstruction and postoperatively to prevent extravasation of urine, fibrosis and subsequent re-strictures¹. It is possible, as happened in our case, for the pigtail curve of the ureteric stent to get entangled with the corresponding curve of the nephrostomy tube in an undilated renal pelvis and the ureteric stent could be removed accidentally during nephrostomy tube removal. Fluoroscopic monitoring of the removal of the nephrostomy tube could therefore, be indicated in certain circumstances especially in solitary kidney situations to prevent accidental removal of the ureteric stent.

References

1. Saltzman, B. Ureteral stents. Indications, variations and complications. *Urol. Clin. North Am.*, 1988;15:481-91.
2. Stables, D.P., Ginsberg, N.J. and Johnson, M.L. Percutaneous nephrostomy: A series and review of the literature. *Am. J. Roentgenol.*, 1978;130:75-82.