

Role of SpyGlass cholangiopancreatography in removal of intraductal foreign bodies

Avais Chatha,¹ Shahzad Iqbal,² Peter Dunsmore Stevens³

Abstract

Intraductal foreign bodies in the pancreatography bile and pancreatic ducts pose a special problem. Routine abdominal imaging, including endoscopic retrograde cholangiopancreatography (ERCP) is very helpful, but is relatively limited by the inability to directly visualise the foreign bodies. Peroral cholangiopancreatography can be helpful in such cases. Here we present two cases where intraductal foreign bodies were successfully removed using the advantage of direct visualisation from SpyGlass cholangiopancreatography system.

Keywords: Cholangiopancreatography, Spyglass, Intraductal foreign bodies.

Introduction

We describe two cases where foreign bodies were successfully removed from the pancreatic and biliary ducts using the advantage of direct visualisation from Spyglass cholangiopancreatography system (Boston Scientific Corp, Natick, MA).

Case-1

A 30-year-old gentleman with a history of abdominal gunshot wound about 5 years ago was admitted with recurrent abdominal pain and elevated liver enzymes. During endoscopic retrograde cholangiopancreatography (ERCP), a foreign body was noted near the hepatic duct bifurcation with upstream dilation of the intra-hepatic biliary tree. The foreign body appeared to move after balloon dilation. However, the exact location could not be determined. A subsequent computed tomography (CT) scan of the abdomen was also not helpful due to metallic artefacts. SpyGlass cholangioscopy was then performed. It revealed fibrous stricture in mid-common bile duct (CBD) and a black metallic object consistent with a bullet inside the bile duct near hepatic duct bifurcation (Figure 1). Since a waist was still seen with 10-mm balloon dilation of the mid-CBD stricture, a 10 mm fully covered metal stent was placed to

^{1,2}Department of Medicine, Winthrop University Hospital, Mineola, NY,
³Department of Medicine, Columbia University Medical Centre, New York, NY.

Correspondence: Shahzad Iqbal. Email: siqbal50@gmail.com

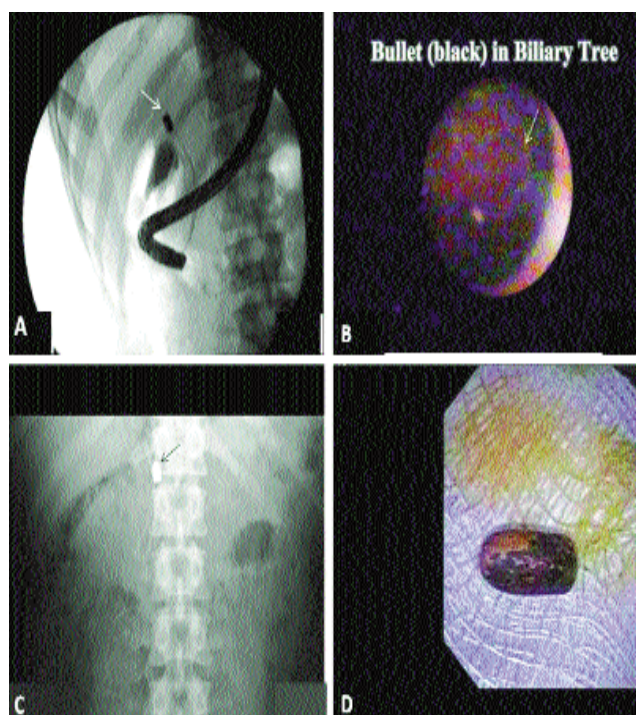


Figure-1: Foreign body in the biliary tree. A: Cholangiogram during ERCP revealed a foreign body (arrow) near hepatic duct bifurcation. B: Spyglass cholangioscopy revealed a black metallic structure (arrow; consistent with bullet) near hepatic duct bifurcation. C: Scout film showed the bullet (arrow) to have migrated down into the fully covered metal biliary stent. D: Successfully removed bullet from the biliary tree.

progressively dilate the stricture. The bullet was later successfully removed using a snare on subsequent ERCP done a few days later.

Case-2

A 65-year-old man with post-transduodenal ampullectomy for tubular adenoma about three months ago, presented with colicky abdominal pain and elevated serum amylase and lipase levels. CT scan of the abdomen showed the pancreas to be unremarkable. However, a linear structure was noted inside the main pancreatic duct. Attempts at removal during ERCP using balloon sweep and biopsy forceps were unsuccessful. SpyGlass pancreatoscopy was performed. It revealed a linear whitish-green structure inside the main pancreatic duct.

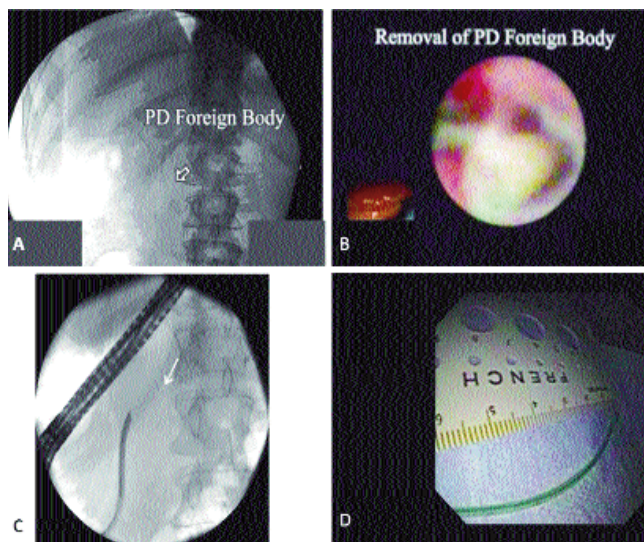


Figure-2: Foreign body in pancreatic duct. A: Scout film of the abdomen shows linear structure (arrow) in mid-abdomen. B: SpyGlass pancreatoscopy revealed whitish-green surgical wire in main duct. C: Fluoroscopic view showing the surgical wire (arrow) next to Spyscope inside the pancreatic duct. D: Successfully removed surgical wire from the pancreatic duct.

The appearance was compatible with a surgical wire that had been left behind (Figure 2). The wire was successfully removed using Spybite forceps.

Discussion

ERCP has been shown to be useful in the retrieval of migrated biliary stents.¹ The SpyGlass peroral cholangiopancreatography is a single-operator semi-disposable system that was introduced about half a decade ago.^{2,3} Due to the ability to directly visualise the intraductal tree, SpyGlass system has been shown to be effective in the removal of bile duct stones,^{4,5} migrated biliary stents,^{6,7} and biopsy of any abnormal lesions.⁸ Intraductal foreign bodies in the bile and pancreatic ducts pose a special problem. Routine abdominal imaging, including CT scan and magnetic resonance imaging (MRI) may not localise the intraductal location of the foreign bodies, as happened in our first case. ERCP is very helpful and has proven effective over the years in removing intraductal foreign bodies. However, it is relatively limited by the inability to directly visualise the foreign bodies and plan effective removal strategy. Peroral cholangiopancreatography is an additional tool, and can

be helpful in cases where routine ERCP fails. SpyGlass cholangioscopy was helpful in our first case in confirming the intraductal (biliary) location and nature of the foreign body (bullet), ultimately leading to the effective removal strategies on subsequent ERCP. In the second case, Spybite forceps were effective in directly removing the iatrogenic pancreatic duct wire. A similar case has been reported where an iatrogenic surgical tube was effectively removed from the bile duct in a post-liver transplant patient initially suspected to be having anastomotic stricture on MRI, using Spybite forceps.⁹

Conclusion

The important diagnostic and therapeutic role of SpyGlass system in suspected intraductal foreign bodies should be emphasised.

Disclosure

This case report was orally presented during the digestive disease week (DDW) annual meeting in the year 2009.

References

1. Sakai Y, Tsuyuguchi T, Ishihara T, Sugiyama H, Eto R, Fujimoto T, et al. Cholangiopancreatography troubleshooting: the usefulness of endoscopic retrieval of migrated biliary and pancreatic stents. *Hepatobiliary Pancreat Dis Int* 2009; 8: 632-7.
2. Chen YK. Preclinical characterization of the Spyglass peroral cholangiopancreatography system for direct access, visualization, and biopsy. *Gastrointest Endosc* 2007; 65: 303-11.
3. Chen YK, Pleskow DK. SpyGlass single-operator peroral cholangiopancreatography system for the diagnosis and therapy of bile-duct disorders: a clinical feasibility study (with video). *Gastrointest Endosc* 2007; 65: 832-41.
4. Draganov PV, Lin T, Chauhan S, Wagh MS, Hou W, Forsmark CE. Prospective evaluation of the clinical utility of ERCP-guided cholangiopancreatography with a new direct visualization system. *Gastrointest Endosc* 2011; 73: 971-9.
5. Seelhoff A, Schumacher B, Neuhaus H. Single operator peroral cholangioscopic guided therapy of bile duct stones. *J Hepatobiliary Pancreat Sci* 2011; 18: 346-9.
6. Maydeo A, Kwek A, Bhandari S, Bapat M, Mathew P. SpyGlass pancreatoscopy-guided cannulation and retrieval of a deeply migrated pancreatic duct stent. *Endoscopy* 2011; (43 Suppl 2 UCTN): E137-8.
7. Kantsevov SV, Frolova EA, Thuluvath PJ. Successful removal of the proximally migrated pancreatic winged stent by using the SpyGlass visualization system. *Gastrointest Endosc* 2010; 72: 454-5.
8. Iqbal S, Stevens PD. Cholangiopancreatography for targeted biopsies of the bile and pancreatic ducts. *Gastrointest Endosc Clin N Am* 2009; 19: 567-77.
9. Ransibrahmanakul K, Hasyagar C, Prindiville T. Removal of bile duct foreign body by using spyglass and spybite. *Clin Gastroenterol Hepatol* 2010; 8:e9. doi: 10.1016/j.cgh.2009.08.033.