

'Menouria' - A Presentation of Vesicouterine Fistula

Pages with reference to book, From 159 To 161

Shereen Zulfiqar Bhutta (Department of Obstetrics and Gynaecology, Jinnah Postgraduate Medical Centre, Karachi.)

Vesicouterine fistulae account for 4% of genitourinary fistulae¹. They are primarily a complication of lower segment Caesarean section and were extremely rare till 1947². The incidence has gone up since then, because of increasing rates of Caesarean sections²⁻⁵. Unlike other genitourinary fistulae, urinary incontinence is not an integral feature of vesicouterine fistula^{1,2,4,6}. When the defect is above the level of internal os, the woman is continent but the menstrual flow is diverted to the bladder causing haematuria. This phenomenon of cyclic haematuria, apparent amenorrhoea, in the presence of a patent cervix with urinary continence is referred to as Youseff's syndrome⁷. Youseff coined the term 'Menouria' for vesical menstruation in these cases. This article describes five women with Menouria presenting to the department of Obstetrics and Gynaecology, Jinnah Postgraduate Medical Centre, Karachi over the last seven years.

Case Reports

Case 1

A 28 year old para 3+0 presented with painless haematuria lasting 5 days for the last 3 months. The last delivery was 8 months earlier, her third Caesarean section with tubal ligation. There was no other urinary complaint. She was amenorrhoeic since delivery. Physical examination, laboratory investigations and intravenous pyelogram (IVP) were unremarkable. Ultrasound examination showed a communication between the bladder and uterus just above the cervix (Figure 1).

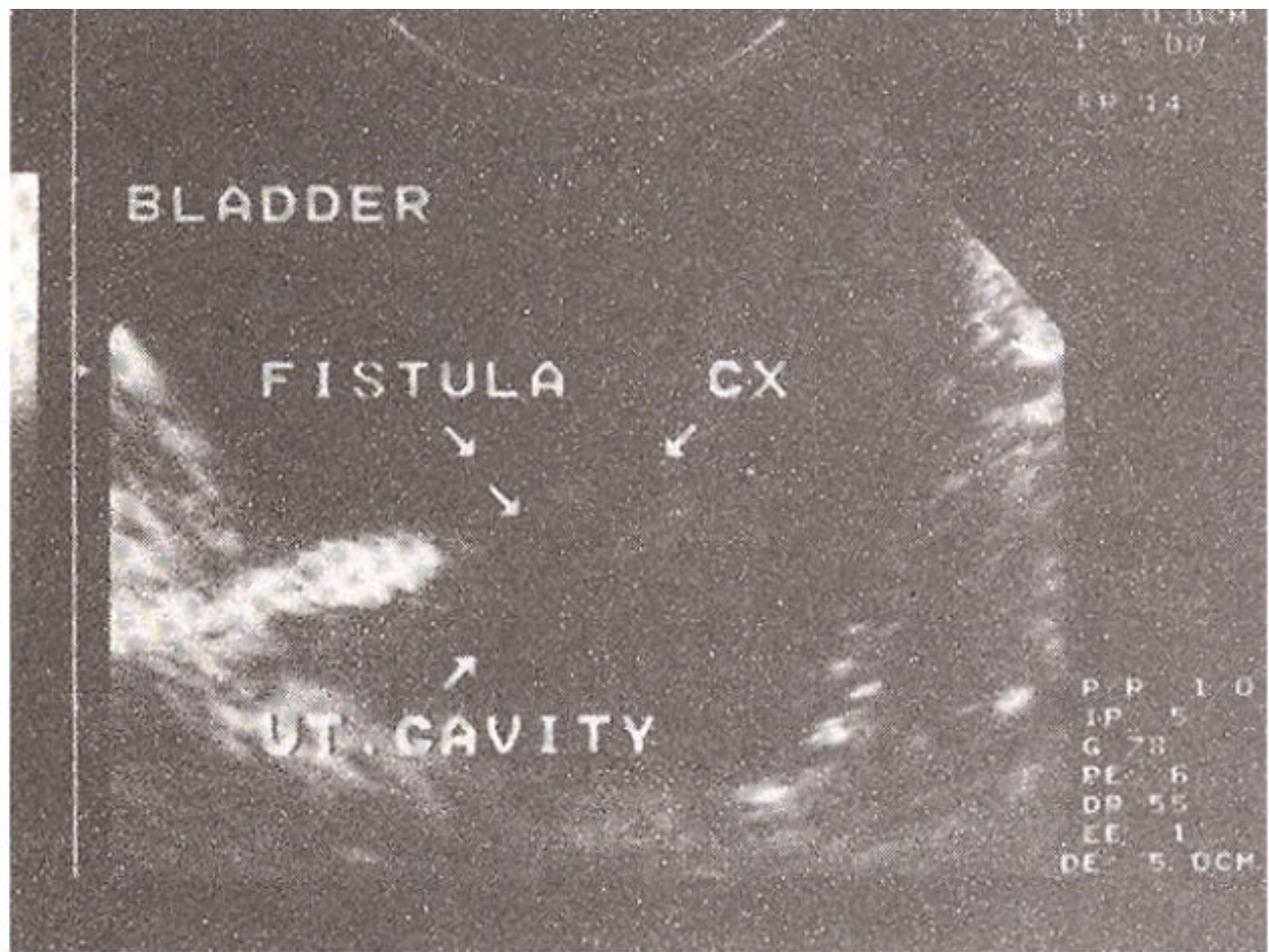


Figure 1. Ultrasound scan showing a fistula between the bladder and uterus above the level of the internal os.

This was confirmed by hystero-graphy and cystoscopy. A total abdominal hysterectomy with bladder repair in two layers was done. The bladder was drained for 10 days with a Foley's catheter. She remains free of symptoms 7 years later.

Case 2

A 41 year old para 6+0 admitted in shock following prolonged obstructed labour at home, had emergency laparotomy. The stillborn foetus weighing 4.2 kg was removed from the peritoneal cavity. The transverse rupture in the lower uterine segment resembling a Caesarean section incision, as well as a 4 cm transverse rupture in the bladder base were repaired in two layers and tubal ligation was done. Bladder was drained continuously with a Foley's catheter. Despite a patent catheter, urinary leakage through the vagina was noticed on the seventh post-operative day. A gentle examination through the still open cervical os revealed the bulb of the catheter palpable through a small defect through the site of the rupture. Bladder drainage was continued for another three weeks. Urinary leakage ceased and she went home completely continent. She reported back after 12 weeks, with two episodes of frank haematuria lasting 4 days at a month's interval. Cystoscopy showed a 2 cm central vesicouterine fistula 2 cm above the trigone. The patient refused further evaluation and treatment. She remains well 6 years later with persistent cyclic haematuria, preferring it to the previous more cumbersome way of managing her menstrual periods.

Case 3

A 22 year old para 2+0 had delivered by second Caesarean section 9 months back. For the last 3 months she had frank painless haematuria lasting 4 to 5 days every month and was amenorrhoeic since

Caesarean section. The physical examination, laboratory investigations and IVP were normal. Cystoscopy showed a 1 cm vesicouterine fistula 1.5 cm above the trigone and hystero-graphy demonstrated spill of contrast medium into the bladder (Figure 2).

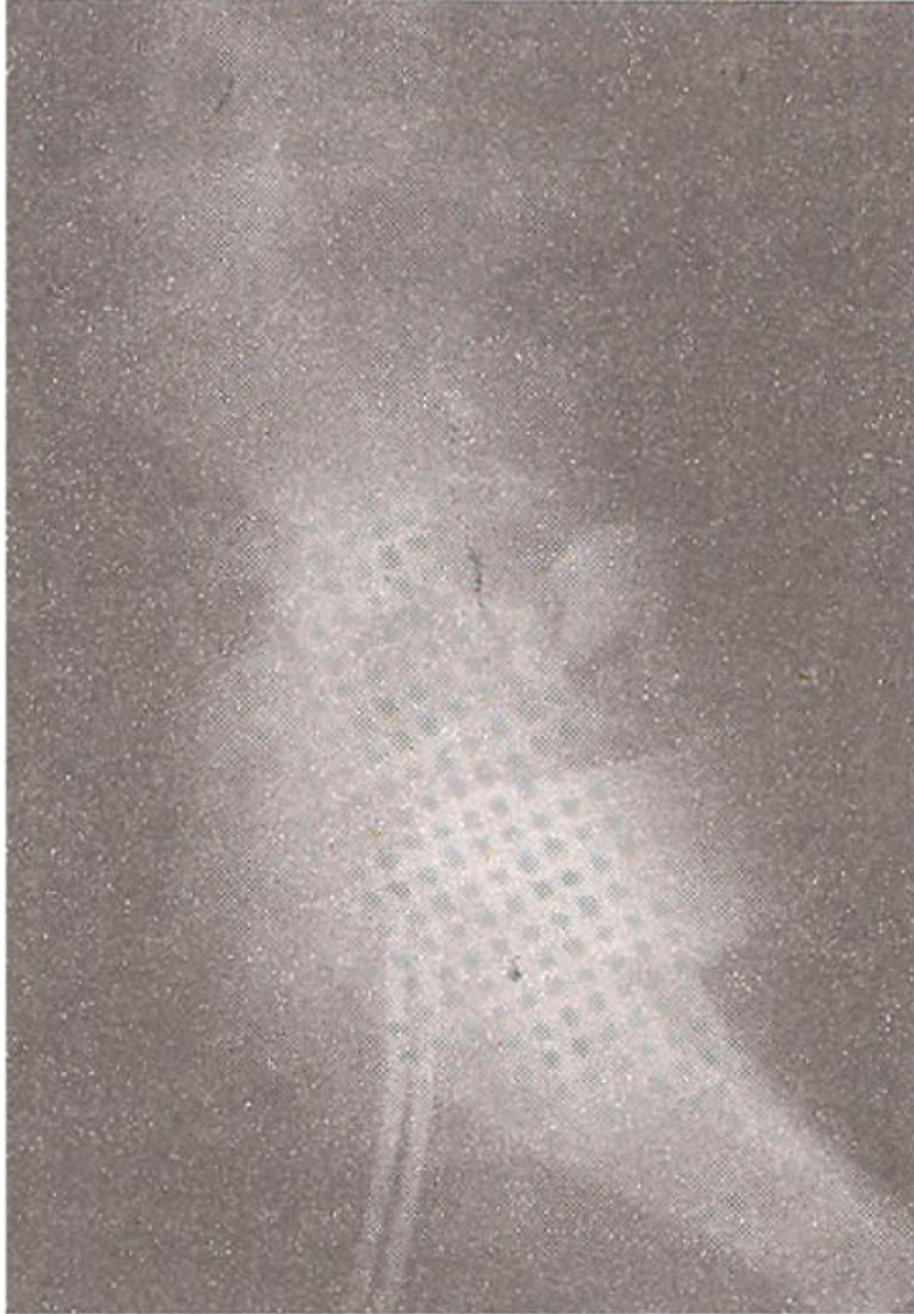


Figure 2. Lateral view X-ray of the pelvis taken after instilling the contrast medium in the uterus through the cervix. The medium can be seen in the bladder

She was prescribed the combined oral contraceptive containing 0.05mg oestradiol, continuously for 6 months to suppress menstruation. She remained asymptomatic during this period but haematuria recurred on stopping the pill. Repair was carried out through the transabdominal transperitoneal route, exposing the fistulous tract, mobilising the bladder off the uterus, cervix and upper vagina. Both the organs were repaired in two layers. The bladder was drained for 12 days by Foley's catheter. Normal menstruation resumed following surgery. She has subsequently had delivery of a term baby by elective caesarean section along with tubal ligation.

Case 4

A 26 year old para 1+0 had an elective caesarean section for breech presentation 10 months earlier. She presented with painless gross haematuria lasting 6 days on two occasions a month apart and was amenorrhoeic since Caesarean section. No abnormality was detectable on examination, laboratory investigations and IVP. Cystoscopy showed a 0.5 cm vesicouterine fistula 2 cm above the trigone, which was also demonstrable on hystero-graphy (Figure 3).



Figure 3. The presence of contrast medium in the bladder on hystero-graphy confirms the presence of vesicouterine fistula despite urinary continence.

Continuous administration of the combined oral contraceptive containing 0.05 mg oestradiol, resulted in resolution of cyclic haematuria and return of normal menstruation. She has since had a live birth by an elective Caesarean section at term and remains free of symptoms.

Case 5

A 26 year old para 2+0 had second Caesarean section 20 months earlier. She remained amenorrhoeic after stopping breast feeding but had frank painless haematuria every month lasting 3 to 4 days. The

examination and IVP were uninformative. Ultrasound cystoscopy and hystero-graphy confirmed the fistula between the bladder base and uterus above the cervix. Examination under anaesthesia after instilling 150 ml of dye showed no abnormality, but on putting another 300 ml of dye into the bladder, the same was seen escaping through the cervix⁷. A transperitoneal abdominal repair of the bladder and uterus after adequate mobilisation was carried out in two layers (Figure 4).

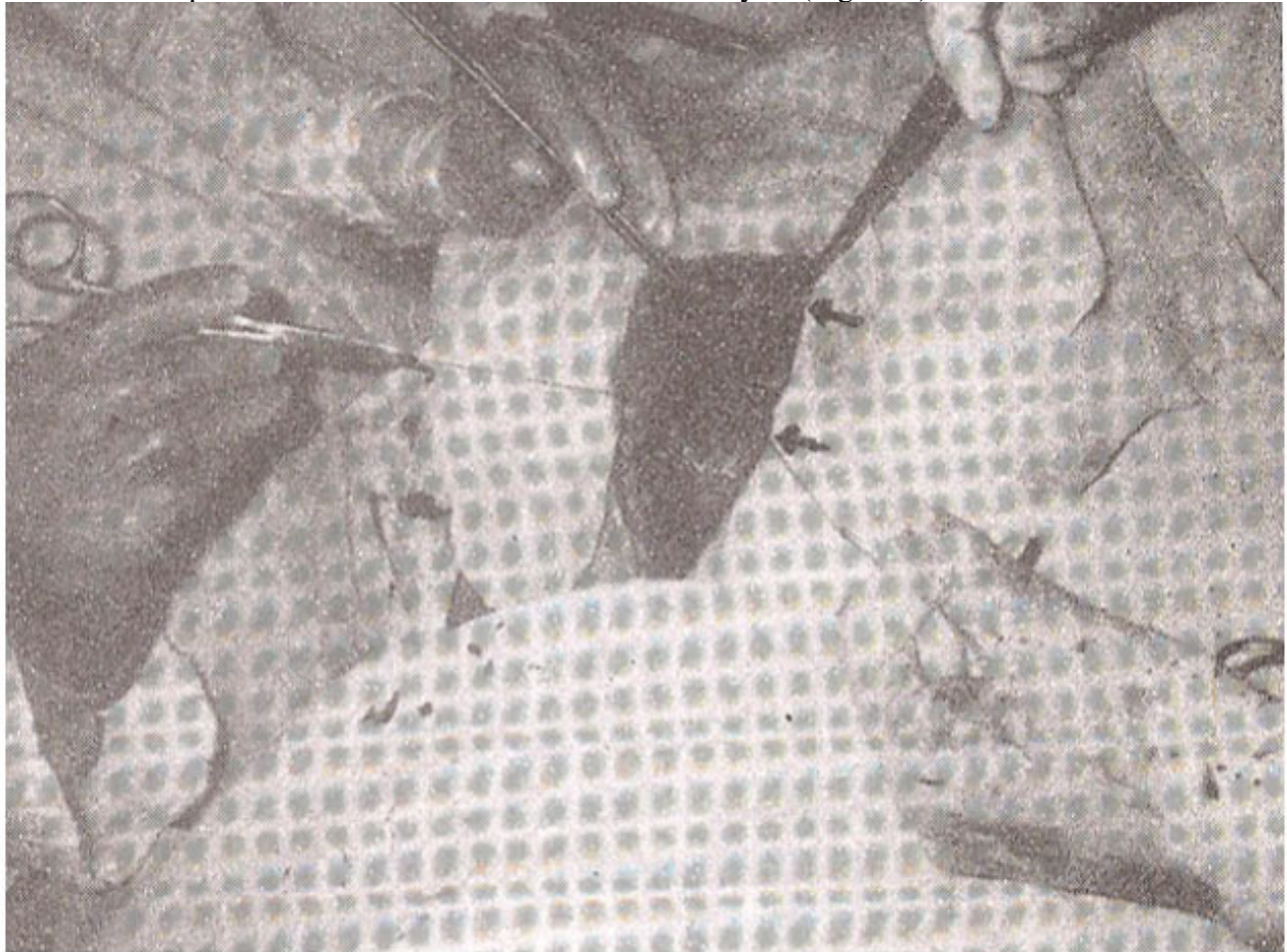

Figure 4. Transabdominal transperitoneal repair of the fistula done after mobilising the bladder off the uterus, cervix and upper vagina. the arrows indicate suture lines in the bladder and uterus after repair.

Foley's catheter was left in the bladder for 12 days. There was no haematuria post-operatively and normal menstruation resumed. The couple are using barrier contraception presently.

Discussion

A vesicouterine fistula presenting with vesical menstruation and urinary continence was first reported in 1935⁸. Various mechanisms have been postulated for this. These include the presence of an isthmic sphincter⁷, granulations on the posterior uterine wall occluding the internal uterine orifice^{1,9} and the intrauterine pressure being higher than the intravesical pressure⁶. Diagnosis can be made by a non-invasive technique like ultrasound, as in two of our cases, but the mainstay remains hystero-graphy and cystoscopy. The latter is essential to determine the exact location of the fistula in the bladder and determine its relationship to the ureteric orifices. An IVP may not assist in diagnosis, but is mandatory to know the status of the upper urinary tract.

Spontaneous closure of the fistula has been reported^{4,10-13} and is worth waiting in fistulae presenting early. Suppression of menstruation with hormone therapy is another conservative treatment associated with favourable outcome^{3,5,7} and cured one of our patients. Interestingly vesical menstruation itself does not necessarily cause harm¹⁴⁻¹⁷.

Cystoscopic fulguration of the fistula is a feasible option¹⁸ for women not desiring further pregnancies³. An other alternative for them is abdominal hysterectomy and bladder repair. For those who wish to retain fertility, repair should be able to withstand the stress of subsequent pregnancies. This is best carried out transperitoneally through the abdominal route, with or without an interposed omental graft¹⁻³. Fertility following repair was thought to be extremely low¹⁹, but this is not corroborated by others²⁰ or us. The two women in this report who had subsequent pregnancies conceived within three months of discontinuing contraception.

Vesicouterine fistula is a rare but largely preventable complication of Caesarean section. Complete preoperative emptying and adequate intraoperative reflection of the bladder from the uterus, with timely recognition and repair of any injury to the bladder minimises such complications.

References

1. Lenkovsky, Z., Pode, D., Shapiro, A. et al. Vesicouterine fistula: A rare complication of caesarean section. *J. Urol.* 1988; 139:123-5.
2. Tancer, M.L. Vesicouterine fistula - A review: *Obstet. Gynecol., Surv.*, 1986;41:743-53.
3. Thanos, A., Paviakis, A.J. and Davillas, N. Vesicouterine fistula, *Urology*, 1986;28:426-8.
4. Raunch, R.J., Rodgers, MW. Spontaneous closure of a vesicouterine fistula following caesarean section. *JAMA* 1962,181:997-9.
5. Rubino SM. Vesicouterine fistula treated by amenorrhoea induced with contraceptive steroids. Two case reports. *Br. J. Obstet. Gynecol.*, 1980;87:343-44.
6. Hemel, A.K., Wadhwa, S.N., Kriplani, A. et al. Youseff's syndrome: An appraisal of hormone treatment. *Urol. Int.*, 1994;52:55-7.
7. Youseff, A.F. Menouria following lower segment caesarean section. *Am. J. Obstet. Gynecol.* 1957;73:759-67.
8. Machado, L.M. Vesico-cervical fistulas after caesarean section. *Rev. Fr. Gynecol. Obstet* 1935:29-471.
9. Hudson, C.N. Vesicouterine fistulas after caesarean section *J. Obstet. Gynecol. Brit. Comm. With.*, 1962;69:121-4.
10. Sims, G.K. Spontaneous healing in a vesicouterine fistula following labor: Report of a case. *JAMA* 1928;90:759-60.
11. Frankel T and Buchsbaum, H.J. Vesicocorporeal fistula with menouria. *J. Urol.*, 1971;106:860-1.
12. Grazzioti, P., Lanbo, A. and Artibani, W. Spontaneous closure of a vesicouterine fistula after caesarean section. *J. Urol.*, 1978; 120:372.
13. Buchspan, M.B., Simha, S. and Klotz, P.G. Vesicouterine fistula: A rare complication of caesarean section. *Obstet. Gynecol.* 1983;62:645-665.
14. Burr, G.C. Uterovesical fistula. *J. Urol.*, 1939;41 :906.
15. Medeiros, A., De, S. and Guimaraes, M.V. Youseff's syndrome: A case report. *J. Urol.*, 1973;109:828-9.
16. Bond, W. and Rogers, G. Unusual vesicouterine fistula. *Am. J. Obstet. Gynecol*, 1952;63:2 15-6.
17. Falk, H.C. and Tancer, M.L. Management of vesical fistulas after cesarean section. *Am. J. Obstet. Gynecol.*, 1956;71:97-106.
18. Molina, L. R., Lynne, C.M. and Politano, V.A. Treatment of vesicouterine fistula by fulguration. *J.*

Urol., 1989;141 :1422-3.

19. Dubbuisson, J.B., Barbot, J. and Santarelli, J. Les fistules vesico-uterines apres operation cesarienne, J. Gynecol. Obstct. Biol Reprod. (Paris), 1979;8:229.

20. Issa, M.M., Schmid, H.P. and Stamey, TA. Youseff's syndrome: Preservation of uterine function with subsequent successful pregnancy following surgical repair. Urol. Int., 1994;52:220-2.