

The Extranasal Glioma - A Cause of Neonatal Respiratory Distress

Pages with reference to book, From 61 To 62

Amanullah, M.M. Moazam, F. Attar. Z (Department of Surgery, The Aga Khan University Hospital, Karachi.)

Introduction

Normal brain tissue in an abnormal configuration, occurring at a site away from the cranial cavity, is termed an Extranasal Glioma. Since its first description in 1852 by Reid², only 140 patients with this entity have been reported.

Heterotopic brain tissue when present in a confined area may cause obstruction, pressure and pain. Its occurrence in the nasopharyngeal region is relatively rare and only 19 cases have been reported so far², the majority presenting with respiratory distress in the early neonatal period. The objective of this report is to create an awareness amongst the physicians of the presentation and management of this condition.

Case Report

A twenty-five day old female infant attended the emergency room at The Aga Khan University Hospital with tachypnea and respiratory distress. Noisy breathing was present since birth, but had recently increased in intensity. The mother reported of episodes of apnea and cyanosis during feeding and crying since 10 days and she had noticed a swelling in the infant's palate.

On examination, the patient weighed 2.3 kgs. She was breathing through an open mouth with a loud inspiratory stridor. There was a visible tracheal tug and intercostal recessions. Examination of the mouth revealed a large, smooth swelling involving the soft and hard palate, occupying a large part of the oropharynx and almost touching the posterior third of the tongue. The swelling was covered by normal appearing oral mucosa.

A complete blood picture had normal values. Arterial blood gases showed a pH of 7.3. pCO₂ of 52.5 mmHg, pO₂ of 50.6 mmHg, HCO₃ of 26.8 meq/L and an O₂ saturation of 82.2%.

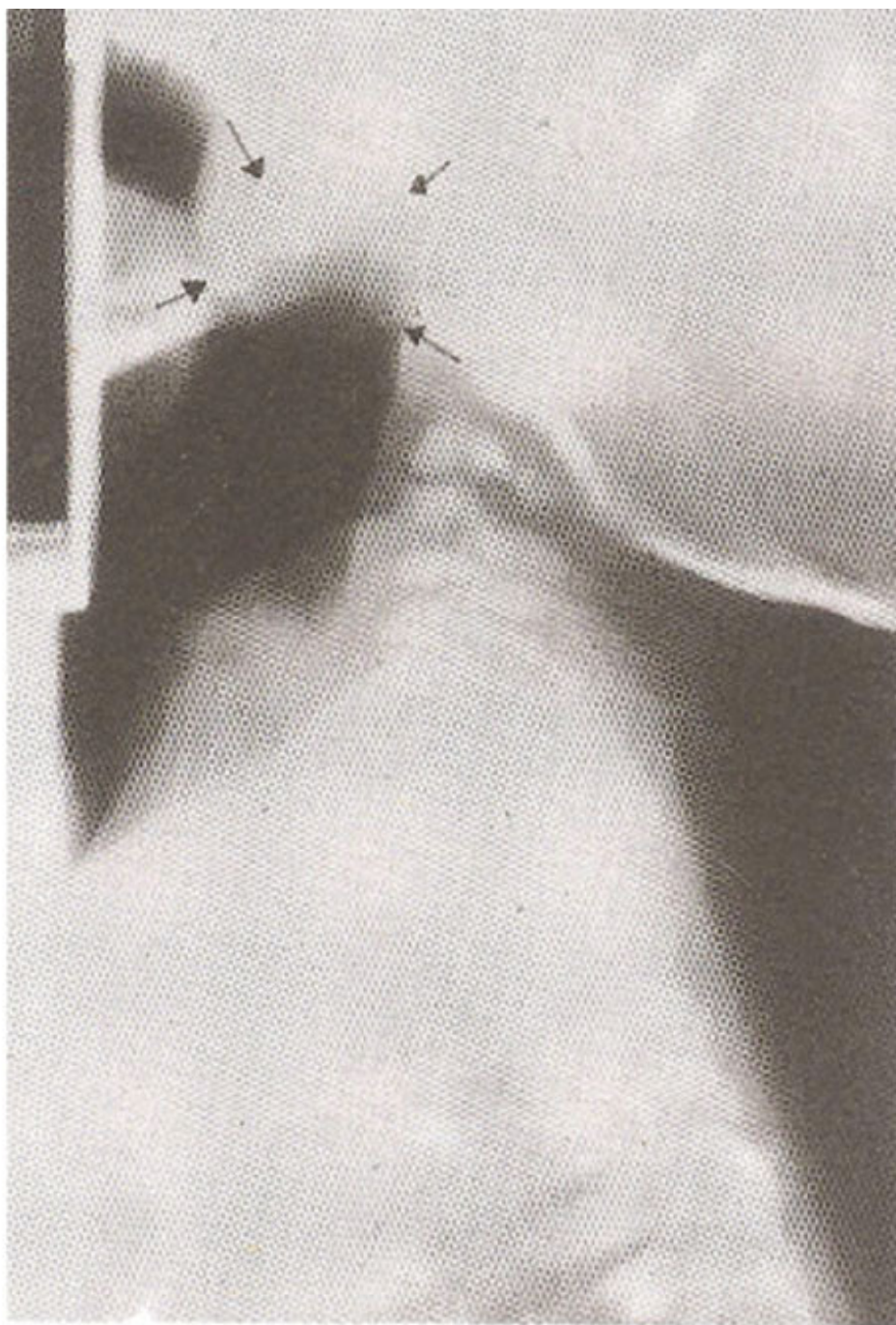


Figure 1. Plain X-ray neck, lateral view. Arrows marking the soft tissue shadow, which is nearly occluding the nasopharynx.

X-rays of the neck (Figure 1) revealed a soft tissue density almost occupying the entire nasopharynx. Examination under anesthesia confirmed a smooth, cystic mass in the nasopharynx displacing the palate down-wards. Aspiration of the mass gave bloody fluid and the cyst collapsed improving the respiratory status of the patient temporarily. A CT-scan of the head and neck (Figure 2)

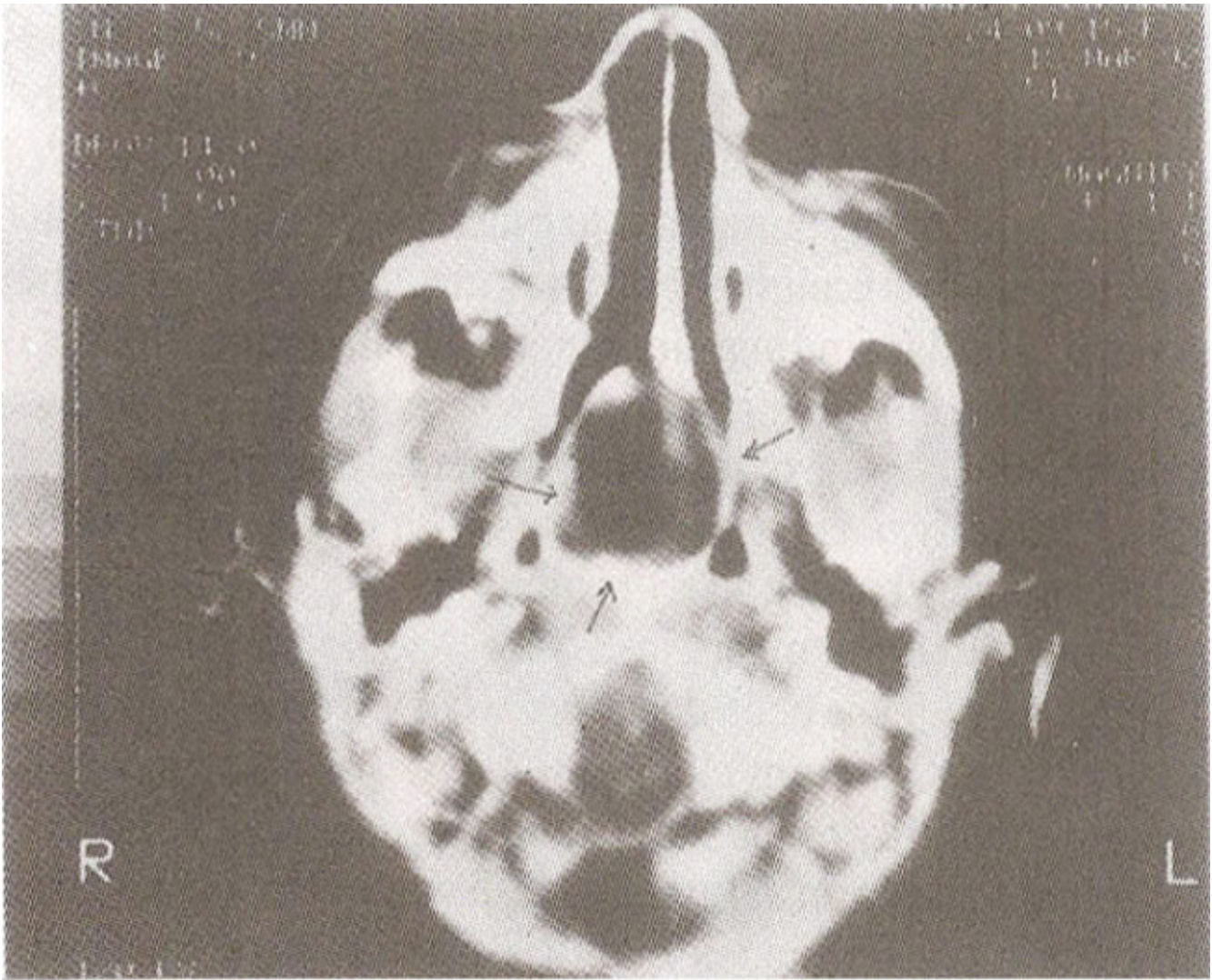

Figure 2. CT-Scan of the oropharynx. Arrows mark the tumour occupying the posterior nasal choanae. There is no intracranial communication.

confirmed a 2 cmx2.5 cm cystic mass with smooth margins. arising from the posterior nasal septum and attached to the base of the skull. There was no obvious intracranial communication.

The patient underwent excision of the mass through a transpalatal approach. The mass was found adherent to the right side of the nasal septum in close proximity to the base of the skull and was excised in toto. The histopathological examination of the tissue confirmed an Extranasal Glioma (heterotopic brain tissue) consisting of choroid plexus, ependymal like epithelium, glial tissue (astrocytes), with no evidence of malignant cells. Special immunoperoxidase staining confirmed neural tissue with the presence of glial fibrillary acidic protein.

The patient had an uneventful post-operative recovery and is doing well, with no respiratory symptoms three years following surgery.

Discussion

Heterotopic brain tissue results from embryonic brain tissue trapped in inappropriate areas during development. This entity was first described by Reid in 1852¹ and in 1890 Schmidt first described nasal gliomas³. To date 140 patients with heterotopic brain tissue have been reported. Among them,

60% were extra-nasal, 30% nasal and 10% mixed⁴. The extra-nasal sites included the chest wall, tongue, eyelid, oropharynx, submandibular region, subcutaneous tissue and the palate^{2,5-10}. There is a slight male preponderance^{2,4}.

Heterotopic brain tissue may become symptomatic at an older age due to its relatively slow growth. However, if located in the head and neck region, respiratory and feeding difficulties appear soon after birth. Of the 19 reported cases of heterotopic brain tissue involving the palate and nasopharynx, 15 presented with respiratory difficulty. All but two, presented during the first month of life, with symptoms similar to the case reported here. Two of the 19 cases, had neoplastic nodules within the mass². Three newborns with respiratory distress died before surgical intervention and the nasopharyngeal masses were discovered at autopsy.

Approximately, 20% of gliomas found in the nose, have a fibrous intracranial connection, although this is less common with extranasal gliomas. Unlike nasal gliomas, extra-nasal gliomas contain a combination of choroid plexus, cyst formation, ependymal like tissue, nasal substance and micro-calcific bodies. The glial tissue predominantly astrocytes is common to both. Rarely, neoplastic changes have been observed in extra-nasal gliomas².

Although the diagnosis can usually be made clinically, magnetic resonance imaging or computerized tomography can be helpful in assessing the extent of the mass and the presence of intracranial connections.

Both nasal and extra-nasal gliomas should be completely excised to prevent recurrence from residual tissue. Craniotomy may be necessary for complete excision, if there is an intracranial extension. The temptation to aspirate cystic masses in the nasopharynx should be avoided as in the presence of intracranial connection; this may lead to meningitis.

Though rare, if not diagnosed early, heterotopic brain tissue in the nasopharyngeal region can be a cause of significant morbidity and mortality. This entity should be considered in the differential diagnosis of neonates presenting with the onset of respiratory distress soon after birth.

References

1. Reid, F. Uber ausgeborene Hirnbrucke in den Stirn und Nasengegend. *Illustrierte. Med.Ztg.*, 1852;1:133-141.
2. Bossen, E.H and Hudson, W.R. Oligodendroglioma arising in heterotopic brain tissue of the soft palate and nasopharynx. *Am. J. Surg. Pathol.*, 1987; 11:571-574.
- 3 Schmidt, MB. Uber seltene spaltbildungen im Bereiche des mittleren Stirnfortsatzes. *Virchows Arch. (A)*, 1890; 162: 340-370.
4. Hendrickson, M., Fayc-Petersen, O. and Johnson, DG. Cystic and solid Heterotopic brain in the face and neck, A review and report of an unusual case. *J. Pediatr. Surg.*, 1990;25:766-768.
5. Gibbs, A.R. and Fuller, C. Heterotopic brain tissue in the lung causing acute respiratory distress in an infant. *Thorax.* 1989;44: 1045-1046.
6. Landini, G., Kitano, M., Urago, A. et al. Heterotopic central neural tissue of the tongue. *Int. J. Oral Maxillofac. Surg.*, 1990;19:334-336.
7. Holbach, L.M., Naumann, GO. and Font, R.L. Neuroglial choristoma presenting as congenital lid tumor. *Greef. Arch. Clin. Exp. Ophthalmol.*, 1989;227:584-588.
8. Momose, F., Hashimoto, K. and Shioda, S. Heterotopic brain tissue in the oropharynx. Report of a case. *Oral Surg. Oral Med. Oral Pathol.*, 1989;68:682-685.
9. Misra, BK, Shaw, J.F. and Gordon, A. Heterotopic brain cyst from middle cranial fossa to submandibular region. *Childs New. Cyst.*, 1987;3:297-300.
10. Shepherd, NA., Coates, P.J. and Brown, A.A. Soft tissue gliomatosis -heterotopic glial tissue in the subcutis. A case report. *Histopathology*, 1987; 11:655-660.

11. Rakestraw, M.R., Masood, S. and Ballinger, W.E. Brain heterotopia and anencephaly. Arch. Pathol. Lab. Med., 1987;111:858-860.