

Management of acute myocarditis in children

Quratulain Merchant,¹ Anwarul Haque,² Babar Sultan Hasan³

Abstract

Myocarditis is defined as the inflammation of the myocardium. It continues to be a significant cause of morbidity and mortality in the paediatric population and is the commonest cause of cardiac failure in a healthy child. Some studies estimate the incidence of myocarditis to be around 1 per 100 000. PubMed search was performed using the term 'myocarditis.' The search was limited to age 0-19 years. A total of 50 articles were identified between 1966 to date and reviewed. Myocarditis is a challenging diagnosis to make on clinical grounds and requires high index of suspicion. The cornerstone of treatment remains supportive though therapeutic modalities such as immunosuppressive and intravenous immunoglobulin therapies are being studied extensively. The overall prognosis of the disease is good with survival rates up to 80%.

Keywords: Myocarditis, Paediatric population, PubMed.

Introduction

Myocarditis, or inflammatory cardiac myopathy, is defined as the inflammation of the myocardium in association with myocellular necrosis and degeneration.¹ It can either be focal or diffuse and can lead to cardiac dysfunction. Myocarditis continues to be a significant cause of morbidity and mortality in the paediatric population and is the commonest cause of cardiac failure in a healthy child.² Sub-clinical presentation of the disease leading to under-diagnosis makes it difficult to determine the true incidence of myocarditis. However, it accounts for 12% of sudden cardiac deaths in adolescents and young adults.³

The clinical presentation of myocarditis has a broad spectrum of signs and symptoms as it varies from asymptomatic cases to complete cardiovascular collapse (referred to as acute fulminant myocarditis).⁴ The main causative agent is a virus, Cocksackie type B virus being the most common, but it can also be due to bacterial infections, immune-mediated and toxic/hypersensitivity reactions.^{2,3}

¹Medical Student, Aga Khan University Medical College, ^{2,3}Department of Paediatrics and Child Health, Aga Khan University, Karachi, Pakistan.

Correspondence: Babar Sultan Hasan. Email: babar.hasan@aku.edu

Myocarditis can be regarded as a precursor to dilated cardiomyopathy (DCM), which is the most frequent cause of heart transplantation.^{5,6} Endomyocardial biopsy (EMB), tissue histology using the 'Dallas criteria' and immunological staining may still be the definitive test for diagnosing myocarditis.^{7,8} The mainstay of treatment is supportive and symptom-based care, though mechanism-based therapy has its role in specific cases of myocarditis.⁹

Aetiology

A broad array of infectious, immune-mediated and drug hypersensitivity causes are implicated in cases of myocarditis (Table-1). Out of these, majority of the cases

Table-1: Causative agents of myocarditis in children.

Infectious	Schistosomiasis
Viruses	
Cocksackie B	Immune-mediated
Adenovirus	SLE (Systemic Lupus Erythematosus)
Echovirus	Rheumatic fever
Hepatitis virus	Rheumatoid arthritis
Herpes simplex virus	Inflammatory bowel disease
Epstein Bar virus	Sarcoidosis
Parvovirus	Churg-Struss syndrome
HIV	Diabetes mellitus
Influenza virus	Thyrotoxicosis
Poliomyelitis	Wegner's disease
Mumps	
Rubella	
Bacteria	
Streptococcus	Toxic/Hypersensitivity
Mycoplasma bacteria	Amphotericin B
Legionella	Tetracyclines
Treponema pallidum	Sulfonamides
Mycobacterium species	Diuretics
Rickettsial	Cephalosporin
Rickettsia rickettsii	Cyclophosphamide
Fungi	Ethanol
Candida	Heavy metals
Histoplasma	Cocaine
Cryptococcus	Anthracycline
Protozoal/Parasites	
Trypanosoma cruzi	
Toxocara canis	

in the paediatric population are caused by viral infections like Adenovirus, Epstein-Barr virus and, most importantly, Coxsackie virus type B.³ However, with the advent of newer diagnostic modalities, including polymerase chain reaction (PCR) and EMB, Parvovirus B19 and Human Herpes Virus 6 were also detected in a number of patients with biopsy-proven myocarditis in European studies.¹⁰ Although myocarditis is a very common cardiac pathological autopsy finding in adult patients diagnosed with human immunodeficiency virus (HIV) (up to 50-70% of the cases),¹¹ it remains uncommon among HIV-infected children. In these patients, cytomegalovirus and adenovirus are found in histologically-proven myocarditis, raising the question whether HIV or secondary viruses are the culprits behind high incidence of myocarditis in an immunocompromised host.⁸ Moreover, in the developing world, mumps, poliomyelitis and rubella may be the other contributing organisms leading to the development of myocarditis, especially in unvaccinated children.

Pathogenesis

The progression of myocarditis, as demonstrated by Murine models,⁵ can be divided into three recognised phases: an acute phase caused by direct cellular damage by the infectious agent; a sub-acute phase which involves innate host immune response against virus infested cells; and chronic phase which leads to DCM.^{1,5}

The acute phase is characterised by direct myocellular invasion by cardiotropic viruses via receptor-mediated endocytosis and rapid viral replication, leading to myocellular necrosis and apoptosis.³ A specific Coxsackie virus-Adenovirus Receptor (CAR), member of the immunoglobulin superfamily, appears to mediate this attachment in cases of viral myocarditis caused by Coxsackie virus and Adenovirus. The expressions of these receptors therefore determine an individual's susceptibility to viral myocarditis. The acute phase lasts only a few days (Figure-1).

The acute phase is followed by rapid progression to host's

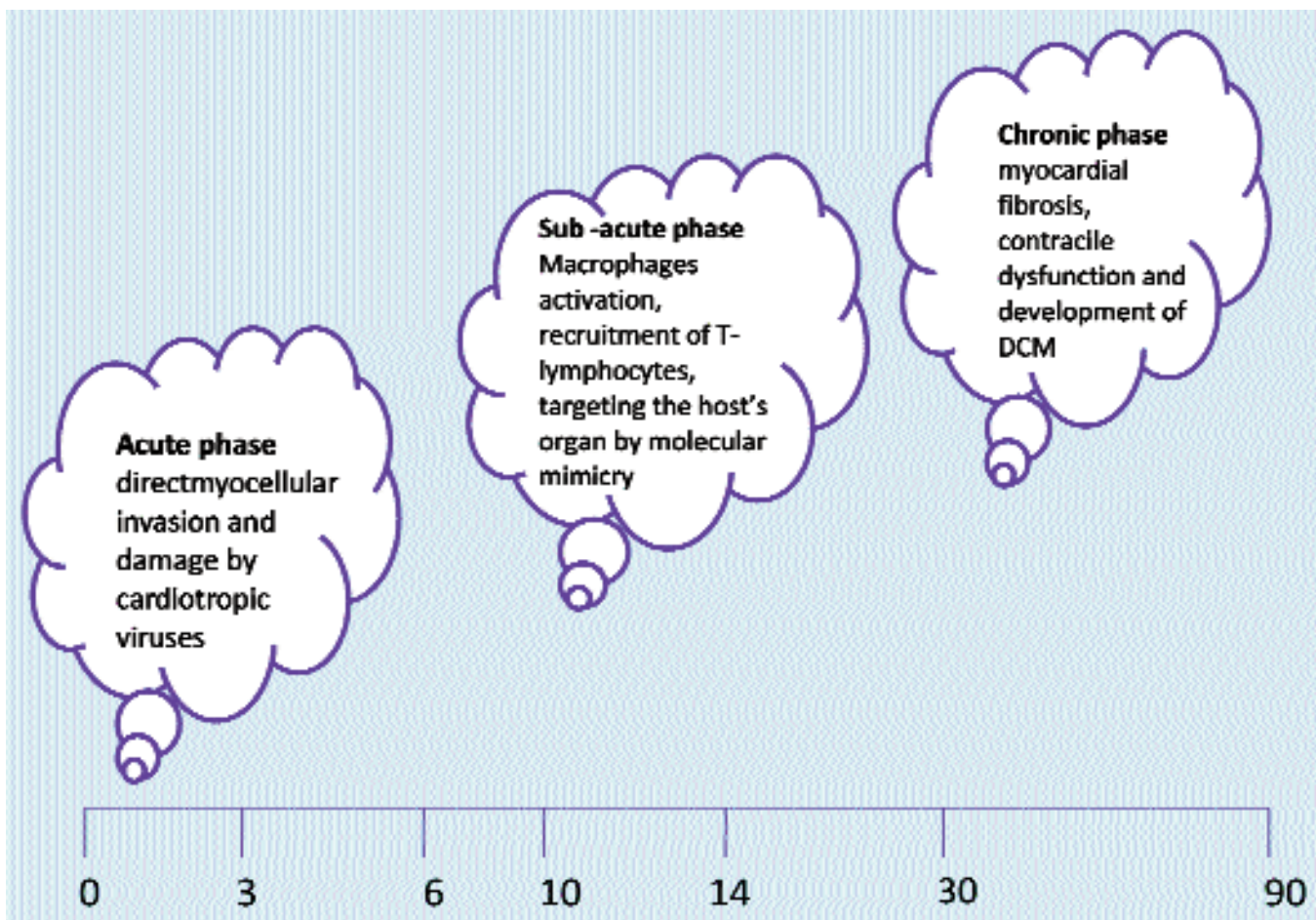


Figure-1: Time line of Viral Myocarditis (days).

DCM: Dilated cardiomyopathy.

immune cascade, known as the sub-acute phase of the disease. Macrophage activation, due to cardiotropic viruses, leads to production of inflammatory cytokines, interleukin 1 β (IL1 β), IL2 and tumour necrosis factor-alpha (TNF- α), which cause recruitment of T lymphocytes and natural killer (NK) cells. The T lymphocytes play a pivotal role in this immune cascade by targeting the myocardium by molecular mimicry, causing further myocardial damage.¹² Both cell-mediated immunity and humoral immunity play a role in this phase of the disease. In addition to production of pro-inflammatory cytokines, titres of protective anti-inflammatory cytokines also rise, suggesting interplay between pro- and anti-inflammatory cytokines¹³ during this phase of myocarditis. It has also been found that sub-acute phase is the most destructive phase of myocarditis and can last from a few weeks to several months. Decrease in viral load in this phase is associated with recovery of left ventricular (LV) function.⁵

In majority of the cases where insult to myocardium is limited, the heart function recovers within a few months, but in cases with more extensive myocardial insult, chronic myocarditis may develop. This third phase of the disease, the chronic phase, is characterised by myocardial fibrosis and development of DCM.¹ This involves chamber dilation and ventricular wall thinning with impairment of the contractile function of the heart, leading to permanent damage with scar tissue replacing the necrotic myocardium.²

Clinical Presentation

The clinical presentation of myocarditis has a broad spectrum of signs and symptoms as it varies from asymptomatic cases to mild lethargy, dysrhythmias, complete cardiovascular collapse and death.^{4,10} Myocarditis can be broadly divided into fulminant, acute and chronic presentation.¹⁴ Fulminant myocarditis is characterised by sudden onset of severe haemodynamic compromise following a viral infection. Though more dramatic in its presentation, if managed aggressively with early mechanical support using extracorporeal membrane oxygenator (ECMO), fulminant myocarditis patients may have full recovery and less risk of developing DCM.¹⁵ Acute myocarditis follows a less distinct onset, initially with less severe compromise, but may lead to worse outcome than fulminant myocarditis, with the development of DCM. D'Ambrosio et al showed that 21% of diagnosed cases of acute myocarditis developed DCM over a mean follow-up of 3 years.¹⁶ Chronic myocarditis can be labelled so if it persists for more than 3 months.¹⁷

Clinical presentation also varies in different age groups (Table-2).⁷ Neonates usually present with non-specific

Table-2: Clinical presentation of myocarditis in different age groups.

Neonates	Nonspecific signs: fever, irritability, pallor, poor feeding Ominous signs: apnoea, episodic cyanosis
Young children and adolescents	Nonspecific signs: fever, myalgia, coryza, anorexia, vomiting Atypical signs: seizures, syncope, sudden cardiac death

symptoms like fever, irritability, pallor and poor feeding, indicating an infection.⁷ However, neonates may also present with ominous signs such as apnoea and episodic cyanosis.⁷

Signs and symptoms of myocarditis are also variable in older children. They may present with non-specific upper respiratory or gastrointestinal symptoms, fever, myalgia, coryza, anorexia and vomiting.⁷ Chest pain, due to pericardial irritation, is non-specific and is only reported in minority of the cases.^{2,7} Myocarditis may also present with atypical features such as syncope and seizures and accounts for 12% of sudden cardiac deaths in adolescents and young adults.³

Owing to non-specific symptoms in majority of cases, the diagnosis of myocarditis is difficult to make on clinical grounds, leading to missed diagnosis in up to 83% of the cases on the first presentation to a medical provider.¹⁸ Generally, medical practitioners become suspicious of myocarditis when there is tachycardia in an otherwise healthy child without a clearly defined cause i.e. fever or dehydration.

Patients who have developed high degree of cardiac dysfunction and congestive heart failure (CHF), present with signs and symptoms of respiratory distress, diaphoresis, tachycardia, tachypnoea, gallop rhythm, decreased peripheral pulses and hepatomegaly. A gallop rhythm, produced by the third or fourth heart sound is best heard at the apex. The first sign of CHF appreciated in children is eyelid puffiness due to fluid retention.²

Differential Diagnosis

Other diseases that can mimic myocarditis are sepsis, dilated cardiomyopathy secondary to metabolic disorders or idiopathic dilated cardiomyopathy or anomalous left coronary artery off the pulmonary artery (ALCAPA).

Diagnostic Modalities

The chest x-ray typically demonstrates cardiomegaly and increased pulmonary vascular markings, indicating pulmonary oedema.

The 12-lead electrocardiogram (ECG) is used widely in the

diagnosis of myocarditis despite low sensitivity.^{5,19} The most common ECG changes are sinus tachycardia, S-T wave changes, low voltage QRS complexes, axis deviation and ventricular hypertrophy.² Infarction patterns, atrial abnormalities and various degrees of heart block may also be seen.²⁰ The presence of Q waves, a new left bundle branch block and prolonged QRS duration of >120msec is associated with higher rates of cardiac death or heart transplantation and may be used as a prognostic indicator.⁵

Echocardiogram is essential in diagnosis, treatment and follow-up of patients with myocarditis.² It does not show any specific features of myocarditis, but helps in ruling out other cardiac abnormalities such as valvular heart disease or other cardiomyopathies (hypertrophic or restrictive cardiomyopathy).² Durani et al recently reported that echocardiography will show abnormal findings in 98% of paediatric myocarditis, with segmental wall motion abnormalities being the most common (hypokinesia, akinesia and/or dyskinesia).¹⁸

Non-specific markers of inflammation, erythrocyte sedimentation rate (ESR) and C-reactive protein (CRP) have been found to be elevated in 27-56% of cases of paediatric myocarditis.⁷ Troponin I and troponin T are cardio-selective markers released in the blood stream, hours following cardiac insult. Cardiac troponin T (cTnT) has been found to be elevated in children with myocarditis.²¹ Levels > 0.052 mg/ml have a sensitivity of 71% and specificity of 86% for paediatric myocarditis.²¹ Recently, aspartate aminotransferase (AST) was also studied and was found to be a highly sensitive marker for diagnosis of paediatric myocarditis as it was seen to be elevated in 85% cases of definite and probable cases of myocarditis. However, AST levels are non-specific and may be raised in conditions such as Kawasaki syndrome, hypoperfusion and other viral illnesses.²³

Soongswang et al²¹ further assessed the use of serum cTnT and creatinine kinase-muscle and brain levels as non-invasive indicators to differentiate acute myocarditis and chronic DCM in paediatric patients. The two levels were shown to be significantly higher in patients with myocarditis than in patients with DCM.²¹

EMB still remains the gold standard for diagnosis of myocarditis. Specific histopathological features found on microscopic examination of the biopsy specimen in a myocarditis patient are shown in Figure-2A-F. Polymerase chain reaction (PCR) performed on the myocardial tissue has proved to be both sensitive and specific in diagnosing enterovirus and adenoviral myocarditis. However, EMB is an invasive procedure and can lead to dangerous

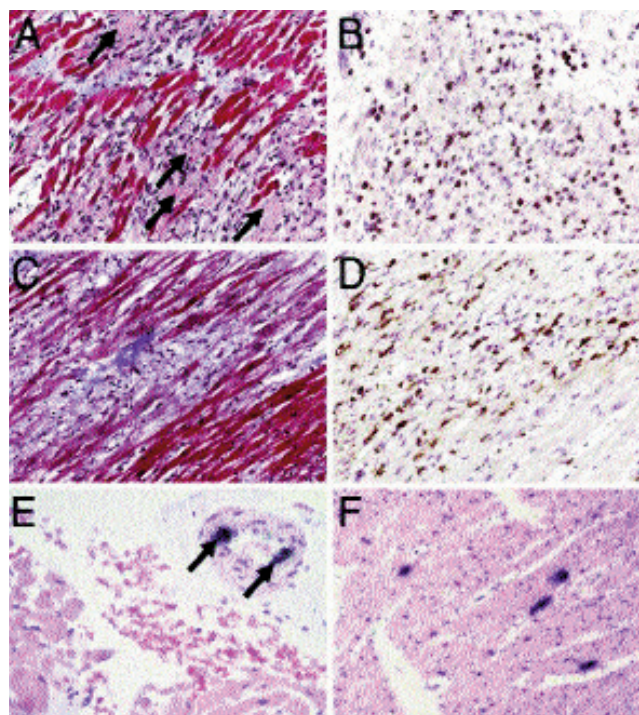


Figure-2: Histopathological findings in myocarditis in children (A, B) acute myocarditis (C, D) chronic myocarditis. In acute myocarditis, numerous necrotic myocytes (A, arrows) are associated with mononuclear cell infiltrates including CD3+ T cells (B), whereas in chronic myocarditis, inflammatory cells such as CD68+ macrophages (D) are mainly present in areas with fibrosis (C, blue staining). (E, F) Radioactive in situ hybridization reveals PVB19 nucleic acid in endothelial cells of an arteriole in a patient with chronic myocarditis (E), whereas enterovirus ribonucleic acid is detected in several myocytes (F). Adapted from Kindermann I et al.⁵

complications in paediatric population, including pneumothorax, haemothorax, dysrhythmia, heart block, myocardial perforation and death.²³ Moreover, EMB, when used alone, is not sensitive owing to patchy nature of myocardial inflammation.³

Cardiac magnetic resonance imaging (CMRI) has recently evolved as a non-invasive and valuable diagnostic modality for myocarditis. CMR, with early and delayed gadolinium enhancement, can often detect the subtle patchy myocardial involvement and can demarcate areas of inflammation.²² Thus, CMR can help not only in diagnosing myocarditis, but can guide EMB procedure. Vashist et al⁷ in his retrospective study concluded that myocarditis in children is characterised by sub-pericardial and transmural enhancement. Transmural myocardial involvement, global hypokinesia, LV dilation, and LV ejection fraction less than 30% were shown to be associated with poor prognosis.

Treatment

The mainstay of treatment in paediatric myocarditis

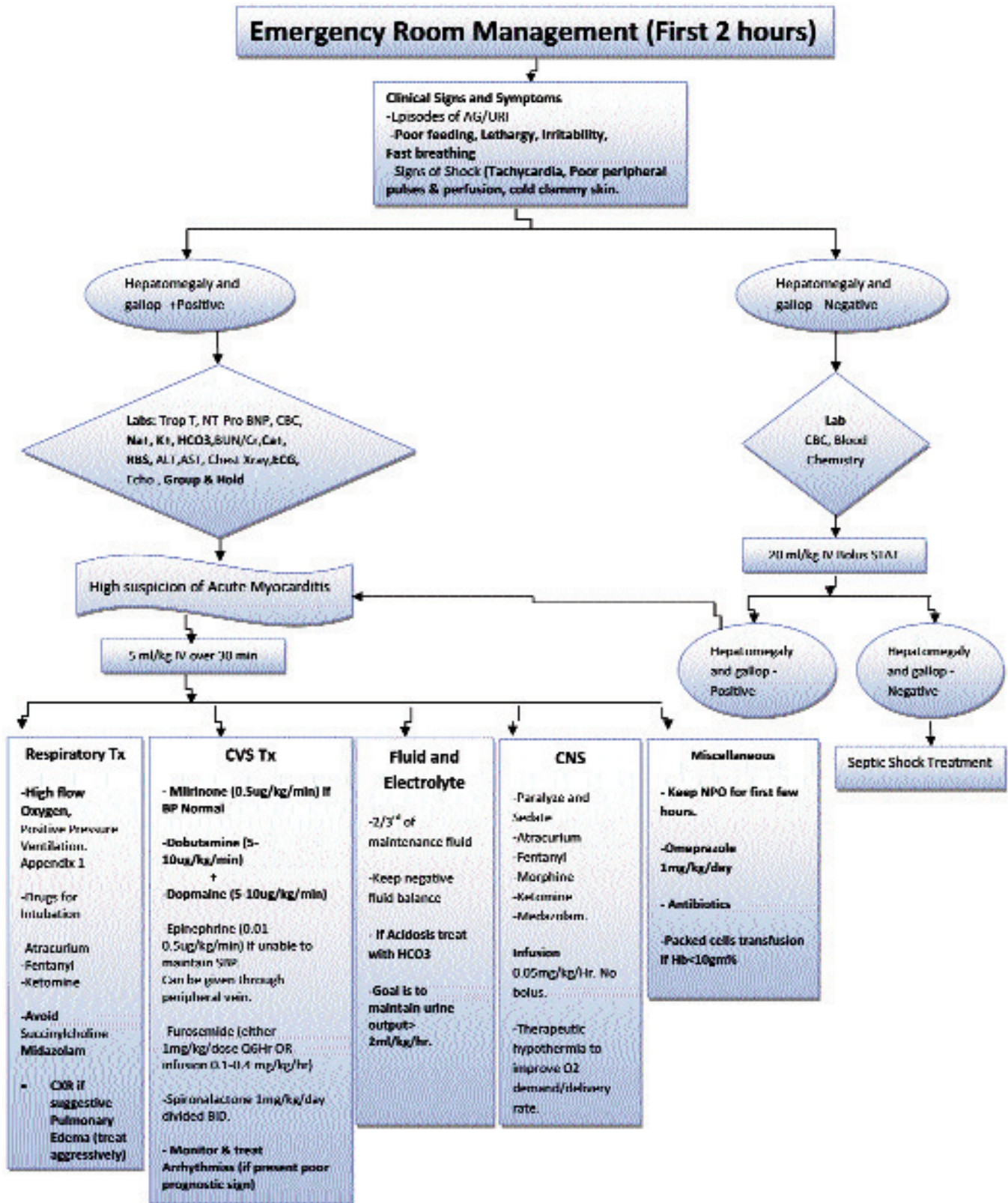


Figure-3: Management of myocarditis in emergency department; endomyocardial biopsy and cardiac magnetic resonance imaging not mentioned as not readily available in resource-limited developing world.

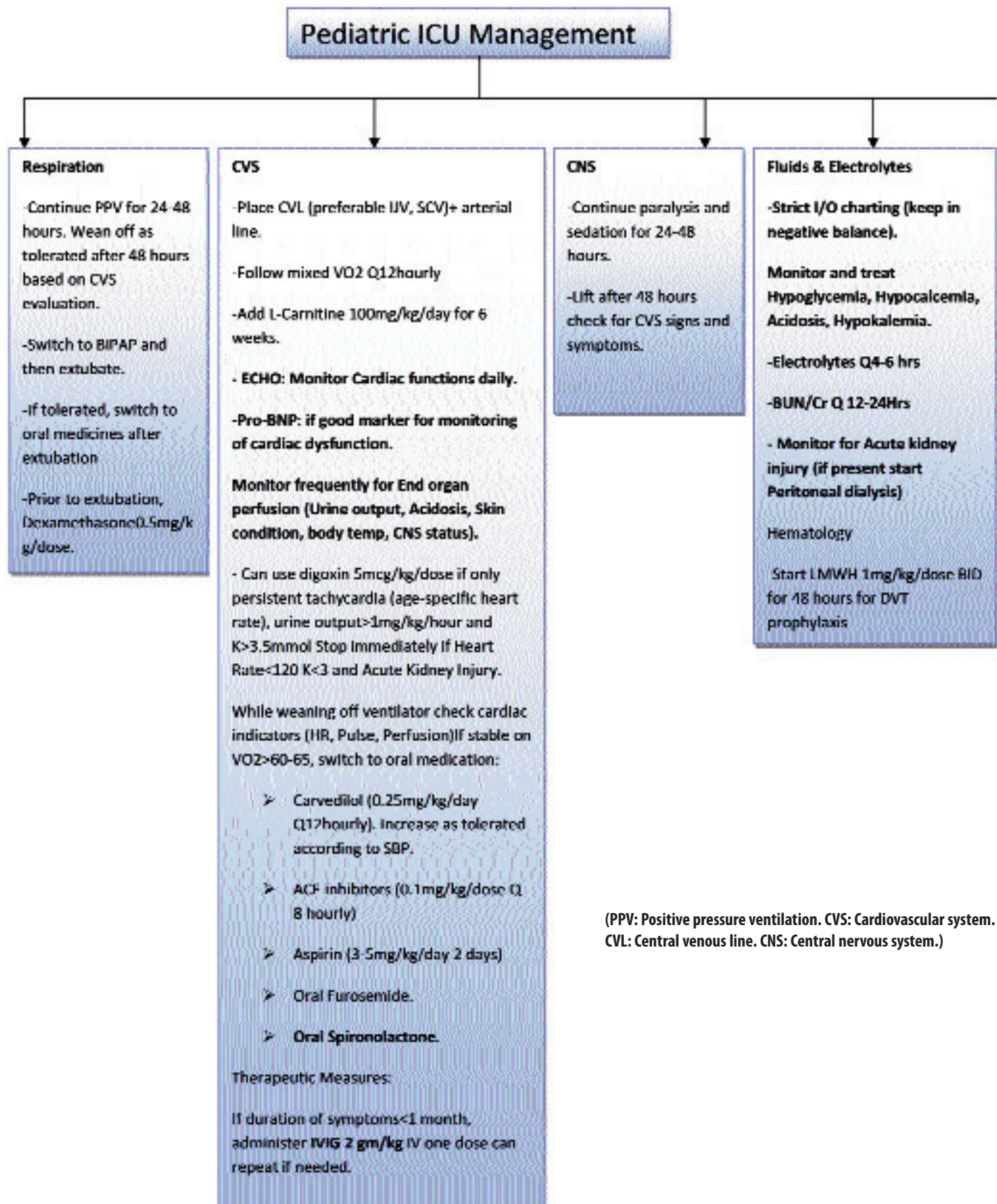
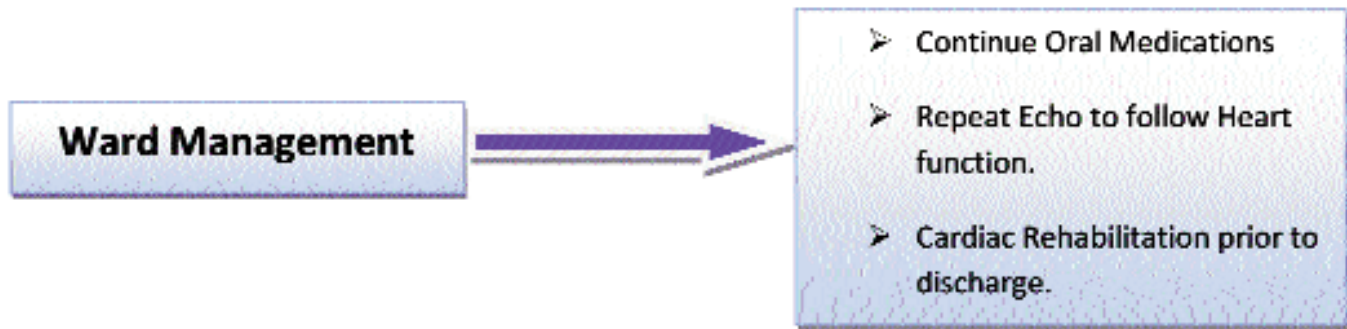


Figure-4: Paediatric intensive care unit and ward management of myocarditis.



remains supportive symptom-based care (Figure-3). Most of the children will recover fully without any long-term sequelae.⁴ General principles of supportive treatment in acute phase include reduction of high ventricular preload, reduction of ventricular afterload, improving myocardial contractility and optimisation of tissue oxygen delivery (Figure-4).²

Symptom-based Care Therapy

Children presenting with signs and symptoms of CHF should be aggressively managed with administration of inotropic support, afterload reduction and diuresis. In acute or decompensated heart failure, diuretics are frequently administered as removal of excess fluid from the body helps to improve cardiac function.⁹ However, diuretics should be administered with care as too rapid a removal of fluid may lead to hypovolaemia and hypotension.⁹ Fluid resuscitation should also be done with caution, especially in undiagnosed myocarditis patients presenting as septic shock where aggressive fluid resuscitation may be detrimental.

For more severe disease, an inotropic agent, such as dobutamine or dopamine, can be added, especially if cardiac output is inadequate and cardiac function is depressed on ECG. They should be administered with caution due to risk of arrhythmias. Dobutamine improves contractility and decreases afterload, while dopamine has both inotropic and vasopressor properties and is useful in patients with cardiogenic shock with hypotension.¹⁷ Severe shock may require the addition of epinephrine as well. Moreover, milrinone, a phosphodiesterase inhibitor, can also be administered as it helps improve the diastolic function of the heart and, hence, improve ventricular relaxation and filling times. Milrinone is considered inotropic agent of choice at many centres owing to its positive effect on the cardiac index, reduction in systemic vascular resistance and comparatively less side effects in terms of arrhythmogenic properties.¹⁷

Use of beta blockers in the treatment of myocarditis in children remains controversial. Although beta blockers,

especially carvedilol, are well known to improve survival in adult patients with CHF, a 2009 Cochrane review on efficacy of beta blockers in children with CHF failed to demonstrate statistically significant benefit of beta blockers.^{24,25} Moreover, a recent randomised control trial carried out by Shaddy et al²⁵ failed to show any significant benefit of carvedilol in children with heart failure. However, the study suggested, this can be secondary to parents and physician's false perception of normal developmental milestones (starting to walk) as indicators of cardiovascular status.²⁵

L-carnitine is employed in treatment of myocarditis as it is known to prevent apoptosis of muscle cells and plays a role in CHF associated myopathies.

Rhythm disturbances in children with myocarditis are life-threatening and should be aggressively treated. Ventricular ectopy, ventricular tachycardia and heart block may develop in children with myocarditis. Digoxin should be used with extreme care during the acute phase of the disease as high doses lead to increased production of pro-inflammatory cytokines and can precipitate serious dysrhythmias. However, its use is still questionable in cases of DCM and chronic heart failure.^{2,17}

Positive pressure ventilation (PPV) can be employed in cases of ventricular dysfunction as it can eliminate work of breathing, and can lead to decrease in LV wall tension and, thus, afterload reduction. In case of failure of medical treatment, mechanical assistance devices with ECMO, and transthoracic placement of a left or biventricular assist device (LVAD/BVAD) may also be used given the overall prognosis for recovery. However, cardiac transplantation is the last resort in cases of end-stage DCM.

Mechanism Specific Interventions

Many studies have been done to evaluate the efficacy of adjuvant therapeutic interventions, specifically intravenous immunoglobulins (IVIG) to reduce long-term cardiac complications. While some of the studies both in developing²⁶ and the developed world have

demonstrated statistically significant increase in survival among those children treated with IVIG,²⁷ a recently conducted multi-institutional analysis on outcome of paediatric myocarditis failed to show any survival benefits of using IVIG.²⁸

Apart from immunoglobulin, immunosuppressive therapies are also possible adjuvant to therapeutic modalities in the treatment of myocarditis. Before initiating immunoglobulin therapy, EMB with PCR should be done to rule out any viral load as immunomodulator use in myocarditis with concomitant viral load may lead to detrimental effect.²⁹ The sole randomised control trial performed by Camargo et al³⁰ randomised paediatric patients with biopsy-proven viral myocarditis into three groups: prednisone only; or prednisone and azathioprine; or prednisone, azathioprine and cyclosporine. The study concluded that combination immunosuppressive therapy leads to improvement in cardiac outcome.³⁰ Aziz et al²⁹ researched the role of prednisone at 3 months of onset of viral myocarditis and concluded that it is beneficial and causes significant improvement in persistent LVF.²⁹ Another meta-analysis done by Hia et al³¹ to assess the benefits of immunosuppressive therapy in the management of viral myocarditis showed that the odds of improved outcome were more among patients treated with immunosuppressive therapy. However, the results were not statistically significant.³¹ The current prevailing consensus regarding immunosuppressive therapy is that it does impart a survival advantage, although there is need of further evaluation.³¹

Prognosis and Outcome

Even though true incidence of myocarditis in children cannot be known owing to sub-clinical presentations, some studies estimate it to be around 1 per 100,000.³² The incidence of myocarditis in developing countries is seen more in the winter months owing to increase in upper respiratory tract infections (URIs).³³ The survival rate is more than 80% in the first year, but 25%-50% of the cases may develop DCM and chronic heart failure.^{2,34} Out of children who develop DCM, the 1-year and 5-year rates of death and heart transplantation are 31% and 46% respectively. It has also been seen that the patients who survive the first 72 hours without requiring ECMO have a survival rate of 97%. Viral persistence in the myocardium, ejection fraction less than 30% and moderate to severe mitral regurgitation have been associated with adverse outcome.³⁵ Hence, early administration of IVIGs may help in the reduction of long-term complications by decreasing the viral load. However, further studies are required to evaluate its role.

Conclusion

Myocarditis is a challenging diagnosis to make on clinical grounds owing to the wide array of clinical presentation, and requires high index of suspicion. Generally, medical practitioners become suspicious of myocarditis when there is tachycardia in an otherwise healthy child without a clearly defined cause. The main cornerstone of treatment remains supportive although therapeutic modalities such as immunosuppressive therapy and IVIGs are being extensively studied. With the advent of newer diagnostic and therapeutic modalities and improved therapy for heart failure, including mechanical cardiovascular support, the overall prognosis of the disease is getting better with 80% survival rates.

References

1. Batra AS, Lewis AB. Acute myocarditis. *Curr Opin in Pediatr* 2001; 13: 234-9.
2. Dancea AB. Myocarditis in infants and children: a review for the paediatrician. *Paediatr Child Health* 2001; 6: 543-5.
3. Sparrow PJ, Merchant N, Provost YL, Doyle DJ, Nguyen ET, Paul NS. CT and MR imaging findings in patients with acquired heart disease at risk for sudden cardiac death. *Radiographics* 2009; 29: 805-23.
4. Amabile N, Fraisse A, Bouvenot J, Chetaille P, Ovaert C. Outcome of acute fulminant myocarditis in children. *Heart* 2006; 92: 1269-73.
5. Kindermann I, Barth C, Mahfoud F, Ukena C, Lenski M, Yilmaz A, et al. Update on myocarditis. *J Am Coll Cardiol* 2012; 59: 779-92.
6. Maron BJ, Towbin JA, Thiene G, Antzelevitch C, Corrado D, Arnett D, et al. Contemporary definitions and classification of the cardiomyopathies. *Circulation*. 2006; 113: 1807-16.
7. Vashist S, Singh GK. Acute myocarditis in children: current concepts and management. *Curr Treat Options Cardiovasc Med* 2009; 11: 383-91.
8. Feldman AM, McNamara D. Myocarditis. *N Engl J Med* 2000; 343: 1388-98.
9. Tobias JD, Deshpande JK, Johns JA, Nichols DG. Inflammatory heart disease. In: Nichols DG, Cameron DE, eds. *Critical Heart Disease in Infants and Children*. Philadelphia, PA: Mosby, 2006; pp 899-925.
10. Kindermann I, Kindermann M, Kandolf R, Klingel K, Bültmann B, Müller T, et al. Predictors of outcome in patients with suspected myocarditis. *Circulation* 2008; 118: 639-48.
11. Cooper Jr LT. Myocarditis. *N Engl J Med* 2009; 360: 1526-38.
12. Kearney MT, Cotton JM, Richardson PJ, Shah AM. Viral myocarditis and dilated cardiomyopathy: mechanisms, manifestations, and management. *Postgrad Med J* 2001; 77: 410.
13. Matsumori A. Molecular and immune mechanisms in the pathogenesis of cardiomyopathy: role of viruses, cytokines and nitric oxide. *Jpn Circ J* 1997; 61: 275-91.
14. Leonard EG. Viral myocarditis. *Pediatr Infect Dis J* 2004; 23: 665-6.
15. McCarthy RE, Boehmer JP, Hruban RH, Hutchins GM, Kasper EK, Hare JM, et al. Long-term outcome of fulminant myocarditis as compared with acute (nonfulminant) myocarditis. *N Engl J Med* 2000; 342: 690-5.
16. D'Ambrosio A, Patti G, Manzoli A, Sinagra G, di Lenarda A, Silvestri F, et al. The fate of acute myocarditis between spontaneous improvement and evolution to dilated cardiomyopathy: a review. *Heart* 2001; 85: 499-505.
17. Gupta D, Garg G, Tomar CRPS. Myocarditis in Children. *The*

- Intensivist: Newsletter of Intensive Care Chapter, Indian Academy of Pediatrics. January 2009.
18. Durani Y, Egan M, Baffa J, Selbst SM, Nager AL. Paediatric myocarditis: presenting clinical characteristics. *Am J Emerg Med* 2009; 27: 942-7.
 19. Morgera T, Di Lenarda A, Dreas L, Pinamonti B, Humar F, Bussani R, et al. Electrocardiography of myocarditis revisited: clinical and prognostic significance of electrocardiographic changes. *Am Heart J* 1992; 124: 455-67.
 20. Freedman SB, Haladyn JK, Floh A, Kirsh JA, Taylor G, Thull-Freedman J. Paediatric myocarditis: emergency department clinical findings and diagnostic evaluation *Pediatrics* 2007; 120: 1278-85.
 21. Soongswang J, Durongpisitkul K, Ratanarapee S, Leowattana W, Nana A, Laohaprasitiporn D, et al. Cardiac troponin T: its role in the diagnosis of clinically suspected acute myocarditis and chronic dilated cardiomyopathy in children. *Pediatr Cardiol* 2002; 23: 531-5.
 22. Cowley CG, Lozier JS, Orsmond GS, Shaddy RE. Safety of endomyocardial biopsy in children. *Cardiol Young* 2003; 13: 404-7.
 23. Goitein O, Matetzky S, Beinart R, Di Segni E, Hod H, Bentancur A, et al. Acute myocarditis: noninvasive evaluation with cardiac MRI and transthoracic echocardiography. *AJR Am Roentgenol* 2009; 192: 254-8.
 24. Frobel AK, Hulpke-Wette M, Schmidt KG, L  er S. Beta-blockers for congestive heart failure in children. *Cochrane Database Syst Rev* 2009; CD007037.
 25. Shaddy RE, Boucek MM, Hsu DT, Boucek RJ, Canter CE, Mahony L, et al. Carvedilol for children and adolescents with heart failure: a randomized controlled trial. *JAMA* 2007; 298: 1171-9.
 26. Haque A, Bhatti S, Siddiqui FJ. Intravenous immune globulin for severe acute myocarditis in children. *Indian Pediatr* 2009; 46: 810-1.
 27. Camargo PR, Okay TS, Yamamoto L, Del Negro GM, Lopes AA. Myocarditis in children and detection of viruses in myocardial tissue: implications for immunosuppressive therapy. *Int J Cardiol* 2011; 148: 204-8.
 28. Klugman D, Berger JT, Sable CA, He J, Khandelwal SG, Slonim AD. Pediatric patients hospitalized with myocarditis: a multi-institutional analysis. *Pediatr Cardiol* 2010; 31: 222-8.
 29. Aziz KU, Patel N, Sadullah T, Tasneem H, Thawerani H, Talpur S. Acute viral myocarditis: role of immunosuppression: a prospective randomised study. *Cardiol Young* 2010; 20: 509-15.
 30. Camargo PR, Snitcowsky R, da Luz PL, Mazzieri R, Higuchi ML, Rati M, et al. Favorable effects of immunosuppressive therapy in children with dilated cardiomyopathy and active myocarditis. *Pediatr Cardiol* 1995; 16: 61-8.
 31. Hia CPP, Yip WC, Tai BC, Quek SC. Immunosuppressive therapy in acute myocarditis: an 18 year systematic review. *Arch Dis Child* 2004; 89: 580-4.
 32. Stiller B. Management of myocarditis in children: the current situation. *Adv Exp Med Biol* 2008; 609: 196-215.
 33. Aziz KU. Acute myocarditis in children, incidence, treatment and prognosis: a developing world problem. *Pak Paed Cardiol J* 2001; 3: 24-9.
 34. Bruns LA, Chrisant MK, Lamour JM, Shaddy RE, Pahl E, Blume ED, et al. Carvedilol as therapy in pediatric heart failure: an initial multicenter experience. *J Pediatr* 2001; 138: 505-11.
 35. K  hn B, Shapiro ED, Walls TA, Friedman AH. Predictors of outcome of myocarditis. *Pediatr Cardiol* 2004; 25: 379-84.
-