

## A case of orbital apex syndrome in a patient with malignant otitis externa

Rashid Baig, Qazi Assad Khan, Mohammad Ali Sadiq, Sohail Awan, Khabir Ahmad

### Abstract

A rare case of skull base infection with a rapid clinical course leading to visual loss and eventually death in a poorly-controlled diabetic patient is presented. A 37-year-old woman presented with a history of visual loss and painful protrusion of the right eye for the preceding 3 days. This was accompanied by vertigo and right-side facial weakness. The patient had perception of light in her right eye and 20/25 (presenting visual acuity) in the fellow eye, accompanied by right-side proptosis, total ophthalmoplegia, optic disc pallor and central retinal artery occlusion. Magnetic resonance imaging showed the presence of oedema with soft-tissue thickening in the right external auditory canal along with evidence of fluid within the middle ear cavity and mastoid air cells on the right side. A diagnosis of Orbital Apex Syndrome was made and treatment initiated.

**Keywords:** Orbital apex syndrome, Malignant otitis externa, Ophthalmoplegia.

### Introduction

Orbital Apex Syndrome (OAS) is a rare condition characterised by damage to vessels and nerves passing through the superior orbital fissure and optic foramen.<sup>1</sup> These include optic nerve, oculomotor nerve, trochlear nerve, abducens nerve, and the ophthalmic branch of the trigeminal nerve. Its ocular manifestations include painful proptosis, ophthalmoplegia and loss of vision. The severity of the condition varies considerably from person to person and for a given person over time due to the differences in the degree of nerve or vascular damage. A number of etiological factors have been found to be associated with the development of OAS, including infections (fungal, viral and bacterial),<sup>2-4</sup> trauma,<sup>5</sup> neoplasms<sup>6</sup> diabetes, neurological, vascular and autoimmune disorders. We describe below a case of OAS secondary to malignant otitis externa, which, to the best of our knowledge, has not been reported previously in medical literature.

Sections of Ophthalmology and Otolaryngology, Department of Surgery, Aga Khan University, Karachi.

**Correspondence:** Rashid Baig. Email: rashid.baig@aku.edu

### Case Report

A 37-year-old woman was referred to us by the Otolaryngology Department for an eye examination. She had a recent onset of visual loss, painful ophthalmoplegia and proptosis involving the right eye for the preceding two days. She also reported having vertigo, and right-sided earache and facial weakness for the preceding 3 days. The patient had long-standing

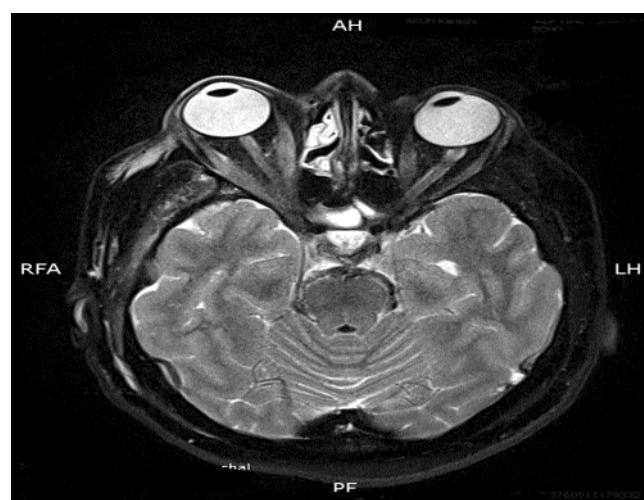


Figure-1: Scan (T1W) showing proptosis of the right eye.

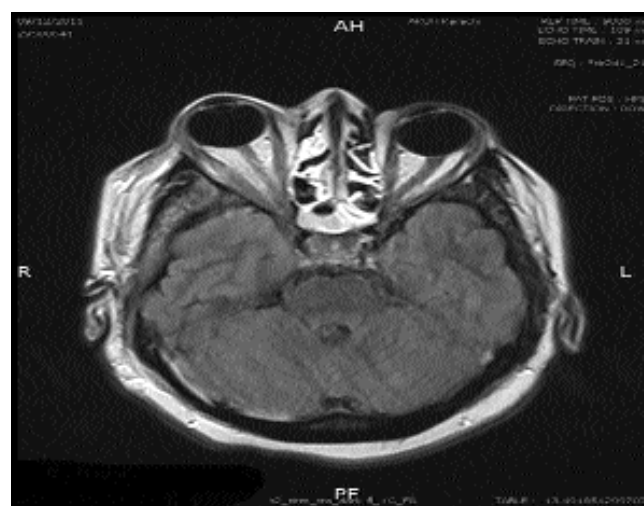
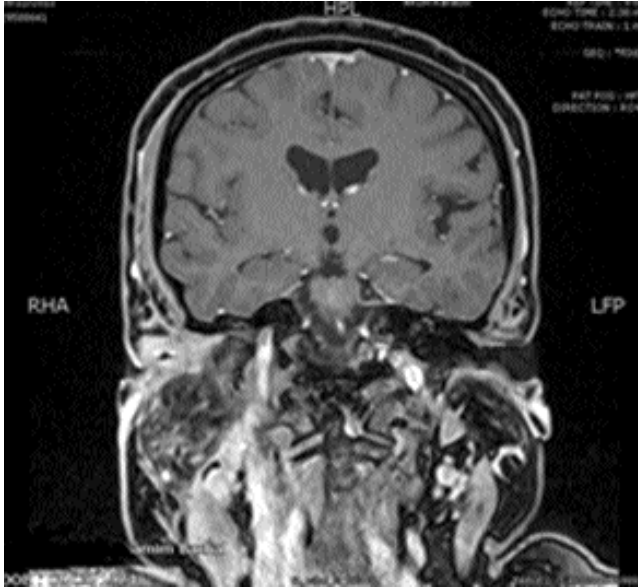
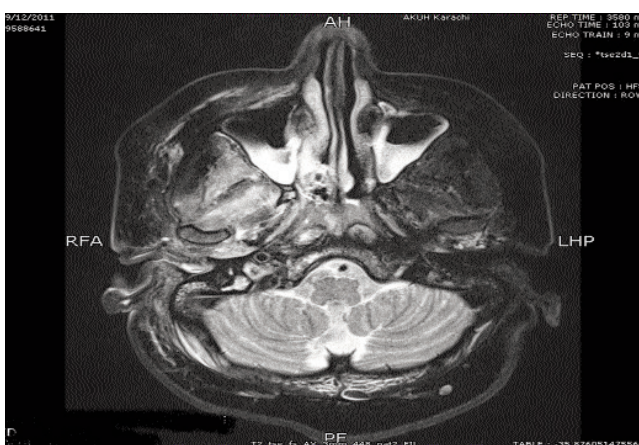


Figure-2: Scan (T2W) showing proptosis of the right eye.



**Figure-3:** Coronal section of T1 weighted MRI-scan showing inflamed right external auditory canal.

poorly-controlled diabetes and hypertension. Her presenting visual acuity was perception of light in the right eye and 20/25 in the left. On examination, she had right-sided axial proptosis (Figure-1 and 2), complete ophthalmoplegia with dilated and fixed pupil. Dilated funduscopy of the right eye revealed mild optic disc pallor, surrounding pale retina with a cherry-red spot at the fovea with cattle track sign. A provisional diagnosis of right-side OAS with central retinal artery occlusion was made. A temporal bone computed tomography scan without contrast was done which showed soft-tissue thickening and fluid in the middle ear cavity



**Figure-4:** Axial section of T2 weighted MRI-scan showing oedematous non-patent right external auditory canal.

along the external auditory canal on the right side (Figure-3 and 4). Magnetic resonance imaging (MRI) showed the presence of significant inflammatory changes along the right side of the head and neck. In addition, there was soft-tissue thickening and oedema of the right external auditory canal, fluid in the middle ear and mastoid air cells suggestive of malignant otitis externa. There were inflammatory changes extending into the right orbit evident by proptosis, intra-orbital fat stranding and oedema of the orbital muscles. There was substantial proptosis of right eyeball in comparison to the left side. After consultation with the infectious disease physician, a short course of intravenous (IV) methyl-prednisolone was given and the patient was kept under close observation. The patient was already on broad-spectrum IV antibiotics and anti-fungals. Aural swabs and blood cultures were negative for any fungal infections. Despite aggressive medical treatment, the patient died of overwhelming infection and multiple organ failure.

## Discussion

This is the first reported case, to the authors' knowledge, of OAS secondary to malignant otitis externa. The closest match was a case in which otitis media resulted in OAS.<sup>4</sup> In our patient the soft-tissue inflammatory reaction started from external ear spreading all the way to the orbital cavity, hence making it a very rare finding.

As mentioned, OAS is a rare condition that presents with a complex set of symptoms, including ophthalmoplegia, proptosis and visual loss. Due to the high morbidity and mortality associated with this condition, timely and aggressive treatment of the primary etiology is necessary. A multi-disciplinary approach involving an ophthalmologist, otolaryngologist, neurologist, and infectious disease physician (where the etiology is infection) should be taken. The development and rapid progression of the disease in our patient could be attributed to the fact that she had longstanding diabetes and her current blood glucose levels were uncontrolled, which increased her risk of getting malignant otitis externa. Diabetes induces microvasculopathy and immune dysfunction, which predisposes to infections, including malignant otitis externa. Studies suggest that diabetes is the most important associated co-morbidity, with most of the cases (65% to 100%) having diabetes.<sup>7</sup> The delayed presentation at the hospital might have also contributed to such an aggressive manifestation.

Painful ophthalmoplegia is an important presenting

complaint to ophthalmologists, neurologists and emergency departments. A systematic approach to the evaluation of eye symptoms is necessary to identify the etiology and to initiate treatment. An extensive list of etiologies causing OAS has been reported<sup>1</sup>. Some of the common ones include infections (e.g., fungal, viral, bacterial), trauma, neoplasms (e.g., primary tumours, local or distant metastases), vascular disorders (e.g., aneurysm, carotid dissection, carotid-cavernous fistula), and other conditions, like microvascular infarcts secondary to diabetes. Complete or near-complete visual loss can occur in patients suffering from OAS as a result of optic nerve atrophy. This was also the case in our patient. The role of steroids in OAS-associated optic atrophy has been advocated,<sup>8</sup> and some patients do regain some form of vision as a result of treatment if they survive.

### Conclusion

This is probably the first reported case of OAS secondary to malignant otitis externa. Skull base infection with a rapid clinical course led to visual loss and eventually

death in this poorly-controlled diabetic patient despite rigorous treatment.

### References

1. Yeh S, Foroozan R. Orbital apex syndrome. *Current Opin Ophthalmol* 2004; 15: 490-8.
2. Saxena R, Phuljhele S, Aalok L, Sinha A, Menon V, Sharma P. A rare case of orbital apex syndrome with herpes zoster ophthalmicus in a human immunodeficiency virus-positive patient. *Indian J Ophthalmol* 2010; 58: 527-30.
3. Kurimoto T, Tonari M, Ishizaki N, Monta M, Hirata S, Oku H, et al. Orbital apex syndrome associated with herpes zoster ophthalmicus. *Clinical Ophthalmol* 2011; 5: 1603-8.
4. Sethi A, Sareen D, Mrig S, Agarwal AK, Khera PS. Acute suppurative otitis media: an unusual cause of orbital apex syndrome. *Orbit* 2008; 27: 462-5.
5. Li Y, Wu W, Xiao Z, Peng A. Study on the treatment of traumatic orbital apex syndrome by nasal endoscopic surgery. *Eur Arch Otorhino-laryngol* 2011; 268: 341-9.
6. McDonald HR, Char DH. Adenoid cystic carcinoma presenting as an orbital apex syndrome. *Ann Ophthalmol* 1985; 17: 757-9.
7. Carfrae MJ, Kesser BW. Malignant otitis externa. *Otolaryngol Clin North Am* 2008; 41: 537-49.
8. Acarturk S, Sekucoglu T, Kesiktas E. Mega dose corticosteroid treatment for traumatic superior orbital fissure and orbital apex syndromes. *Ann Plastic Surg* 2004; 53: 60-4.