

Pleural angiosarcoma: a rare cause of spontaneous haemothorax

Seda Tural Onur,¹ Zeki Günlüoğlu,² Levent Dalar,³ Sinem Sökücü,⁴ Sedat Altın,⁵ Ibrahim Dinçer⁶

Abstract

Angiosarcoma is a rare soft tissue tumour and constitutes less than 1% of all soft tissue cancers. Pleural angiosarcomas are extremely rare and have an aggressive course. We report the case of a 79-year-old female patient who presented with complaints of increasing dyspnoea on exertion and homogeneous opacification of the left hemithorax on chest radiograph. Epithelioid angiosarcoma was determined on pleural tissue obtained by video-assisted thoracoscopic surgery (VATS).

Keywords: Angiosarcoma, Hemothorax, Pleura, Soft tissue tumour.

Introduction

Malignant tumours of the pleural membranes are commonly metastatic tumours, especially from peripheral lung adenocarcinomas.¹ Spontaneous haemothorax is a rare disease manifestation and is defined as pleural effusion with a haematocrit of 50% of that of peripheral blood.² The most common reasons are coagulation and vascular disorders. More rarely, carcinomas are the cause of spontaneous haemothorax. Angiosarcoma is a rare soft tissue tumour and comprises < 1% of all soft tissue cancers.^{1,3} It is derived from endothelial cells and high-grade malignant tumours, and can affect any organ.^{1,3} Pleural angiosarcomas are very rare and aggressive tumours.^{1,3} We report a rare case of primary pleural angiosarcoma.

Case Report

A 79-year-old woman with previous hypertension was admitted to our emergency department with complaints of increasing dyspnoea on exertion of one month duration. Chest radiography revealed homogeneous opacification of the left hemithorax, with absent lung markings (Figure-1a), and diagnostic thoracentesis was performed. Serohaemorrhagic exudative pleural effusion of 1 L was produced. Effusion fluid pH was 7.35 and haematocrit was 8%. No feature of the patient's own or

family history (Yugoslav immigrants) was relevant. She was a non-smoker and did not consume alcohol, and she had no defined exposure to asbestos or other environmental exposure. She was taking verapamil HCl + trandolapril, 240/4 mg and metoprolol succinate, 50 mg. She was not taking acetylsalicylic acid, anticoagulants, or antiplatelet agents.

Symptoms given were chest and back pain, shortness of breath at rest, fatigue, cough, and sputum expectoration. Physical examination with pulse oximetry showed oxygen saturation of 92%, arterial blood pressure of 100/60 mmHg, heart rate of 64 beats/min, and respiratory rate of 20 breaths/min. The patient was found to be cooperative, oriented, and conscious. She had no oedema, jaundice, or cyanosis. Respiratory system examination revealed that the left thoracic vibration was reduced. Other systemic examinations showed nothing abnormal.

Clinical Course: Symptomatic treatment was started and the patient was hospitalized. A litre of pleural fluid was sent for diagnostic cytology. On day 4 of monitoring, the patient had increased shortness of breath, and thoracentesis was performed and pleural fluid haematocrit was determined at 27% (24% of simultaneous blood haematocrit). Haemothorax was evaluated and tube thoracostomy was implemented. After the drainage fell below 100 mL on the second day, chest computed tomography (CT) and bronchoscopy were performed. CT revealed cystic and cavitory lesions and diffuse destruction, accompanied by left pleural thickening. The bronchoscopy did not show any clinical features. The patient received packed red blood cells and the thoracostomy tube was removed. However, shortness of breath was evident and fluid accumulation was observed on chest radiography.

Positron emission tomography (PET)/CT was performed after the histopathological diagnosis. The left hemithorax and all costal, mediastinal and diaphragmatic pleural surfaces in areas that were characterised by massive pleural thickening and nodularity showed intense fluorodeoxyglucose uptake. Additionally, widespread mediastinal and supraclavicular lymphangiomyomatosis was seen on PET/CT (Figure-1b). The patient was unable to tolerate oncological treatment,

.....
^{1,3-5}Department of Chest Diseases, ^{2,6}Department of Chest Surgery, Yedikule Chest Diseases and Chest Surgery Education and Research Hospital, Istanbul, Turkey.

Correspondence: Levent Dalar. Email: leventdalar@gmail.com

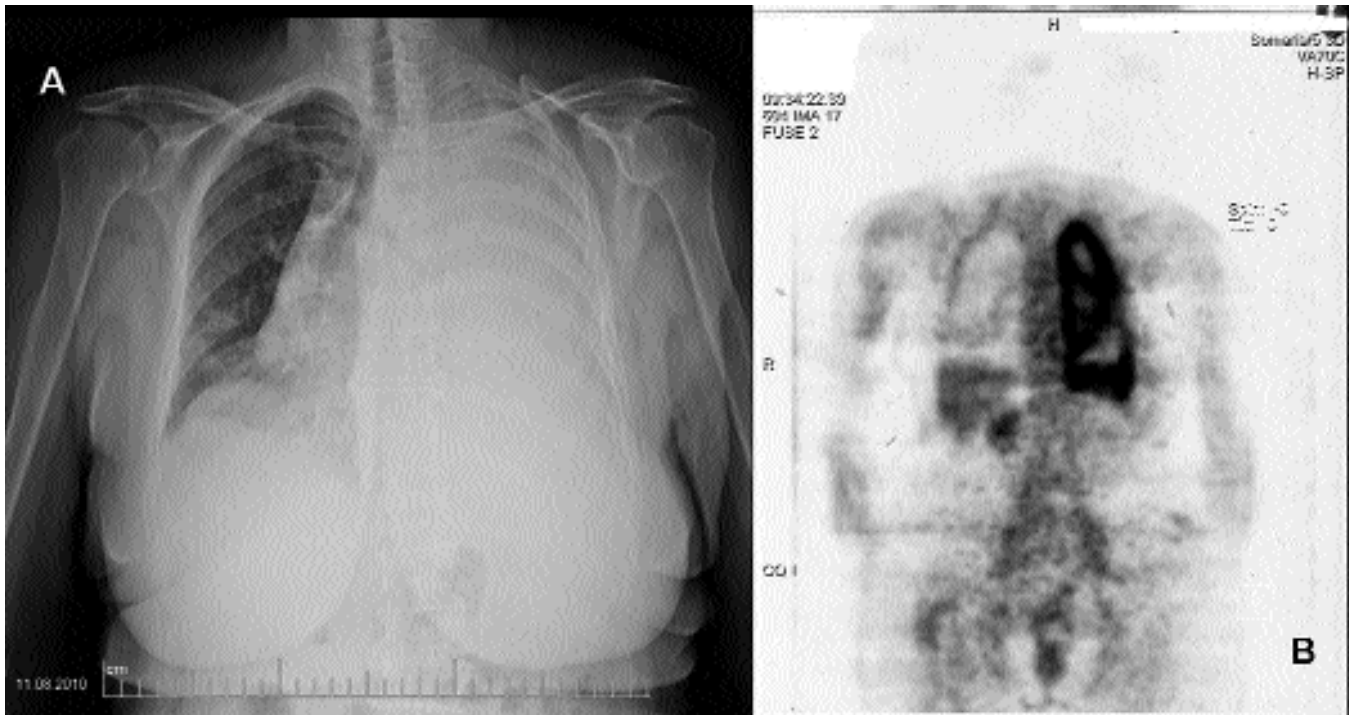


Figure-1: (a) Chest radiography. (b) PET/CT.

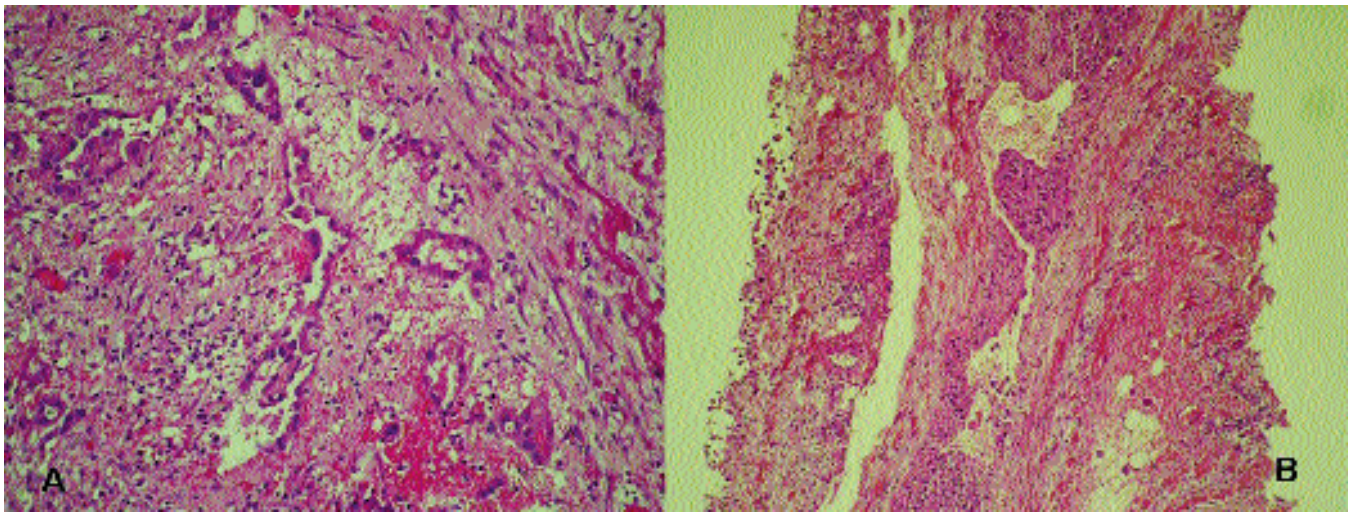


Figure-2: (a) Histopathologic Findings. Fibrotic tissue lining the surface of the slots and are tumoural proliferation. (b) Histopathologic Findings. Some of the slots are of different diameter and shape of necrosis, fibrin, erythrocytes contain histiocytes are installed around the hemosiderin. Tumour cells are large, polygonal eosinophilic cytoplasm, oval or round nuclei, with or multinuclei noteworthy. Lamination observed in the cytoplasm of tumour cells in places. The findings are compatible with epithelioid angiosarcoma. Immunohistochemical studies CD34 (+) and CD31 (+), pancytokeratin focal (+), CEA, calretinin, mesotelin, cytokeratin 5/6, vimentin (-) showed that epithelioid angiosarcoma. The results support the epithelioid angiosarcoma. 807 x 603mm.

and was followed up after 6 months.

Histopathological findings: Sparse atypical cells were determined on two thoracentesis procedures; they were calretinin (-), TTF-1 (-), CEA (-), and Ber Ep 4(-). There were

insufficient cells for additional immunohistochemical studies. Epithelioid angiosarcoma was diagnosed from pleural tissue obtained by VATS (Figure-2). Tumour cells had large, polygonal, eosinophilic cytoplasm, oval or

round nuclei, or were multinucleated. The findings were consistent with epithelioid angiosarcoma. Immunohistochemical studies, showing CD34 (+) and CD31 (+), pancytokeratin focal (+), CEA, calretinin, mesothelin, cytokeratin 5/6, vimentin (-), were consistent with epithelioid angiosarcoma.

Discussion

Malignant tumours of the pleural membranes are commonly metastases from adenocarcinomas.¹ Although they are usually localised, they sometimes spread diffusely over the pleura and mimic mesotheliomas.¹ Pleural angiosarcoma, small cell lung cancer and thymoma are tumours that mimic mesothelioma.¹ Indeed, in our case, CT images initially suggested mesothelioma. Angiosarcomas are highly malignant neoplasms of vascular origin and account for about 1% of all soft tissue sarcomas. They usually occur in the skin, deep soft tissue, head and neck, spleen and liver, and are extremely rare and aggressive in the pleura and other serous membranes.^{1,4-7}

Pleural angiosarcoma has only been seen rarely, and the average age of patients is 58 (range, 22-80) years, with a male to female ratio of 6:1.³ Aetiology is unclear but trauma, chronic lymphoedema, radiation, foreign bodies, viral infection, chronic pyothorax, or thorium can be responsible for this malignancy.^{1,2,8,9} In our case, no prominent aetiological agent could be found.

Pleural angiosarcomas are difficult to diagnose.¹ They are often of epithelioid type (74%) and can easily be mistaken clinically and histologically for mesothelioma.^{1,2,6} Calretinin (-), focal cytokeratin (+) and vimentin (+) reactivity is useful for differentiation from mesothelioma. Otherwise, one of the endothelial markers, CD31, CD32 or factor VIII, indicates a pleural, epithelioid vascular tumour.^{1-4,7} Such histopathology was seen in our case. For a diagnosis of pleural angiosarcoma, one must demonstrate another focus using screening methods.¹ In our case, we used PET/CT to determine the presence of another focus.

Pleural angiosarcomas are usually advanced; thus, many patients die soon after diagnosis.^{1-3,7} There is no standard treatment modality because of the rapid progression and rarity.¹ From a small number of cases and post-mortem diagnoses, there is little information about treatment modalities.¹⁻³ Clinical data from reported cases have shown that patients die within 6 months after diagnosis, despite the variety of therapeutic modalities available.³

We administered palliative treatment to our patient after carrying out a literature review on the subject.

Clinical features are usually vague and include chest discomfort, cough, and exertional dyspnoea, as in our case.^{1,4} Spontaneous haemothorax is an extremely rare manifestation,^{2,4} and is defined as pleural effusion with a haematocrit of 50% of that of peripheral blood.¹⁰ Regarding spontaneous haemothorax, there was no anticoagulant medication in the patient's history or any family history of coagulation disorders.^{2,4} Physical examination in angiosarcoma may reveal neurofibromatosis lesions and vascular lesions suggesting Osler-Weber-Rendu syndrome.² In the differential diagnosis of pleural angiosarcoma in our case, spontaneous haemothorax was not helpful. There was no significant contribution of imaging techniques to the differential diagnosis. The presence of angiosarcoma can be distinguished with PET/CT from another focus.² CT angiography, video-assisted thoracoscopy, angiography, or exploratory thoracotomy can be used to diagnose haemothorax. In our case, histopathological diagnosis was achieved by video-assisted thoracoscopy and biopsy. As a result, in the differential diagnosis of spontaneous haemothorax, pleural angiosarcoma does not come readily to mind because it is such a rare tumour. Indeed, in the literature, primary pleural angiosarcoma is extremely rare and certain treatment is not clear.

References

1. Pramesh CS, Madur BP, Raina S, Desai SB, Mistry RC. Angiosarcoma of the pleura. *Ann Thorac Cardiovasc Surg* 2004; 10: 187-90.
2. Varsano S, Edelstein E, Gendel B, Smorzik J. Bilateral and unilateral spontaneous massive hemothorax as a presenting manifestation of rare tumours. *Respiration* 2003; 70: 214-8.
3. Dainese E, Pozzi B, Milani M, Rossi G, Pezzotta MG, Vertemati G et al. Primary pleural epithelioid angiosarcoma a case report and review of the literature. *Pathol Res Pract* 2010; 206: 415-9.
4. Moriya Y, Sugawara T, Arai M, Tsuda Y, Uchida K, Noguchi T et al. Bilateral massive bloody pleurisy complicated by angiosarcoma. *Intern Med* 2006; 46: 125-8.
5. Patel AM, Ryu JH. Angiosarcoma in lung. *Chest* 1993; 103: 1531-5.
6. Zhang PJ, Livolsi VA, Brooks JJ. Malignant epithelioid vascular tumours of the pleura: report of a series and literature review. *Hum Pathol* 2000; 31: 29-34.
7. Roh MS, Seo JY, Hong SH. Epithelioid angiosarcoma of pleura. *J Thorac Imaging* 2003; 18: 200-3.
8. Maziak DE, Shamji FM, Peterson R, Perkins DG. *Ann Thorac Surg* 1999; 67: 839-41.
9. Aozasa K, Naka N, Tomita Y, Ohsawa M, Kanno H, Uchida A et al. Angiosarcoma developing from chronic pyothorax. *Mod Pathol* 1994; 7: 906-11.
10. Light RW. Hemothorax. In: Light RW, Pleural Diseases, eds. 2nd ed. Philadelphia: Lea & Febiger, 1990; pp 263-7.