

Bilateral Idiopathic Ossification of the Auricles

Pages with reference to book, From 185 To 186

Raheel Ahmed (Medical School, The Aga Khan University Hospital, Karachi.)

S.S.M. Hussain (Departments of Otolaryngology Head and Neck Surgery, The Aga Khan University Hospital, Karachi.)

J. Rees (Departments of Radiology, The Aga Khan University Hospital, Karachi.)

Introduction

Petrification of the auricle is a recognized and distinct pathological entity¹. This involves ossification or calcification of the auricular cartilage resulting in hardening of the auricle which is clinically evident on palpation and can be confirmed through radiological imaging. The aetiology of this unusual phenomenon is varied and includes both local and systemic causes. Systemic conditions associated with this disorder include endocrine disorders like Addison's disease², acromegaly³ and hypopituitarism⁴, collagen disorders like scleroderma⁵ and systemic diseases like alkaptonuria⁵, gout⁶ and sarcoidosis⁷. However, the more common causes of petrification are local in nature namely, trauma⁵ and frostbite⁸. We report on a patient admitted to our hospital who was consequently found to have idiopathic bilateral auricular ossification.

Case Report

An 84-year old man presented to the ENT clinic at the Aga Khan University Hospital. He complained of severe, intractable pain with discharge from the right ear for 1, week, On examination he had large protruding pinnae on both sides which felt hard on palpation but were non-tender. Otoloscopy the right auditory canal was inflamed and granular Pus was sent for culture and sensitivity. The tympanic membrane was not visible. The left ear was normal. Tenderness was also noted over the right post auricular region. The patient had a 25-year history of hypertension and was on anti-hypertensive therapy. He was admitted to the hospital with the diagnosis of necrotizing otitis externa. Treatment was commenced with ciprofloxacin and gentamycin ear drops. Pain was controlled. Standard X-ray film of the mastoid region indicated sclerotic changes in the right mastoid air cells and opacification of the auricular cartilage. CT imaging of the temporal bone indicated middle ear cleft disease and bilateral ossification of the auricular cartilage (Figure 1).

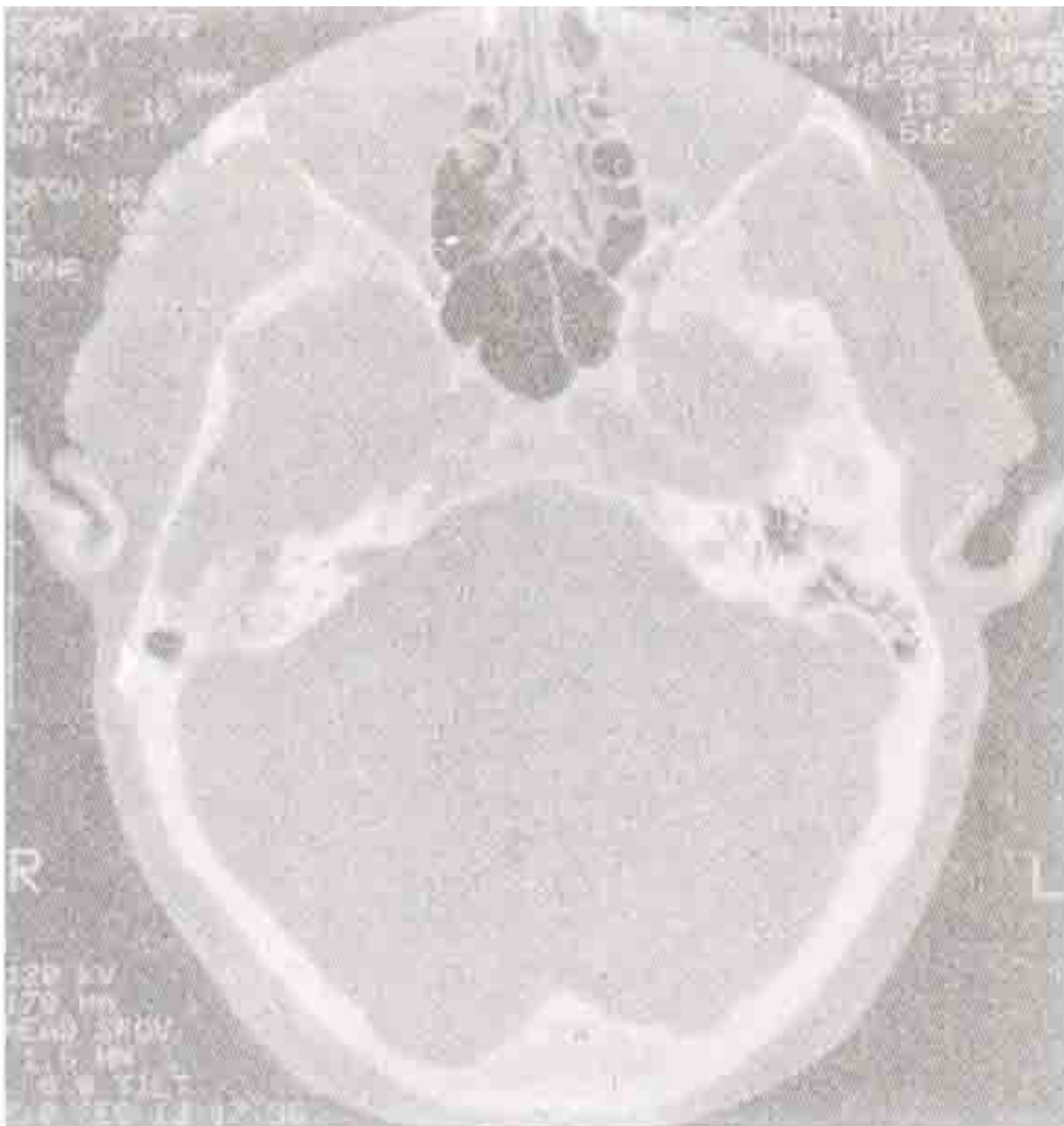


Figure. A computerized tomographical view of the skull showing evidence of ossification within the auricle and the external auditory canal.

With resolution of otitis externa, the tympanic membrane became visible. A central perforation was noted. This was discharging. Ear swabs did not yield any microbiological growth on cultures on two occasions. Blood count of hemoglobin and differential cells was normal. Since there was a rise in serum creatinine level, the dose of ciprofloxacin was reduced.

Discussion

The nonnal human auricle consists of elastic cartilage, the pliability and elasticity of which is attributed to the presence of elastic fibers present in the cartilage matrix⁹. Since the elastic cartilage of the auricle does not normally ossify, auricular ossification takes place through ectopic bone formation¹⁰. Ectopic bone formation occurs through a process whereby mesenchymal cells with osteo-chondrogenic

potential are stimulated to differentiate into mature bone forming osteoblasts responsible for the ectopic formation of lamellar bone through endochondral ossification. This complex histological phenomenon is mediated through documented cellular mediators like Bone Morphogenic Protein (BMP) and Bone Derived Growth Factor (BDGF)¹¹.

DiBartolomeo (1985)⁸ reported that the first documentation of the involvement of the auricular cartilage in ectopic ossification and calcification was observed by By Bochdalek as far early as in 1866. The incidence of petrification involving either calcification or ossification has been extremely variable^{5,8}. Therefore, overall estimation of prevalence is difficult to assess especially for auricular ossification since this is the rarer of the two causes for petrification. Review of literature has indicated that apart from attempts by Gordon, 1964⁵ and Scherrer, 1932¹² all other reports in this respect have been incidental findings at clinical examination.

In the review of cases of histologically validated reports of auricular ossification by DiBartolomeo (1985)⁸ the most frequent and identifiable cause was a previous or present history of frostbite involving the pinna. Though Friedman and Kritzler (1946)¹³ proposed a hypothesis, the pathogenesis of ossification due to hypothermia has yet to be clearly elucidated. The critical triggering factor inducing differentiation of the pluripotent mesenchymal stem cells into osteo-progenitor cells has not been identified. Chalmers et al (1975)¹⁴ concluded that whether or not the tissues of the body ossify may depend on a fine balance of osteogenic and osteoinhibitory influences acting both locally and systemically. It may therefore be prudent to assume, from the authors' point of view, that regenerative activity in the disrupted tissues following hypothermic exposure has a proosteogenic influence which leads to induction of osteoprogenitor cells and therefore induces bone formation. As to why such influences act only in certain and not all damaged parts of the body is largely unknown.

Since detailed questioning of the patient ruled any past history of exposure to extreme cold temperatures or any frostbite, the radiologically documented and the clinically evident auricular ossification of this patient was termed of idiopathic origin.

Though auricular ossification is regarded as a rare clinical occurrence, the clinician must be alert to the possibility of such infrequent and unusual clinical idiosyncrasies.

References

1. Disorders of the bone, Chapter 11. In Schuknecht HF Pathology of the ear. 2nd edition. Lea and Febiger, Box 3204 Zocheater Field Pathway, Malvern, Pennsylvania, 1993, pp. 408.
2. Jarvis it, Jenkins D, Sosman MC et al. Roentgenologic observations in Addison's disease; Review of 120 cases. Radiology, 1954;62: 16-29.
3. Nathanson L, Losner S. Ossification of auricles of external ears associated with acromegaly. Radiology. 1947;48:665-67.
4. Barkan A, Glantz I. Calcification of auricular cartilage in patients with hypopituitarism. J. Clin. Endocrinol. Met., 1982;55:354-357.
5. Gordon DL. Calcification of auricular cartilage. Arch. Intem. Med., 1984;1 13:23-27.
6. Greenfield GB. Radiology of bone diseases, J. B. Lippincot Co., Philadelphia, 1969. pp. 420.
7. Batson JM. Calcification of ear cartilage associated with the hypercalcemia of sarcoidosis. N. Engl. J. Med., 1969;265:876-877.
8. DiBarolomeo JR. The petrified auricle: Comments on ossification, calcification and exostoses of the external ear. Laryngoscope, 1985;95:566-576.
9. Burkitt GH, Barbara Y, Heath WJ. Wheater's functional histology - A text and color atlas. Third edition, Churchill Livingstone, Edinburgh. 1993. pp. 173.
10. Kewlermani LS. Ectopic ossification. Am. J.Phys.Med. 1997; 56:99-121.

11. Urist MR, DeLange RJ, Finerman GAM. Bone cell differentiation and growth factors. *Science*, 1983;220:680-686.
12. Scherrer FW. Calcification and ossification of the external ear. *Ann. Otol.* 1932;41 :867-885.
13. Friedman N, Kritzler RA. The pathology of high altitude frostbite. *Am. J. Pathol.*, 1946;23:173-187.
14. Chalmers J, Gray DH, Rush J. Observations on the induction of bone in soft tissues. *J. Bone. Joint Surg. Br.* 1975;57:36-45.