

Primary Spinal T-Cell Rich B-Cell Lymphoma: A Case Report

Pages with reference to book, From 148 To 149

Suhail Muzaffar, Irshad Nabi Soomro, Naila Kayani, Shahid Siddiqui (Departments of Pathology, The Aga Khan University, Karachi.)

Yousuf A. Husein (Departments of Radiology, The Aga Khan University, Karachi.)

Rasheed Jooma (Department of Neurosurgery, Jinnah Postgraduate Medical Centre, Karachi.)

Introduction

Non-Hodgkin's lymphoma is a heterogeneous group of lymphoid malignancies with marked variability in morphologic features, growth pattern, antigenic phenotype and biological behaviour. T-cell rich B-cell lymphoma (TCRBCL) is a newly recognised entity of this large heterogeneous group of lymphoid neoplasms which closely mimics Hodgkin's disease and peripheral T-cell lymphoma (PTCL). Most of the cases of TCRBCL have been reported in the lymph nodes, however, a small number of cases have been described in the extranodal sites including skin, soft tissue, common bile duct and central nervous system. Primary spinal TCRBCL with symptoms of spinal cord compression has been described in the literature.

Case Report

A 30 year old man presented with history of paraplegia of three months duration. X-ray of the spine revealed collapsed upper thoracic vertebra and paraspinal mass, however, the pedicles were preserved. Magnetic resonance imaging (MRI) showed partial collapse of upper thoracic vertebra and peripheral extension of the lesion into the spinal canal. The intervertebral discs below and above were preserved (Figure 1).

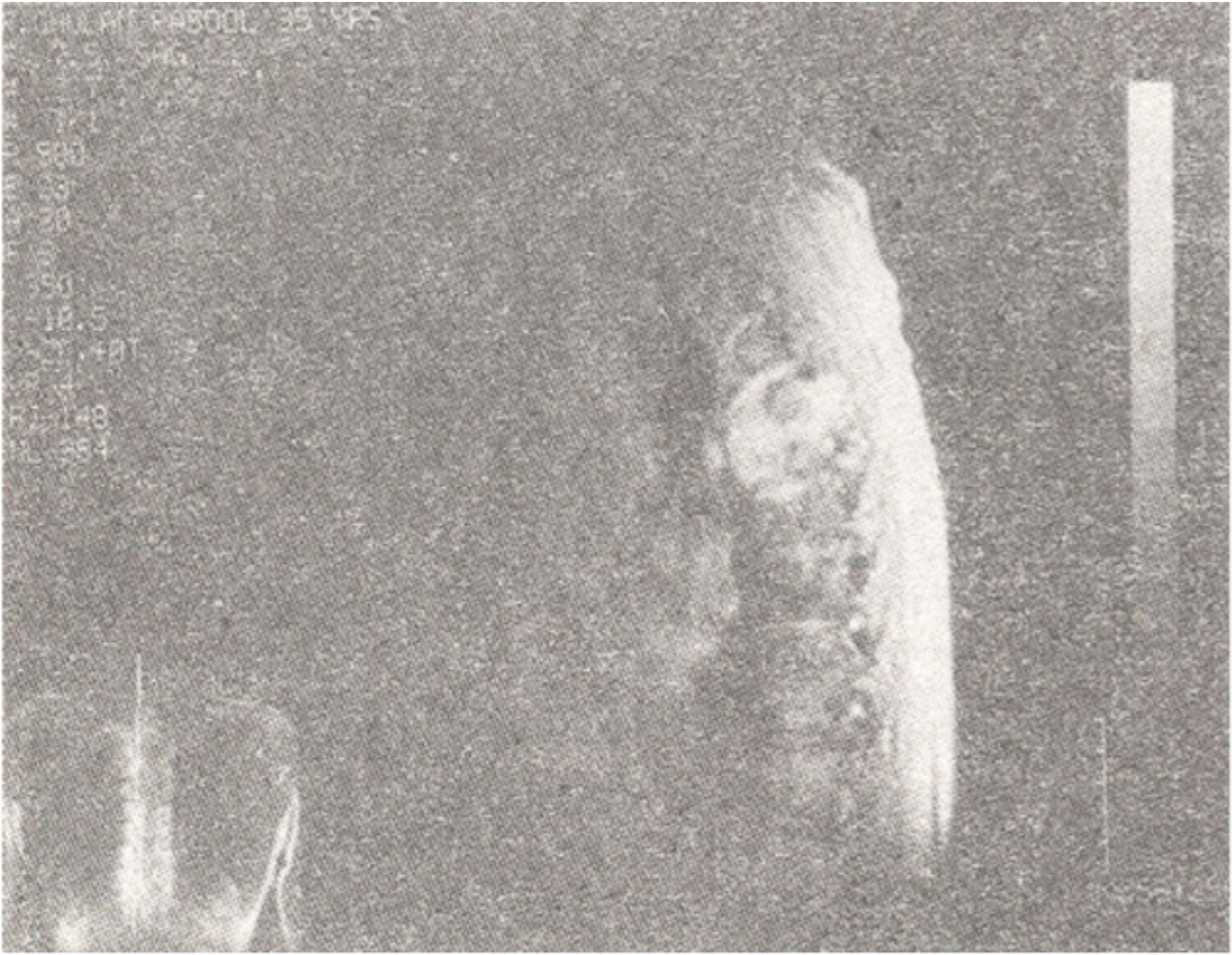


Figure 1. Sagittal T2 weighted image. MR scan shows tumour deposit in upper thoracic vertebra with partial collapse. Posterior extension into spinal canal is evident. Note, intervertebral discs above and below are preserved.

Decompression procedure was performed and histopathological examination of the biopsy material revealed a cellular neoplasm predominantly composed of mature T lymphocytes as revealed by immunocytochemistry. Amidst a small population of atypical cells (10-15%) with large irregular and lobulated nuclei, a small number of plasma cells and neutrophils were seen. Some of these atypical cells show large prominent nucleoli. At places there was prominent vascularity. Foci of necrosis were also present. The differential diagnosis in this case included Hodgkin's disease and peripheral T-cell lymphoma (PTCL). Immunohistochemical studies were carried out using a panel of lymphoid markers including leucocyte common antigen (LCA), pan-B marker (L-26), pan-T marker (UCHL-1) and immunoglobulin light chains (Kappa and Lambda). Phenotypically the large atypical cells were B lymphoid cells (L-26 positive) which also revealed clonal proliferation i.e., lambda light chain restriction (Figure 2).

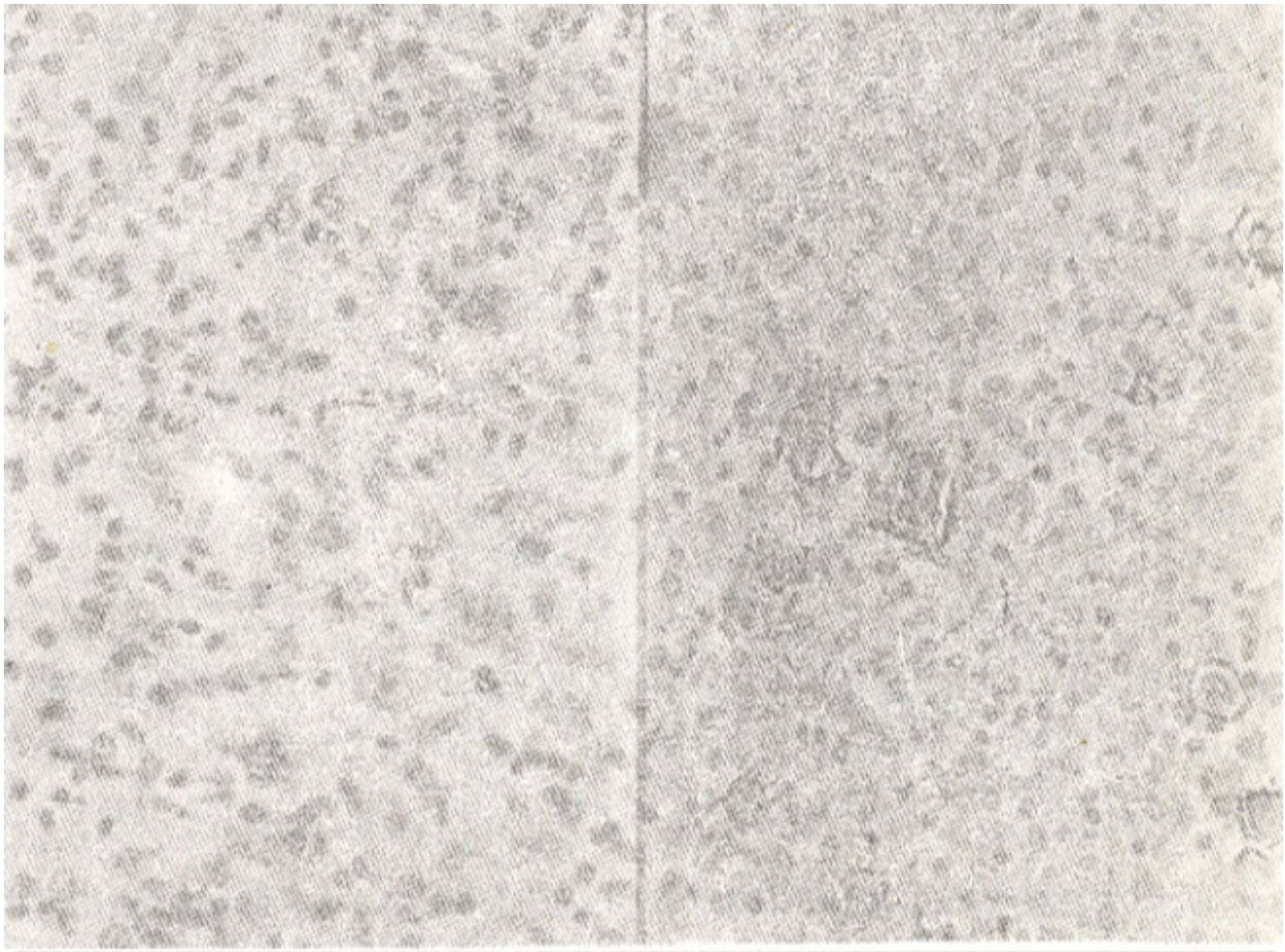


Figure 2. Right Side: H and E stained photomicrograph of the spinal lesion showing atypical cells with large irregular nuclei and prominent nucleoli in a background of mature lymphocytes mixed with plasma cells and occasional neutrophils (Mag. x100). Left side: The section is stained with monoclonal antibody L-26 (CD20). Note: large atypical cells show strong membrane reactivity while the background cells are non-reactive.

Clinical and radiological workup failed to reveal any other source of primary disease. So on the basis of clinical, morphological and immunohistochemical features a diagnosis of primary spinal T-cell rich B-cell lymphoma (TCRBCL) was made.

Discussion

T-cell rich B-cell lymphoma (TCRBCL) is a newly recognised, unusual diffuse non-Hodgkin's lymphoma that contains a minority of neoplastic B cells surrounded by a predominant population of reactive T-cells. This entity was first recognised and presented in abstract form as 'pseudo-peripheral T cell lymphoma'¹. However, some workers preferred the term B-cell lymphoma resembling T-cell lymphoma². Ramsay et al were the first who coined the term T-cell rich B-cell lymphoma (TCRBCL) for this lesion and this has gained wide acceptance³. The criteria for the diagnosis are now well defined as cited by Jaffe and include: a) Mimic peripheral T-cell lymphoma (PTCL) morphologically and phenotypically; b) Majority of the cells are phenotypically normal T-cells; c) Minority of the cells are monoclonal B-cells and d) Immunohistochemistry (especially on paraffin sections) and molecular

genetics are useful in diagnosis -both Ig gene and be 1-2 rearrangements⁴.

However, the upper limit for the number of neoplastic B-cells and minimum T-cells content with reference to the entire cellular population in TCRBCL is still controversial. Some workers used an arbitrary figure of 50% as minimum T-cells population in TCRBCL⁵, whereas Jaffe and co-workers proposed that it should be greater than 75%. According to Rainsay and colleagues the T-cell content should be 90% or above whereas Baddoura and co-workers proposed that 'until more meaningful limits can be established in future studies, the percentage of T and B-cells are reported in the majority of cases in the literature and in this study, should be used for the diagnoses of TCRBCL; an upper limit of 25% for the neoplastic B-cell population and a lower limit of 75% for T- lymphocytes. However, the percentage of T-cells required for diagnoses may be reduced in cases with a large number of histiocytes⁶. Immunohistochemical analysis particularly on paraffin sections is essential to establish the diagnosis of TCRBCL and in most cases these studies are sufficient to establish the monoclonal nature of the B-cells. The most characteristic immunophenotypic features are L-26 and monotypic cytoplasmic Ig reactivity by neoplastic cells.

The main differential diagnoses for TCRBCL are peripheral T-cell lymphoma (PTCL) and Hodgkin's disease, particularly the lymphocyte predominant type (LPHD). In the later the presence of L&H cells, lack of conspicuous vascularity, significant mixture of small B-cells and inability to demonstrate B-cell monoclonality are important distinguishing features. PTCLs pose important diagnostic problems, as TCRBCLs are easily confused with this morphologically heterogeneous group of non-Hodgkin's lymphoma (NHLs). Majority of the TCRBCLs are diffuse and may resemble one of the patterns described for PTCLs, for example, lymphocytic infiltrate of mixed size, compartmentalisation by delicate connective tissue septa and hypervascularity. TCRBCL with prominent histiocytic component may resemble Lennert's lymphoma. Cases of TCRBCL with T-zone distribution and sparing of benign follicles have also been described. It is worth noting that a number of cases which have been placed in the category of PTCLs might have actually TCRBCLs. For a pathologist it is important to recognise this newly emerged entity and distinguish it from Hodgkin's disease and peripheral T cell lymphoma because of different therapeutic modalities. With reference to the International Working Formulation there are basically two school of thoughts for placing TCRBCLs into this classification system. One group feels that mixed population of morphologically atypical small and large lymphoid cells should be taken into account and the lesion should be placed in diffuse mixed cell (DMC) category. The other group argues that since only the large cell are neoplastic, these cases should be classified into either the diffuse large cell (DLC) or the diffuse large cell immunoblastic (DLCL) subtypes whereas in Revised European American Lymphoma (REAL) classification this entity has been placed in category of diffuse large B cell lymphoma. Since DMC, DLC and DLCL lymphomas are treated similarly in most institutions, so this issue is of only academic importance. The clinical data of these lymphomas is limited. Majority of the cases are presented in adults in their sixties with a slight male predominance. To date approximately 95 to 100 cases of TCRBCL have been reported in the international literature, most of which are seen in the lymph nodes^{3,6,7}. However, a handful of cases have been reported as primary extranodal TCRBCL including skin⁶, soft tissue⁷, common bile duct⁸ and central nervous system⁹. Our case is probably the first case report of primary extranodal TCRBCL arising in the spine (Stage IE) and causing cord compression.

References

1. Jaffe, ES. Pseudo-peripheral T-cell lymphomas. In Jaffe, ES. ed. Surgical pathology of lymph nodes and related organs. Philadelphia, WB Saunders, 1985, pp. 230-231.
2. Mirchandani, I., Palutke, M., Tabaczka, P. et al. B-cell lymphomas morphologically resembling T-cell lymphomas. *Cancer*, 1985;56:1578-1583.

3. Ramsay, A.D., Smith, V.J and Isaacson, P.O. T-cell rich B-cell lymphoma. *Am. J. Surg. Pathol.*, 1988;12:433-443.
4. Jaffe, ES., T-cell rich B-cell lymphoma (TCRBCL). In Jaffe, ES. ed. *Surgical pathology of lymph nodes and related organs*. Philadelphia, W.B. Saunders, 1995, pp. 356-358.
5. Ng, CS., Chan, J.K.C., Hui, P.K. et al. Large B-cell lymphomas with a high content of reactive T-lymphocytes. *Hum. Pathol.*, 1989;20:1145-1154.
6. Baddoura, F.K., Chan, V.C., Masih, AS. et al. T-cell rich B-cell lymphoma: A clinicopathologic study of eight cases. *Am. J. Clin. Pathol.*, 1995; 103:65-75.
7. Macon, W.R., Williams, M.E., Greer, J.P. et al. T-cell rich B-cell lymphomas: A clinicopathologic study of 19 cases. *Am. J. Surg. Pathol.*, 1992;16:351-363.
8. Brouland, J.P., Molimard, J., Nemeth, J. et al. Primary T-cell rich B-cell lymphoma of the common bile duct. *Virchows. Arch. Pathol. Anat. Histopathol.*, 1993;423 :513-517.
9. Okuyama, J., Fujita, T., Sato, K et al. Primary malignant T-cell rich B-cell lymphoma of the central nervous system: A case report. *No Shinkei. Geka*, 1995;23:1003-1006.