

# Esophageal Foreign Body in Neonates

Z. Tasneem, M.A.M. Khan, N. Uddin

Section of Pediatric Surgery, Department of Surgery, Aga Khan University Hospital, Karachi.

## Introduction

Ingestion of foreign body in pediatric population is a common but serious incident. Curiosity and preference to oral exploration are the two key factors in its prevalence. Children of the age 5 months - 8 years are the highest risk for a foreign body.<sup>1</sup> In neonates such an occurrence is rare<sup>2-4</sup> and may pose a difficult management problem for the surgeons. The successful location and extraction of this foreign body demands substantial patience, skills and a multidisciplinary team approach. This paper primarily focuses on the management problems encountered and various options available; in particular use of pediatric bronchoscope with optical forceps for retrieving ingested foreign bodies in neonates.

## Case Report

### Case 1

A three-day-old female baby was admitted, suffering from dyspnea and excessive drooling. She had swallowed a piece of jewelry presented to her by the grandmother. Plain x-ray revealed an impacted finger ring in the upper part of esophagus (Figure 1A). The foreign body (Figure 1B), was removed successfully under general anesthesia by using pediatric bronchoscopic sheath (3.5' 26 cm, Storz) with fiberoptic rigid grasping forceps (35 cm, Storz) (Figures 2A and 2B).

### Case 2

A two days old premature baby presented in the emergency room with severe respiratory distress. She was accidentally intubated in the esophagus. The cut endotracheal tube slipped into the esophagus with the other end reaching the stomach (Figure 3A). The baby was re-intubated in the trachea and after stabilization the displaced endotracheal tube (Figure 3B), in the esophagus was removed under general anesthesia, using pediatric bronchoscope sheath (3.5x26 cm, Storz) with fiberoptic rigid grasping forceps (35cm, Storz) (Figures 2A and 2B) without any complications.

## Discussion

One of the most serious causes of morbidity and mortality in children below 5 years of age are swallowed and inhaled foreign bodies; children of age 5 month - 8 years are at the highest risk of foreign body ingestion.<sup>1</sup>

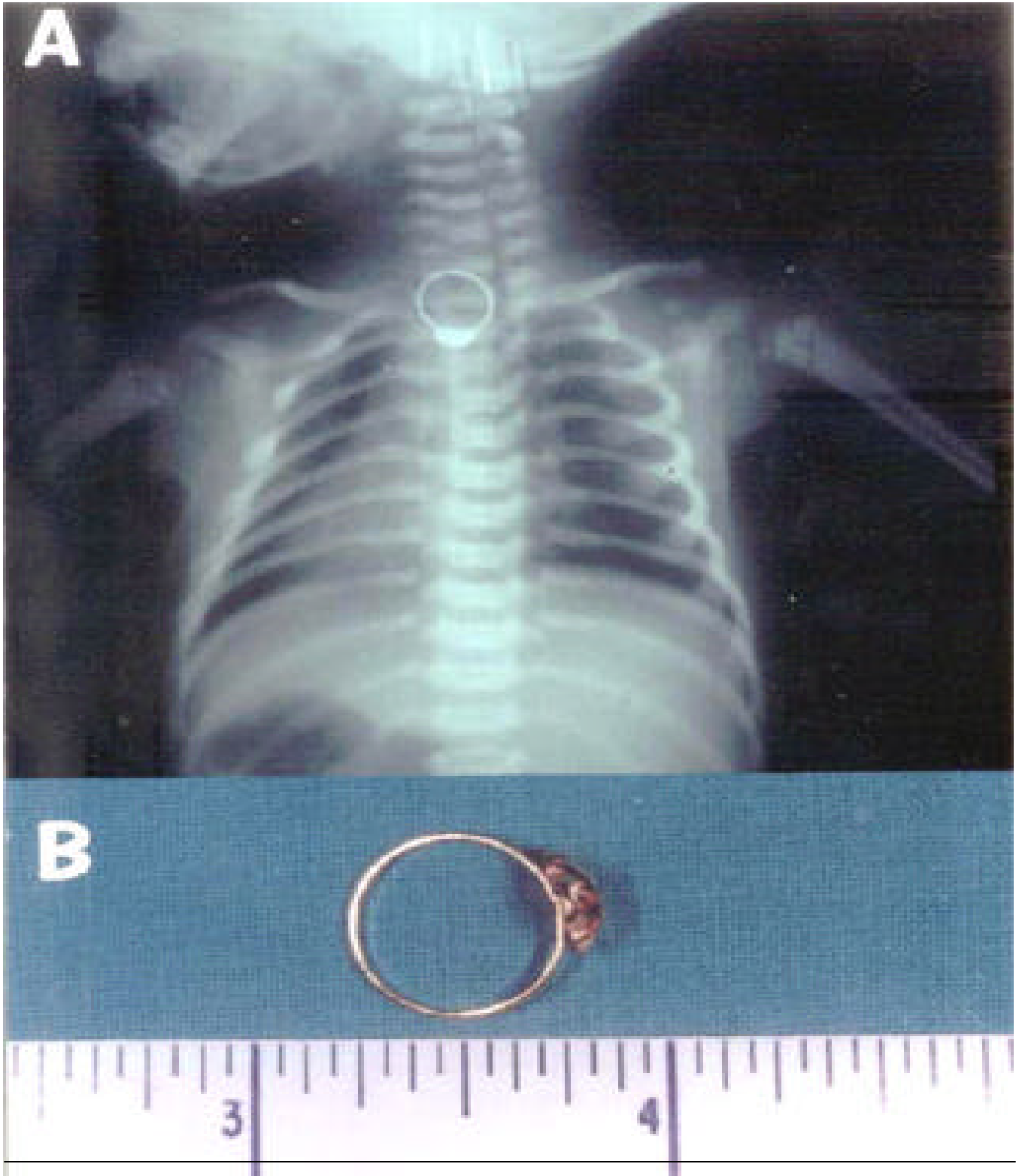
However, the incidence of esophageal foreign body in neonate is rare.<sup>2-4</sup> To the best of our knowledge these two cases are the youngest yet reported in English literature.

Most common esophageal foreign body in neonates is a swallowed endotracheal tube<sup>5,6</sup>, however, there are other examples mentioned in the literature including stone<sup>7</sup>, bean<sup>8</sup>, button<sup>9</sup> and even a thumb tack.<sup>10</sup> Most of these cases were more than two weeks old. One of our patients had endotracheal tube and other had a finger ring impacted in their esophagi, both were less than 72 hours old.

If the incident has not been witnessed and the ingested object is radiolucent, the diagnosis of foreign body ingestion can be very tricky in neonates. Because respiratory distress is the most common manifestation of a foreign body in oesophagus in younger children, it may lead to a misdiagnosis of some respiratory disorder.<sup>9,11</sup> Beside typical symptoms of choking, gagging, dysphagia or drooling, esophageal foreign body in neonates has been associated with hematemesis and malena.<sup>7</sup>

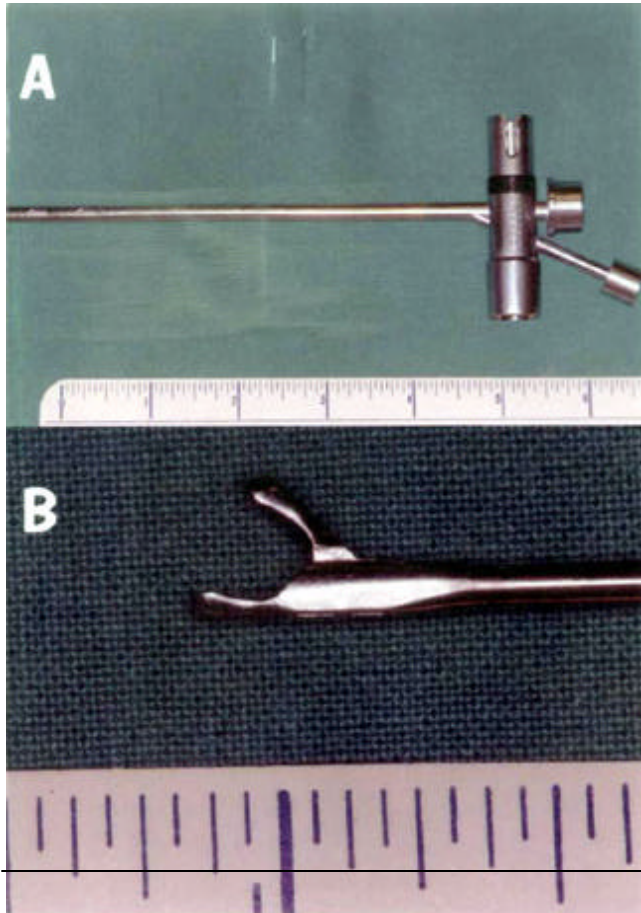
A simple x-ray followed by a contrast study (if needed) can help in establishing the diagnosis. The combined sensitivity and specificity of x-ray and contrast study is 99% and 80% respectively.<sup>12</sup> Fortunately in our cases the diagnosis was not much of a problem as one had a radio opaque foreign body (finger ring) evident on x-ray with typical presentation. The other baby had an evident event of ingesting a foreign body (endotracheal tube).

Among children below 3 years of age the impaction of foreign body is common<sup>2</sup>, necessitating prompt removal. Frequent lodging sites are the constrictions at the levels of cricopharyngeus muscle, aorta, left main bronchus and lower esophageal sphincter. For removing a foreign body various methods have been described, like Foley's catheter, rigid endoscopy and fiber optic endoscopy.<sup>13,14</sup> While removal under direct vision is the method of choice, conventional pediatric esophagoscopes of small size are difficult to work with, because of limited "straw" vision. This visual field is further diminished by the passage of manipulating instruments through the lumen. As a result, grasping takes place in a semi-blind manner. We found that this problem was overcome to a great extent by using an optical forceps within a small pediatric bronchoscopic channel. Its application combines the advantage of excellent visualization and a larger forceps, which can be applied with more precision.



Swallowed or inhaled foreign bodies are among the most serious and common causes of morbidity and mortality in pre-school children. However, such occurrence is very rare in infants and newborns. With the introduction

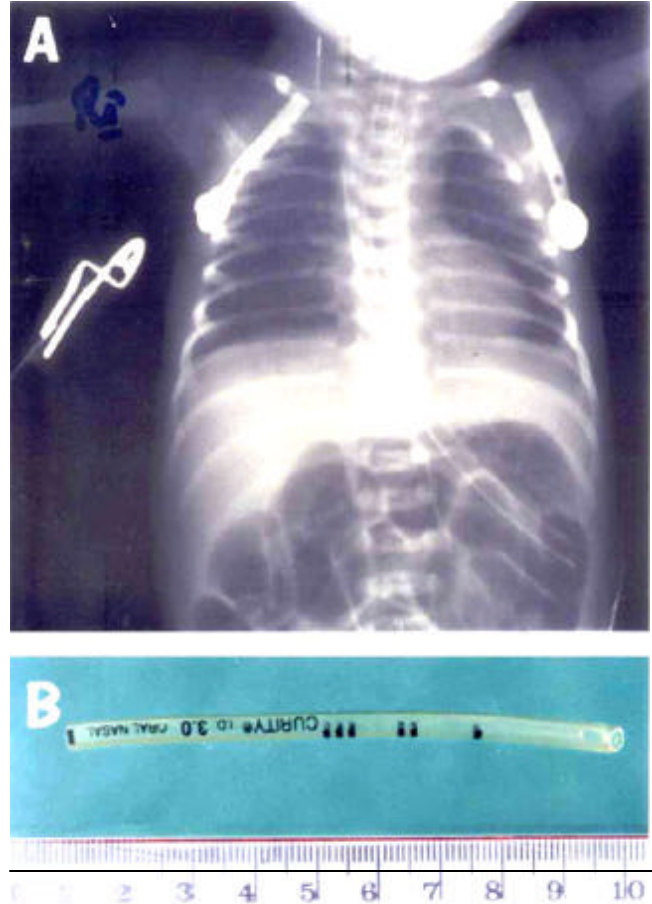
of the optical forceps in pediatric bronchoscope, it allows foreign body manipulation with excellent positional control of the tip in smaller diameter of neonatal esophagus. In our experience, we found it to be more convenient and efficient



as compared to the conventional esophagoscope.

### References

1. Al-Salem AH, Qaisarrudin S, Murugan A, et al. Swallowed foreign bodies in children: aspect of management. *Ann Saudi Med* 1995;5:419-21.
2. Elli PDM, ARdn GM. Esophageal foreign bodies in an infant. *J Laryngol Otol* 1973;87:691-8.
3. Crysdale WS, Sendi K.S, Yoo J. Oesophageal foreign bodies in children: 15 years review of 485 cases. *Ann Otol Rhinol Laryngol* 1991;100:320-24.
4. Jones NS, Lanningan FJ, Salama NY. Foreign bodies in the throat: a prospective study of 388 cases. *J Laryngol Otol* 1991;105:104 -8.
5. Banerjee A, Rao BK. Lower esophageal foreign body in a neonate (letter). *Indian Pediatr* 1983;20:384.
6. MacKinlay GA, Wilson Storey D, Hendry GM. The ectopic endotracheal tube. *J R Coll Surg Edinburg* 1987;32:310.
7. Thapa B R, Kaur B, Nagi B, et al. Unusual foreign body (stone) in the



8. Dogruyol H, Gurpinar AN. A foreign body in a four-day-old infant's esophagus: a case of negligence. *Turk J Pediatr* 1989;31:163-6.
9. Chowdhury CR, Bricknell MCM, MacIver D. Oesophageal foreign body: an unusual cause of respiratory symptoms in a three-week-old baby. *J. Laryngol Otol* 1992;106:556-7.
10. Al-Odaidan N, Amu OD, Fahmy M, et al. An unusual case of impacted esophageal foreign body. *Saudi Med J* 2000; 21:202-3.
11. Friedman EM. Foreign bodies in the pediatric aero-digestive tract. *Pediatr Ann* 1988;17:640-2.
12. Taylor RB. Esophageal foreign bodies. *Emergency medicine clinics of North Am* 1987;5:301-11.
13. Carlson DH. Removal of coins in the esophagus by using Foley's catheter. *Pediatrics* 1972;50:475.
14. Christie DL, Ament ME. Removal of foreign bodies from esophagus and stomach with flexible panendoscope. *Pediatrics* 1976;57:931-4.