

## Chemotherapy-induced Neutropenic Necrotizing Enterocolitis: A Review

Itrat Mehdi, Bassim Al Bahrani

Department of Medical Oncology, National Oncology Center, The Royal Hospital, Muscat, Sultanate of Oman.

Corresponding Author: Itrat Mehdi. Email: [itrat\\_mehdi@yahoo.com](mailto:itrat_mehdi@yahoo.com)

### Abstract

Neutropenia is a common toxicity of systemic cytotoxic therapy. Neutropenic enterocolitis (NE) is a rare occurrence but can be fatal, subsequent to neutropenia. The exact incidence and frequency is difficult to establish, but is usually underestimated. It is often missed but has recently been appreciated with increasing frequency in solid tumours. NE was initially reported with taxanes but now an increasing number of chemotherapeutic drugs are implicated. NE incidence is expected to increase with the use of dose dense regimens, myeloablative cytotoxic protocols, tissue transplants, and emerging newer molecules.

The usual presentation is often non-specific and often over shadowed by the symptomatology of primary malignant disease and toxicity symptoms of chemotherapy. The basis of diagnosis is clinical, radiological (ultra sound/CT scan), per operative findings, and eventually post mortem. Treatment options of this highly fatal phenomenon varies from conservative to early surgical intervention.

NE is expected to be diagnosed with increasing frequency. The factors leading to it are mucosal injury, caecal distension with resultant ischaemia, cytotoxic drugs, and microbiological agents. A high index of clinical suspicion and an early diagnosis is paramount for better outcome. Irrespective of management employed, conservative or upfront surgical intervention, it has a poor out come with high mortality.

A clinical suspicion, early diagnosis, and prompt management are the key to a better result. There is need to identify people at high risk by prognostic factors, large scale studies, and formulating consensus management guidelines. At present individualized risk assessment based strategy is advocated.

**Keywords:** Neutropenia, Enterocolitis, Necrotizing, Chemotherapy-induced, NE.

### What is Neutropenic enterocolitis (NE) and Chemotherapy induced NE?

Chemotherapy induced neutropenia is a frequently encountered complication of intensive chemotherapy in oncology practice.<sup>1,2</sup> Neutropenia with immune-compromised status by malignant disease, and low functional reserves predispose the cancer patients to further grave and fatal

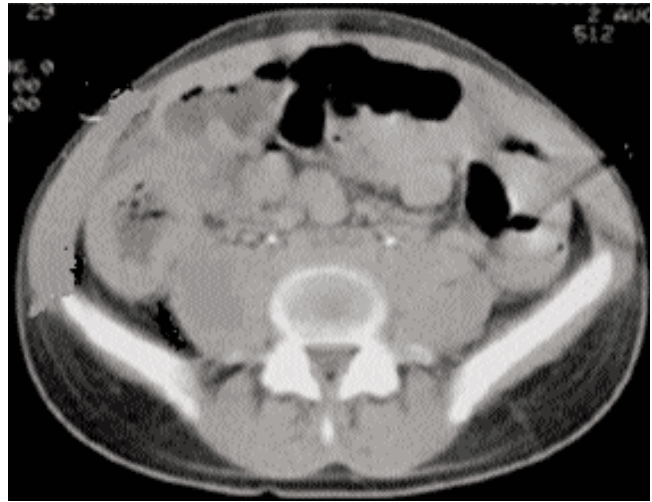


Figure-1: A CT scan picture of a case of Neutropenic enterocolitis showing thick walled caecum, fluid filled and dilated loops of intestines.

complications. Neutropenic enterocolitis (NE), ileocaecal syndrome, agranulocytic colitis or necrotizing enterocolitis is a rare phenomenon seen in neutropenic patients. Neutropenic enterocolitis is a specific disease entity, usually manifesting itself with diarrhoea.<sup>1,2</sup> NE is classically characterized by transmural inflammation of the intestines in neutropenic patients who are experiencing severe myelosuppression. The entire gut can be affected but commonly involved areas are from terminal ileum to ascending colon. Caecum is almost always involved probably due to its low vascular supply and perfusion.<sup>2</sup> The affected gut becomes oedematous, thick walled; with mucosal ulceration, ecchymoses, fibrin exudates, and partial to full thickness haemorrhagic necrosis often discovered only at autopsy.<sup>3</sup> Most of the earlier reports have focused on typhlitis, which may be regarded as a localized form of neutropenic enterocolitis limited to caecal inflammation.<sup>2,3</sup> The disease spectrum varies from a mild self limiting form of disease to fatal transmural pathology. NE usually occurs between 1st-2nd week post chemotherapy corresponding to neutrophil count nadir.<sup>4</sup> The exact etiology and progression of neutropenic enterocolitis are unknown, profound neutropenia appears to be the common denominator.

NE was initially described and often seen in paediatric

patients of post-chemotherapy neutropenia, as high as 38-46% in paediatric haematologic malignancies usually presenting with intestinal perforation.<sup>5</sup> NE is also reported in other conditions associated with bone marrow failure and low white cell counts like aplastic anaemia, myelofibrosis, Myelodysplastic syndrome, bone marrow infiltration, and AIDS.<sup>6</sup> The increased usage of upfront myeloablative therapy, standard of care combination polychemotherapy, protracted and prolonged many lines of chemotherapy, and newer drugs may increase the number of cases reported in future.<sup>2</sup>

Epidemiological data about neutropenic enterocolitis are conflicting because of the heterogeneity of the patient populations analyzed, variable diagnostic criteria being used and duration of patient follow-up in the data published.<sup>7</sup> Additionally the exact incidence and prevalence rate of NE are unknown. This is because many patients who survive are never diagnosed, and there is no gold standard of diagnosis. In adults, very variable incidence rates between 0.8% and 26% have been reported,<sup>7,8</sup> with mortality rates up to 63%.<sup>4,9</sup> Studies in paediatric patient populations demonstrated incidence rates of 0.35%-6.1%<sup>9</sup> and mortality rates up to 71%.<sup>7-9</sup> A prevalence rate of 24% and a mortality rate of 34% are reported in children. Data regarding its incidence and prevalence in adults is sparse, yet 5.3% incidence rate has been reported in adults from pooled data in USA.<sup>10-12</sup> International data has reported an incidence rate from 3-6%.<sup>10</sup> Pooled analysis of 21 studies involving 5058 patients/neutropenic episodes revealed a 5.3% incidence for neutropenic enterocolitis in adults.<sup>11</sup> These results, although variable, prompt the importance of neutropenic enterocolitis as a clinical problem.

### Which Chemotherapy drugs are Implicated in NE?

The reported cases of NE were seen at median 7th day post chemotherapy, earlier than anticipated neutrophil nadir of 10-14 days. The mortality is reported as high as 45% in different series of cases.<sup>12</sup> The possible implicating risk factors are direct drug related mucosal injury, cytopenias, Disseminated Intravascular Coagulation (DIC), and steroid therapy. The steroids can delay wound healing, cause hyperglycaemia, impair cellular and humoral immunity, impair mucosal integrity, and decrease resistance to pathogens.<sup>2</sup> A pre-existing breach of intestinal mucosal integrity by tumour, a previous abdominal surgery, a diverticular disease or intestinal polyposes are additional risk factors.<sup>2,4</sup>

NE is reported with increasing frequency amongst adult patients treated for solid tumours, in the era of more used dose dense and high dose chemotherapy and transplantation.<sup>2,10,12,13</sup> NE is now reported in treated cases of cancer breast (MBC), Lung (NSCLC), ovary, esophagus, and prostate (CRPC) while on chemotherapy.<sup>3,12-17</sup> It is described with the use of many

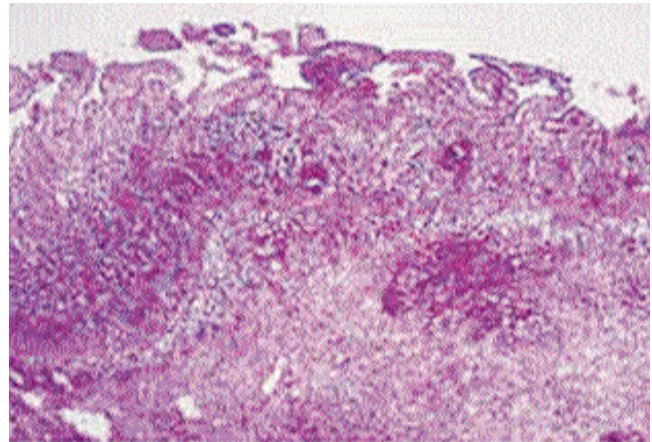


Figure-2: Microscopic features of neutropenic enterocolitis include diffuse bowel wall thickening, mucosal and intramural edema, mucosal ulcerations, necrosis, and intramural or intraluminal hemorrhage.

chemotherapy agents like taxanes, 5-Fluoro uracil, epirubicin, cyclophosphamide, platinum derivatives, vinorelbine, ifosfamide, etoposide, pegylated interferon, cytosine arabinoside, vinca alkaloids, sulphasalazine, procainamide, gemcitabine, pemetrexed, and alemtuzumab.<sup>1,2,14-19</sup> Taxanes alone or in combination appears to predispose a higher risk.<sup>12,13</sup> A continuous infusion regimen of chemotherapy is more likely to be a predisposing factor for NE.<sup>2</sup> An incidence of 0.6% is reported with the use of taxanes which cause mucosal cell mitotic arrest and epithelial necrosis in GI tract.<sup>2,12,14</sup> In 5-FU treated cases of solid tumours, NE is more likely to be seen with DPD (dihydropyridine dehydrogenase) deficient patients.<sup>1,2,15</sup> NE is also reported post chemotherapy in patients, even with normal neutrophil counts.<sup>2</sup> In an era where new molecules and targeted agents are increasingly being incorporated in chemotherapy regimens, the long term effect of these combinations are yet to be seen in terms of NE incidence and treatment outcome.

### What is the patho-biology of NE?

NE is believed to be associated with chemotherapy-induced intestinal mucosal injury, followed by a superinfection (usually by Gram-negative bacteria) and may lead to bacteraemia.<sup>1,2,11</sup> However, other fungal and viral pathogens are also identified and isolated in many cases. Despite the controversy surrounding the direct role of chemo toxic agents in the pathophysiology of NE, ischaemic necrosis is believed to be the triggering factor, followed by bacterial invasion in the background of severe neutropenia.<sup>2,8,10,11,19,20</sup>

Many cytotoxic drugs can directly damage the intestinal mucosa.<sup>20</sup> The inherent deficit immune response of a malignant disease patient causes over growth of normal intestinal flora. There can be acquired nosocomial infections due to empirical administration of antibiotics. The associated thrombocytopenia

and element of DIC contribute to gut haemorrhages. In up to 80% stool or blood cultures were found positive and common microbial isolates identified include clostridium species, E. coli, Candida species, Pseudomonas species, gram positive cocci, gram negative bacilli, and other fungi.<sup>11,20-22</sup>

A systemic analysis of NE has identified many factors that may potentially play a role in the pathogenesis, and these include:

- ◆ Mucosal injury caused by cytotoxic drugs: mucosal injury can occur in the absence of cytotoxic therapy, and neutropenia itself can cause mucosal ulcerations.
- ◆ Distension of Caecum: Whether primary or secondary to vinca alkaloids, caecal distention may compromise the arterial vascular supply, causing further mucosal damage.
- ◆ Concurrent Drugs utilized: antibiotics and steroids may contribute to an altered enteric bacterial flora and overgrowth of fungi.
- ◆ Micro bacteria: bacterial or fungal invasion of the impaired bowel wall may result in transmural inflammation, perforation and ultimately peritonitis.

One of the studies showed that administration of mitoxantrone and anthracyclines was associated with an increased occurrence of diarrhoea. Mitoxantrone and anthracyclines, like all other cytotoxic drugs, have the potential to cause diarrhoea and neutropenic enterocolitis.<sup>19,21</sup> Diarrhoea induced by cytotoxic compounds is most likely due to mucositis, but may also be due to the alteration of the bacterial flora of the gut.<sup>7,8,10,11,22</sup>

### **What is the Clinical Presentation of NE?**

The presenting features of NE are un-explained fever, protracted diarrhoea, bleeding per rectum, vague abdominal pain and progressive abdominal distension in the background setting of neutropenia. The typical presentation can mimic acute appendicitis or local/diffuse peritonitis. Usually the pain is in right lower quadrant of abdomen (cramping, intermittent or continuous dull pain); with nausea, vomiting, local or diffuse abdominal distention, and oropharyngeal mucositis. The physical signs may vary depending on the severity, location, and the presence or absence of complications. They may include abdominal distention, tenderness in right lower abdomen, mass in right iliac fossa, hypoactive bowel sounds, and a tympanitic abdomen (ileus). Rebound tenderness and rigidity suggest colonic perforation, while shock is a sign of septicemia.<sup>4,5,8-10</sup>

### **How NE can be diagnosed?**

The diagnosis is aided by transabdominal ultra sound and CT scan. There is a very minimal role played by plain X-rays or barium studies due to risk of perforation.<sup>2,22-26</sup> Colonoscopy is usually contraindicated and should be avoided.

A bowel wall thickness of more than 4 mm and intestinal pneumatosis are highly suggestive, and differentiate with other pathology. Bowel wall thickness is directly related to duration of NE, subsequent outcome, and mortality.<sup>2,22,24</sup>

X-rays of abdomen is usually non specific and may be normal (False Negative 48%). It may show right colon or small gut dilatation, thumb printing sign in right colon, paucity of air in right colon, or intramural pneumatosis. Ultrasonography is quite useful (False negative 23%) and shows gut wall thickening,<sup>23,24,27,28</sup> which correlates with the duration of NE and in predicting the outcome. In bowel wall thickening of 5 mm and > 10 mm, the mortality is 29% and 60% respectively.<sup>23</sup> A CT Scan is the investigation of choice (False negative 15%). It can show symmetrical thick walled and fluid filled caecum, pericaecal inflammation, free air in case of perforation and portal venous gas presence.<sup>24-29</sup> Colonoscopy examination is usually contraindicated due to risks associated with cytopenia, bleeding, and the potential risk of gut perforation.<sup>24,30</sup>

With the advent and refinement of imaging techniques, computed tomography (CT) and ultrasonography have become the cornerstones for diagnosis. These are necessary to rule out other acute or sub-acute intra-abdominal pathology. Neutropenic enterocolitis should be a diagnosis of exclusion. Controversies still exist about the specificity, sensitivity and predictive values of certain diagnostic findings. Intestinal wall thickening has been indicated to be specific for neutropenic enterocolitis in many studies,<sup>22,23,27</sup> but has also been reported in C. difficile-associated enterocolitis and bowel ischaemia.<sup>11,22,27-29</sup> Current available data on diarrhoea in neutropenic patients and neutropenic enterocolitis are limited to case reports, retrospective analyses or autopsy series.<sup>29</sup> Few prospective studies have either investigated neutropenic enterocolitis among neutropenic patients with acute leukaemia or those undergoing bone marrow transplantation<sup>7,26,28</sup> or have focused on all GI or infectious complications exclusively.<sup>7,27-30</sup>

Abdominal imaging studies in neutropenic patients are sometimes challenging and not easy to perform. CT scans cannot always be carried out due to the acute critical illness of these patients and confounding issues like renal failure. Ultrasonography is a very valuable, safe and non-invasive option; however, it is not as sensitive or accurate as CT in demonstrating the intra-abdominal pathology. In a study of 1720 patients who received intensive chemotherapy for high risk haematological malignancies, intestinal wall thickening was detected in 50% patients with neutropenic enterocolitis; however, this study was limited because it was retrospective.<sup>22,24</sup> There was lack of comparison with CT and, finally, diagnosis of neutropenic enterocolitis was made only on clinical grounds.<sup>23</sup> In another study, a lower diagnostic yield was demonstrated with ultrasonography, indicating the use of CT as the preferred imaging modality in neutropenic patients

with diarrhoea.<sup>24,28</sup> Gorschlüter et al.<sup>11</sup> have suggested that the presence of fever, abdominal pain and bowel wall thickening of >4 mm in a neutropenic patient should be accepted as diagnostic criteria for neutropenic enterocolitis.<sup>23</sup> In one series, 27.3% of the patients with documented neutropenic enterocolitis did not have abdominal pain at all.<sup>28</sup> Differential diagnosis of *C. difficile* associated diarrhoea and neutropenic enterocolitis may sometimes be challenging, or they can co-exist.<sup>11</sup> In a retrospective series of 76 neutropenic patients with radiological abnormalities on CT, Kirkpatrick and Greenberg<sup>26</sup> reported the greatest mean wall thickness in patients with *C. difficile* colitis (12 mm in *C. difficile* colitis versus 7 mm in neutropenic enterocolitis).

### **What are the other possible Diagnoses to differentiate from NE?**

Although the classical triad of neutropenic enterocolitis — fever, abdominal pain and diarrhoea - has been used as the diagnostic criteria for many years, there is considerable overlap between neutropenic enterocolitis and other causes of diarrhoea.<sup>1,2,4,8,29</sup> Mucositis-related diarrhoea, *C. difficile*-associated colitis, ischaemic colitis, bacterial and viral colitides, parasitosis and surgical pathologies should be differentiated.<sup>3,4</sup>

The other differential diagnosis to be considered in suspected NE include diverticulitis, appendicitis, Inflammatory bowel disease, acute megacolon, Ogilvie syndrome, graft versus host disease, cholecystitis, pseudomembranous colitis, small bowel obstruction, intersuception, ischaemic colitis, and pelvic abscess.<sup>1-5</sup> The clinical presentation in all these cases may range from features of septicaemia to intestinal perforation and shock.<sup>8-10,29,30</sup> The main differential diagnosis is *C. difficile* induced pseudo membranous colitis which is less severe and has positive bacterial tests.<sup>28-30</sup> Stool and blood cultures (*Clostridium difficile*) should always be carried out in each and every case.<sup>11,28,29</sup>

### **What are the Treatment Options in a case of NE?**

There are no randomized clinical trials or prospective studies addressing the management of NE. Most clinicians follow the guidelines for febrile neutropenia as general.<sup>1,2,8-10</sup> The more conservative management approach consists of aggressive fluid resuscitation, restoring the electrolyte balance, bowel rest, alimentary decompression, parenteral nutrition, supplementing blood products (platelets, Fresh frozen plasma, and cryoprecipitate), and broad spectrum antibiotics to cover gram positive cocci, gram negative bacilli, and anaerobes.<sup>2,4,5,14,20</sup> A frequent imaging by the CT scan to assess the progress is suggested.<sup>14,15,22</sup> Many management guidelines also advocate the potential advantage of using G-CSF in neutropenic patients with septicaemia, abscess or shock.<sup>30,31</sup>

The Empirical anti fungal therapy is also recommended as there is substantial difference in mortality for those receiving it, especially if neutropenic fever is of more than 5 days duration.<sup>8,10,31</sup>

Laparotomy is often indicated in cases of peritonitis, persistent gastrointestinal bleeding despite improvement of neutropenia, thrombocytopenia and coagulopathy and if the patient deteriorates despite aggressive conservative medical management.<sup>3-5,8,32-35</sup> The first successful surgical intervention in NE was done in 1979 with right hemicolectomy and ileocolic anastomosis.<sup>3,34</sup> An early diagnosis and prompt surgical management influence the outcome and give a better prognosis.<sup>5,32-35</sup> The selection criteria for an early surgical intervention include a persistent GI bleed despite improved blood counts and coagulopathy, radiologic evidence of perforation, deterioration on conservative management, and progressive symptoms of abdominal involvement despite improving neutropenia.<sup>2,33,34</sup> The common procedure performed is right hemicolectomy, loop ileostomy, and resection of gut having transmural necrosis or perforation.<sup>2,5,35</sup>

The use of anticholinergics, antidiarrheals, and narcotic analgesics should be avoided as they may mask or confuse the clinical picture. The antibiotics of utility are metronidazole, 3rd or 4th generation cephalosporins, meropenem, imipinem, pencillins, and aminoglycosides in varying combination.

The treatment is not optimized, with options varying from conservative medical management to early surgical intervention. Early recognition of NE is paramount to a potentially good outcome. The available management options warrant a tailored individualized treatment strategy; considering the co-morbidities, cytopenias, and coagulopathy.<sup>5,8,32-35</sup> A conservative approach in the absence of surgical indications is a logical approach. A high mortality however is experienced with both the approaches.<sup>2,8</sup>

### **Treatment outcomes and Prognosis of NE**

Many cases of NE occur and progress to a fatal outcome without being ever suspected. The early recognition and prompt management is the only chance of survival in these cases.

The most important risk factor of morbidity and mortality in NE seems to be neutropenia. Indeed, the combination of the two is deadly in 40%-50% of cases.<sup>14,31-35</sup>

Mortality rates of 5-100% have been reported with conservative management, and an average mortality rate of about 40-50%.<sup>34,35</sup>

NE often has an atypical presentation with the initial complaint being slight abdominal pain which rapidly deteriorates into peritonitis and associated shock.<sup>1,4,5,29</sup> It is important for physicians to be attentive to seemingly harmless symptoms even in younger patients under aggressive

chemotherapy.<sup>7,8,10,13</sup> They may be the only heralding signs of deadly yet preventable complications especially when associated with neutropenia.<sup>31,32</sup>

The authors in their clinical practice have encountered three cases of NE. They were colon cancer, breast cancer and Lung cancer (NSCLCA). They received capecitabine+oxaliplatin (XELOX), adriamycin plus paclitaxel (AT), and Carboplatin+Paclitaxel based regimens respectively. NE developed after 2nd, 3rd and 5th cycle on average 12th day post chemotherapy (10-15 days). All of them presented with neutropenia, shock and septicaemia with predominant abdominal and GI related symptoms. The basis of diagnosis was clinical, radiological (ultra sound/CT scan), per operative findings, and post mortem findings in one case. Only one patient had surgical intervention, while other two were managed conservatively. Two of the three patients did not survive, despite all the treatment offered.

### Conclusion

Given the widespread, aggressive use of systemic chemotherapy in the neoadjuvant setting, patients at risk for this potentially lethal complication of neutropenic enterocolitis are increasingly common. Necrotizing enterocolitis in adults is a rare fatal disease and, in the past, has been associated with nearly uniform mortality in almost every case. An early surgical intervention in adult patients with intestinal necrosis is essential to avoid fatal outcome from this condition.

A high index of clinical suspicion, an early diagnosis and prompt management is key to a favourable positive outcome in NE. Awareness and suspicion in the mind of treating physician, in high risk patient population, can only lead to early diagnosis and effective management. Despite all the precautions, NE will continue to be encountered in clinical practice; emphasizing the need for identification of prognostic factors, formulating guidelines of management, and standardizing the management. At the current stage of clinical knowledge, an individualized risk assessment based treatment strategy is advocated.

Due to paucity of cases, emergent medical situations, difficulty in recognition it is difficult to have a prospective analysis or study. It is thus required to have subgroup Meta analysis to formulate evidence based guidelines.

### References

1. Buchheidt D, Bohme A, Cornely OA, et al. Diagnosis and treatment of documented infections in neutropenic patients: Recommendations of the Infectious Disease Working party (AGIHO) of the German society of Hematology and Oncology (DGHO). *Ann Hematol* 2003; 82 (Supple 2): S127-32.
2. Celeste Ann T. Bremer and Brian P. Monahan. Necrotizing Enterocolitis in Neutropenia and Chemotherapy: A Clinical Update and Old Lessons Relearned. *Current Gastroenterol Reports* 2006; 8: 333-41.
3. Badgwell BD, Cormier JN, Wray CJ, et al. Challenges in surgical management of abdominal pain in the neutropenic cancer patient. *Ann Surg* 2008; 248: 104-9.
4. Wade DS, Nava HR, Douglass HOJ. Neutropenic enterocolitis. *Clinical diagnosis*

- and treatment. *Cancer* 1992; 69: 17-23.
5. Ullery BW, Pieracci FM, Rodney JR, et al. Neutropenic Enterocolitis. *Surg Infect (Larchmy)* 2009; 10: 307-14.
6. Mullholland MW, Delaney JP. Neutropenic colitis and aplastic anaemia, a new association. *Ann Surg* 1983; 197: 84-90.
7. Salazar R, Sola C, Maroto P et al. Infectious complications in 126 patients treated with high-dose chemotherapy and autologous peripheral blood stem cell transplantation. *Bone Marrow Transplant* 1999; 23: 27-33.
8. Gorschluter M, Mey U, Strehl J, et al. neutropenic enterocolitis in adults: systematic analysis of evidence quality. *Europ J Hematol* 2005; 75: 1-13.
9. Fike FB, Mortellaro V, Juang D, et al. Treatment of appendicitis in Neutropenic Children. *J Surg Res* 2011; 170 : 14-6.
10. Keith Sultan, and Rajeev Vasudeva. Neutropenic Enterocolitis. *Drugs Diseases and Procedures* 2009; 3: 218-21.
11. Gorschluter M, Glasmacher A, Hahn C et al. Clostridium difficile infection in patients with neutropenia. *Clin Infect Dis* 2001; 33: 786-91.
12. Dumitra S, Sideris L, Leclerc Y, et al. Neutropenic enterocolitis and docetaxel neoadjuvant chemotherapy. *Ann Oncology* 2009; 20: 795-6.
13. Avigan D, Richardson P, Elias A, et al. Neutropenic enterocolitis as a complication of high dose chemotherapy with stem cell rescue in patients with solid tumors: a case series with a review of the literature. *Cancer* 1998; 83: 409-14.
14. Kouroussis C, Samonis G, Androulakis N, et al. Successful conservative treatment of neutropenic enterocolitis complicating taxane-based chemotherapy: A report of five cases. *Am J Clin Oncol* 2000; 23: 309-13.
15. Wenzel C, Urbauer E, Schwarz C, et al. Severe enteropathy associated with raltitrexed and oxaliplatin chemotherapy: report of two patients experiencing this rare, potentially lethal gastrointestinal adverse event. *Anticancer Drugs* 2006; 17: 865-8.
16. Tiseo M, Gelsomino F, Bartolotti M, et al. Typhlitis during second-line chemotherapy with pemetrexed in non-small cell lung cancer (NSCLC): A case report. *Lung Cancer* 2009; 65: 251-3.
17. Marie I, Robaday S, Kerleau JM, Jardin F, Levesque H. Typhlitis as a complication of alemtuzumab therapy. *Haematol* 2007; 92: e62-3.
18. Kasturi KS, Mummadi RR, Sood GK. Neutropenic enterocolitis: An unusual complication of HCV combination therapy with PEG-IFN and ribavirin. *Eur J Intern Med* 2008; 19: 372-3.
19. Wenzel C, Urbauer E, Schwarz C et al. Severe enteropathy associated with raltitrexed and oxaliplatin chemotherapy: report of two patients experiencing this rare, potentially lethal gastrointestinal adverse event. *Anticancer Drugs* 2006; 17: 865-8.
20. Cloutier RL. Neutropenic enterocolitis. *Emerg Med Clin North Am* 2009; 27: 415-22.
21. Hogan WJ, Letendre L, Litzow MR et al. Neutropenic colitis after treatment of acute myelogenous leukemia with idarubicin and cytosine arabinoside. *Mayo Clin Proc* 2002; 77: 760-2.
22. Spencer SP, Power N, and Reznick RH. Multidetector computed tomography of the acute abdomen in the immunocompromised host: a pictorial review. *Curr Probl Diagnostic Radiol* 2009; 38: 145-55.
23. Dietrich CF, Hermann S, Klein S, et al. Sonographic signs of neutropenic enterocolitis. *World J Gastroenterol* 2006; 12: 1397-402.
24. Rizzatti M, Brandalise SR, de Azevedo AC, et al. Neutropenic enterocolitis in children and young adults with cancer: prognostic value of clinical and image findings. *Pediatrics. Hematol Oncol* 2010; 27: 462-70.
25. Cardona Zorrilla AF, Reveiz Herault L, Casasbuenas A, Aponte DM, Ramos PL. Systematic review of case reports concerning adults suffering from neutropenic enterocolitis. *Clin Transl Oncol* 2006; 8: 31-8.
26. Kirkpatrick ID, Greenberg HM. Gastrointestinal complications in the neutropenic patient: characterization and differentiation with abdominal CT. *Radiol* 2003; 226: 668-74.
27. Gorschluter M, Marklein G, Hofling K et al. Abdominal infections in patients with acute leukemia: a prospective study applying ultrasonography and microbiology. *Br J Haematol* 2002; 117: 351-8.
28. Madani TA. Clinical infections and bloodstream isolates associated with fever in patients undergoing chemotherapy for acute myeloid leukemia. *Infection* 2000; 28: 367-73.
29. Aksoy DY, Tanriover MD, Uzun O, Zarakolu P, Ercis S, Erguven S, Oto A, Kerimoglu U, Hayran M, Abbasoglu O. Diarrhea in neutropenic patients: a prospective cohort study with emphasis on neutropenic enterocolitis. *Ann Oncol* 2007; 18: 183-9.
30. Mullassery D, Bader A, Battersby AJ, et al. Diagnosis, incidence, and outcomes of

- suspected typhlitis in oncology patients - experience in a tertiary pediatric surgical center in the United Kingdom. *J Pediatr Surg* 2009; 44: 381-5.
31. Kuderer NM, Dale DC, Crawford J, et al. Impact of primary prophylaxis with granulocyte colony-stimulating factor on febrile neutropenia and mortality in adult cancer patients receiving chemotherapy: A systematic review. *J Clin Oncol* 2007; 25: 3158-67.
  32. Cunningham SC, Fakhry K, Bass BI, Napolitano LM. Neutropenic enterocolitis in adults: case series and review of literature. *Digest Dis Sci* 2005; 50: 215-20.
  33. Cloutier RL. Neutropenic Enterocolitis. *Haematol. Oncol. Clin N Am* 2010; 24: 577-84.
  34. Furonaka M, Miyazaki M, Nakajima M, et al. Neutropenic enterocolitis in lung cancer: a report of two cases and a review of the literature. *Intern Med* 2005; 44: 470-6.
  35. Davila ML. Neutropenic enterocolitis: current issues in diagnosis and management. *Curr Infect Dis Rep* 2007; 9: 116-20.
-