

Arthritis and Rosai-Dorfman Disease of the Skin: A Diagnostic Dilemma

Pages with reference to book, From 280 To 282

Irshad Nabi Soomro (Department of Pathology, The Aga Khan University Hospital, Karachi.)
Kamran Hameed (Department of Medicine, The Aga Khan University Hospital, Karachi.)

Introduction

Sinus histiocytosis with massive lymphadenopathy commonly presents with painless, bilateral, massive lymph node enlargement in the neck. There is association with fever, leukocytosis, raised erythrocytation rate and polyclonal hypergammaglobulinemia. Upto 40% cases can have extranodal involvement, common sites being skin, orbit, central nervous system, head and neck region and upper respiratory tract. Disease has not so far been described in the bone marrow and spleen. Disease is known to occur in all races with predisposition for the condition in blacks. There are case reports describing, lesion effecting lymph nodes in the region of Sub-Continent. However, extranodal disease is described in only one report¹; we present another case predominantly involving skin.

Case Report

This 55 year old man presented to rheumatology clinic in January 1996 with complaints of pain in small and large joints. The pain dated back to 1983 and had recently increased in severity. Joint pain predominantly effected both knee joints, ankles and toes. Interphalangeal joints of both hands were also involved. Joint pain was piercing and lasted 1-1½ hours. This episodic pain was accompanied by swelling which lasted 3-4 days. Pain used to subside after analgesic medication. Patient was in stone crushing business which he has given up.

Patient had no family history of arthritis. His serum uric acid was 6.4 mg/dl at the time of presentation. Since October 1996 he noticed several red subcutaneous nodules on back, chest and calves of both the legs (Figures 1 and 2).

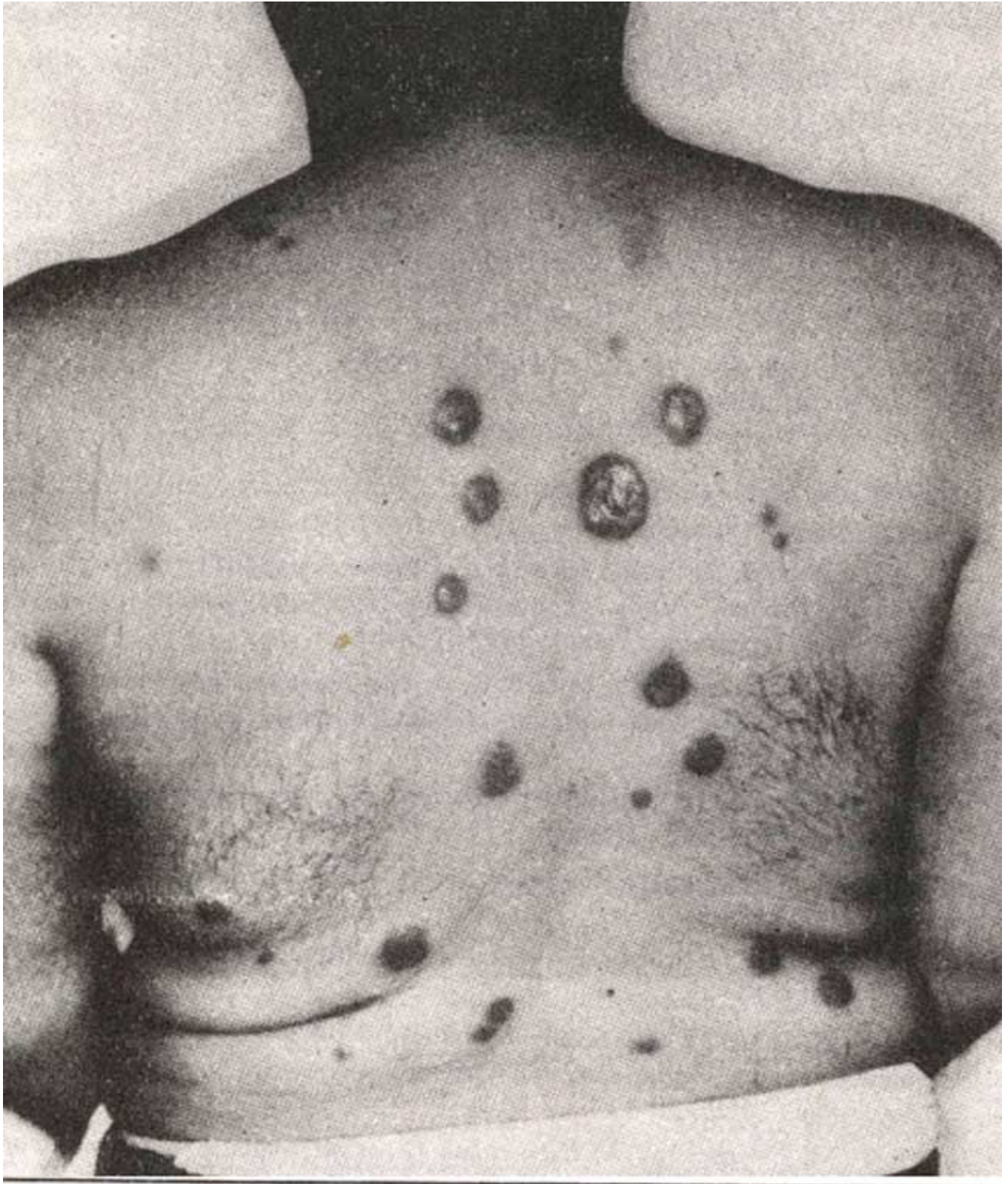


Figure 1 Pink indurated round to oval plaques of variable size predominantly on the back.

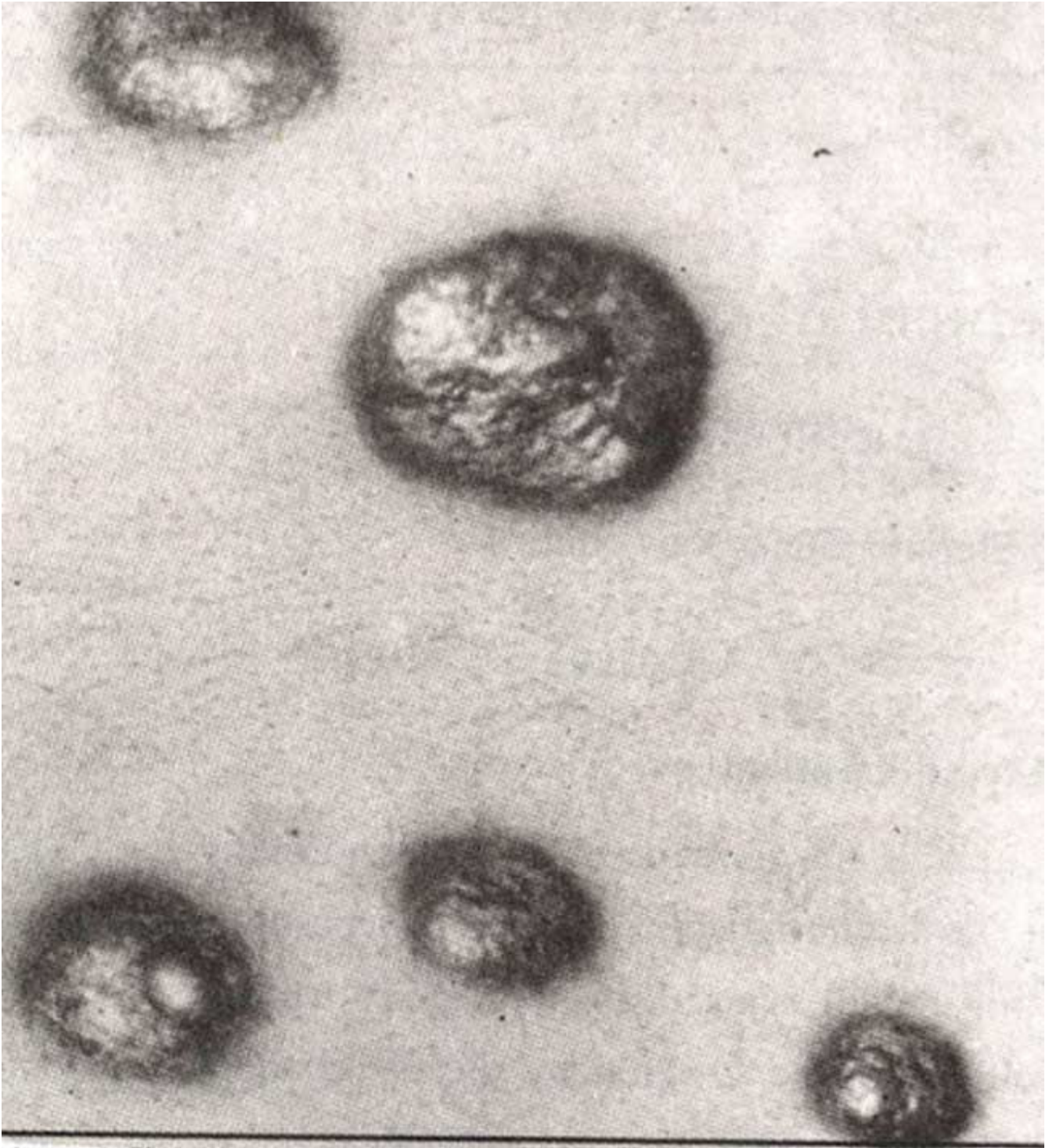


Figure 2 Closer inspection reveals papular excrescences on the surface of these lesions

Patient on examination was well nourished and had several hyperpigmented and indurated plaques and nodules of variable sizes predominately on the back. Similar lesions were seen on the chest and lower legs. A swelling measuring 3.00 cm was present in the parotid region and was clinically thought to be enlargement of the parotid gland. Other significant finding included Angiotensin converting enzyme levels of 139 and serum ANA speckled positivity.

The initial punch biopsy of one of these lesions revealed unremarkable epidermis and infiltrate of foamy macrophages in the dermis. There were few multinucleated giant cells associated with these

macrophages. Special stains for leprosy, TB and fungus were negative. A suggestion of granulomatous inflammation was made. Coupled with clinical findings and ACE levels a diagnosis of sarcoidosis was made and patient was prescribed 25 mg dexamethasone once daily. He was again seen on 3/1/1997 and complained of hair loss over the legs, shortness of breath and photophobia. There was no reduction in the size of skin lesions or joint symptoms. In view of no response to steroids a second skin biopsy was performed. The histology of the skin lesion revealed a diffuse infiltrate of foamy histiocytes in the dermis and subcutaneous fat. Emperipolesis of lymphocytes and plasma cells by macrophages was also seen. Occasional Touton type giant cells were noted. At the periphery of histiocytes there were collections of lymphocytes. Staining with anti S-100 protein antibody showed cytoplasmic positivity of the histiocytes. There was no pseudoepitheliomatous hyperplasia of the epidermis and eosinophils were not seen as seen in one case by Chu P et al 1992². A dermatopathology consult was obtained and a specific diagnosis of sinus histiocytosis with massive lymphadenopathy, Rosai-Dorfman was made. Lymph node was not biopsied.

Discussion

Rosai-Dorfman is a well-known entity especially among histopathologists. Condition is almost always included in the differential diagnosis whenever a lymph node with normal architecture and dilated sinuses with macrophages is examined. Lymphocytophagocytosis (emperipolesis) is specific feature of this condition and clinches the diagnosis. In pathology practice, however, lymph nodes with dilated sinuses are commonly received and indicate a physiologic or pathologic response.

Sinus histiocytosis with massive lymphadenopathy although primarily thought to be affecting lymph nodes can have extranodal manifestations in upto 40% cases. Skin involvement is the commonest extranodal presentation³. Because of rarity of disease, first biopsy diagnosis can be misleading⁴. The differential diagnosis includes xanthoma, Juvenile Xanthogranuloma, benign histiocytic lesions such as eruptive histiocytoma, Langerhan's cell histiocytosis, metastatic malignant melanoma and in endemic areas like ours lepromatous leprosy.

Our case had a predominant skin involvement manifesting with lesions as described by Perez Ferriols⁵. Only single lymph node was massively enlarged in the parotid region. Patient also had arthritis since 13 years. In 1966, Azoury and Reed⁶ described histiocytosis characterized by recurrent infections, massive lymphadenopathy, histiocytic infiltration of the testes and rheumatoid arthritis for 10 years. Our case seemed to resemble this in some ways.

This case report describes systemic Rosai-Dorfman disease with predominant skin manifestations. As tissue diagnosis of joint disease was not made one can only speculate about arthritis. Immune associations are commonly observed with RDD and common lesions include joint disease and autoimmune hemolytic anemia⁷. Our patient also had ANA ++ positivity supporting an immune basis, although joint disease preceded 13 years of skin lesions. Skeletal defects resembling histiocytosis, neurofibromatosis, sarcoidosis, osteomyelitis or metastasizing neuroblastoma are well described in Rosai-Dorfman disease⁸. These changes were not seen in this case.

Skin manifestation with arthritis and biopsy findings led us into diagnosis of sarcoidosis. Other conditions that were included in the differential diagnosis included reticulohistiocytoma, xanthoma etc. Diagnosis of cutaneous Rosai-Dorfman disease can be specifically made provided this condition is included in the differential diagnosis both histologically and clinically. Condition can present as panniculitis⁹, macular erythema, xanthomatous eruptions, plaque like infiltrates of the lower legs, penile lesions resembling Peyronie's cutaneous fistulae and plaques⁷.

Conclusion

Although several cases of Rosai-Dorfman involving lymph nodes are, described, this is second case of predominately extranodal Rosai-Dorfman disease from Southeast Asia. First case presented with skin and multiple osteolytic lesions in India'. Recognition of this entity will definitely bring out more reports.

A close liaison between clinician and histopathologist is desirable to reach a definitive diagnosis. Histologically emperipolesis may be missed and one must attempt to find this feature by cutting thin paraffin sections and use of high power microscopy especially oil immersion lens. Immunocytochemistry can supplement the diagnosis.

Acknowledgement

Authors wish like to thank Dr Phillip H Mckee, Department of Dermatopathology, Division of Pathology, Brigham and Women's Hospital, 75 Francis Street, Boston MA 02115, USA for reviewing this case.

References

1. Naresh KN, Mukerjee G, Rao CR et al. Extranodal sinus histiocytosis with massive lymphadenopathy - case report. *Indian J. Cancer*, 1992;29:226-29.
2. Chu P, Le Boit PE. Histologic features of cutaneous sinus histiocytosis (Rosai-Dorfman Disease). Study of cases both with and without systemic involvement. *J. Cutaneous Pathol.*, 1992;19:201-6.
3. Thawerani, H, Sanchez RL, Rosai J, et al. The cutaneous manifestations of sinus histiocytosis with massive lymphadenopathy. *Arch. Dermatol.*, 1978;14:191.
4. Carrington PR, Reed RJ, Sanusi DI, et al. Extranodal Rosai-Dorfman Disease (RDD) of the skin. *Int. J. Dermatol.*, 1998;37:267-77.
5. Perez Ferriols AA. Sinus histiocytosis limited to the skin (abstract). *J. Cutan. Pathol.*, 1992;19:542.
6. Azoury Fi, Reed J. Histiocytosis-report of an unusual case. *N. Engl. J. Med.*, 1966;274:928-30.
7. Foucar E, Rosai J, Dorfman RF, Sinus Histiocytosis with massive lymphadenopathy (Rosai-Dorfman Disease): review of the entity *Semin. Diag. Pathol.*, 1990;7:19-73.
8. Lehnert M, Eisenschenk A, Dienemann D, et al. Sinus histiocytosis with massive lymphadenopathy-skeletal involvement. *Arch. Orthop. Trauma Surg.*, 1993;113:53-56.
9. Puppin D Jr, Chavaz P, Harms M. Histiocytic lymphophagocytic Panniculitis (Rosai-Dorfman Disease) a case report. *Dermatology*, 1992;184:317-20.