

# Acute Urinary Retention: A Primary Manifestation of Chronic Lymphocytic Leukemia and Organ Confined Prostate Cancer

Pages with reference to book, From 124 To 125

M. Hammad Ather, Amanullah Memon ( Section of Urology, Department of Surgery, The Aga Khan University, Stadium Road, Karachi. )

## Introduction

Luekemic infiltration of the prostate is unusual. Acute urinary retention as an initial presentation of chronic lymphocytic leukemia is found only in sporadic cases. Organ confmed adenocarcinoma of prostate associated with chronic lymphocytic leukemia and presenting as acute urinary retention is to our knowledge not reported in literature. This report documents a case of acute urinary retention in a 74-year-old man with chronic lymphocytic leukemia and adenocarcinoma of the prostate.

## Case Report

A 74-year-old male presented to the Emergency Room with a 20-hour history of acute urinary retention. He has been troubled with mild to moderate irritative lower urinary tract symptoms, which were not bothersome. When catheterized in the emergency room 1500 cc of urine drained in the first 15 minutes. The past history revealed hypertension (well controlled), coronary artery by-pass grafting in 1984 for ischemic heart disease, although at present, his cardiovascular status was unremarkable. Digital rectal examination showed a moderately enlarged benign feeling prostate with firm consistency but no nodularity. Since past history of Lower Urinary Tract Symptoms (LUTS) was mild, he was given a trial without catheter after commencement of a-blocker (Terazosin). This, however, failed and he was re-catheterized. His preoperative haemoglobin, hematocrit and total leukocyte counts were normal. An uneventful transurethral resection of prostate was done and he was discharged on the second postoperative day after successfully removing the catheter. Later his histopathology revealed leukciiiiic infiltration with 10% chips showing a well-differentiated adenocarcinoma of the prostate (Figures 1 and 2).

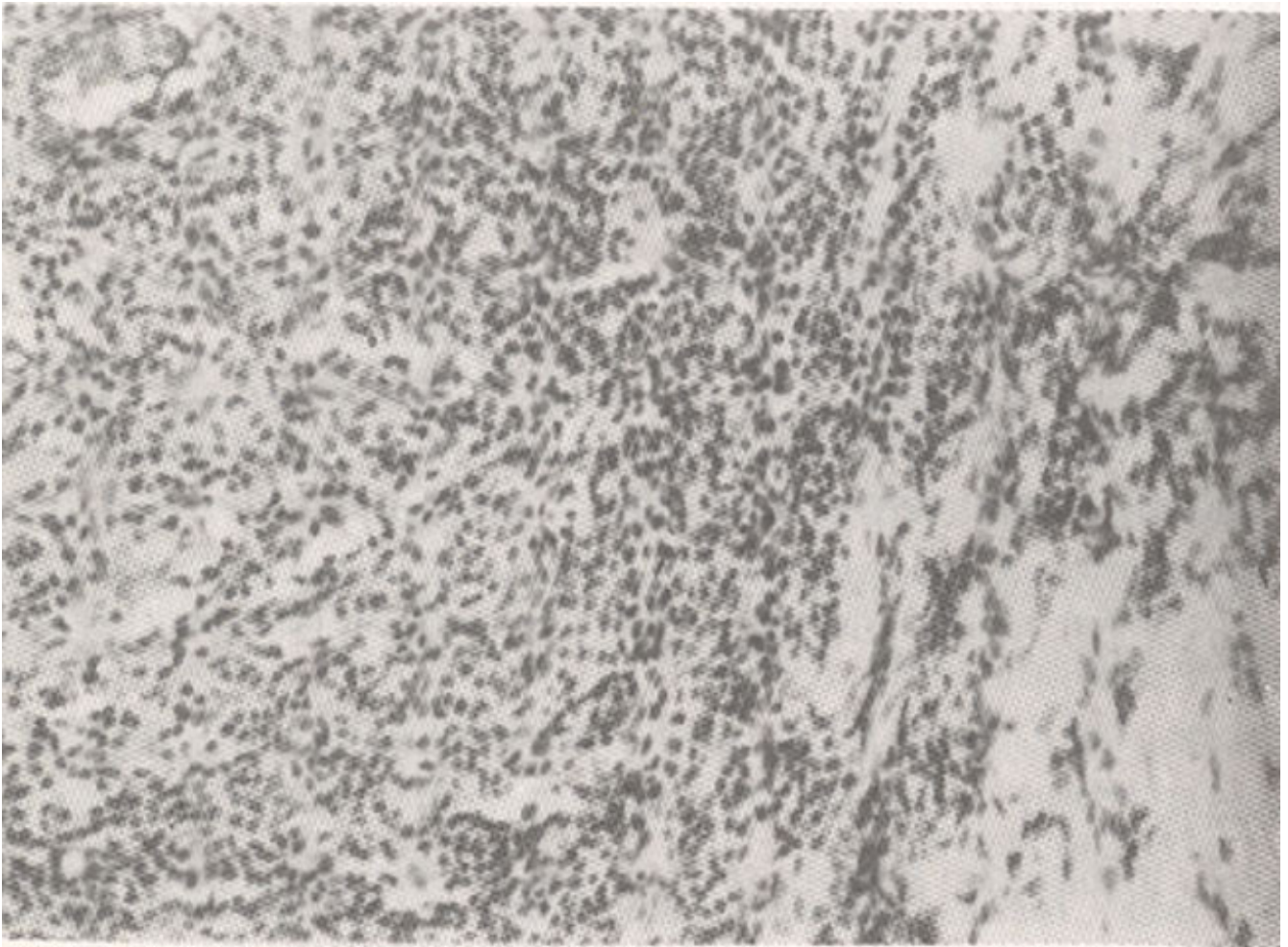


Figure 1. Photomicrograph showing dense leukemic infiltration in a transurethral resection (TUR) prostate chip.

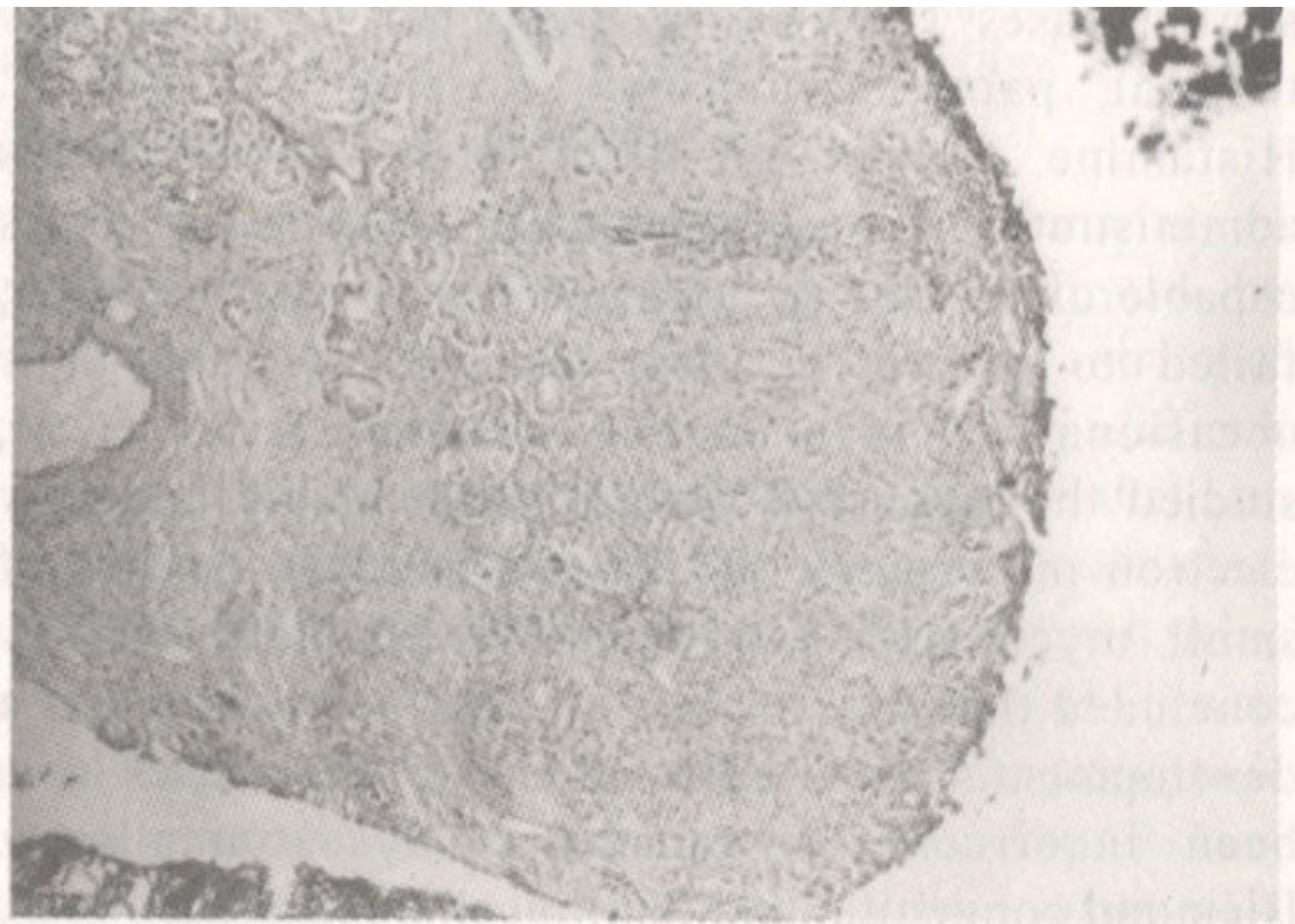


Figure 2. Photomicrograph of a cross section of TUR prostate chip with a focus of prostate cancer.

Gleason sum was 2+1=3. Serum PSA was 2.1 ng/ml (0-Sng/ml). The bone scan was negative for any metastatic disease. The leukernic infiltrate of the prostate was LCA +ve and cytokeratin -ye. The blood film was highly suggestive of chronic lymphocytic leukemia, his post-operative haemoglobin concentration was 13.6 gm%(11 - 15.5 gm/dl), white blood cell count was  $6 \times 10^9$  (4-10) with 47% lymphocytes and platelet count was also normal. Consultations with the haematologist and oncologists derived a consensus that no further treatment was indicated at that stage. Regular follow-ups were recommended and further intervention would only be indicated if haemoglobin and platelet counts showed a decline. Watchful waiting was adopted with regular serum PSA and digital rectal examinations to monitor the prostate cancer status.

## Discussion

Leukemic infiltration of the prostate is unusual. Most commonly encountered pathology is chronic lymphocytic leukemia. In 1973, Butler and O'Flym<sup>1</sup> detected 6 cases of CLL among 4863 consecutive prostatectomies. In a necropsy study of 5962 male subjects with various types of cancer, Zein et al<sup>2</sup> found 18 cases of CLL infiltrating the prostate gland among 88 cases of CLL (20.4%). Seventy seven patients died of leukemia showed leukemic involmenet of the prostate among 776 autopsied leukemia patients (10%).

To our knowledge, prostate cancer associated with chronic lymphocytic leukemia has only been reported once<sup>3</sup> in a patient with Klinefelter syndrome with XXY karyotype. Terris et al<sup>4</sup> assessed the clinical impact of haematolymphoid malignancies in a retrospective review, discovered during 1092

radical prostatectomies. The overall incidence in their experience was 1.2%. Of these, there were 9 cases of CLL for which no further treatment was needed. In their opinion majority of hematolymphoid malignancies discovered at radical prostatectomy do not require further treatment.

Well differentiated adenocarcinoma of prostate with a low Gleason sum in a 74 year old male can be managed by expectant means. Clinically, isolated prostatic involvement by leukemia is generally managed by observation alone<sup>5</sup>. In our patient due to low potential for progression and relatively benign natural history of both conditions, considered separately, we opted for watchful waiting which concurred with the wishes of the patient too.

## References

1. Butler MR, O'Flynn JD. Prostatic disease in leukemic patients with particular reference to leukemic infiltration of the prostate - a retrospective clinical study. *Br. J. Urol.* 1973;45:179-83.
2. Zein TA, Huben R, Lane W, et al. Secondary tumors of the prostate. *J. Urol.*, 1985;133:615-16.
3. Pienkos EJ, Meisner LF. Adenocarcinoma of the prostate in a 41 year old man with XXY karyotype and chronic lymphocytic leukemia: report of a case. *J. Urol.*, 1991;145:148-50.
4. Terris MK, Hausdorff J, Freiha FS. Hematolymphoid malignancies diagnosed at the time of radical prostatectomy. *J. Urol.*, 1997;158:1457-9.
5. Mellempgaard A, Geisler CH, Storm HH. Risk of kidney cancer and other second solid malignancies in patients with chronic lymphocytic leukemia. *Eur. J. Haematol.*, 1994;53(4):218-22.